

A detailed microscopic image of tissue, likely a histological section, showing various cellular structures and fibers. The image is the background for the entire page.

Annotation

- histological dictionary

Contents

Subcellular localizations

- 5 – plasma membrane, cilia, microvilli, extra cellular
- 6 – Golgi apparatus, lysosomes, peroxisomes, endoplasmic reticulum
- 7 – mitochondria, nucleus, nuclear membrane, nucleoli

Different celltypes and intracellular structures

Adrenal gland

- 8 – adrenal medulla

Airway epithelium

- 9 – pneumocytes
- 10 – goblet cells in nasopharynx and bronchus

Blood, bone marrow, muscular tissue

- 11 – artery wall
- 12 – endothelial cells
- 13 – erythropoiesis in bone marrow
- 14 – myelopoiesis in bone marrow
- 15 – megakaryocytes in bone marrow
- 16 – smooth muscle cells
- 17 – intracytoplasmic structures and intercalated discs in heart muscle

Breast

- 18 – glandular cells with a special type of activity
- 19 – myoepithelial layer

Gastro- /intestinal tract

- 20 – chief cells in stomach
- 22 – endocrine cells in stomach
- 23 – endocrine cells in duodenum
- 24 – glands of Brunner in duodenum
- 25 – goblet cells in duodenum
- 26 – cells of mesenchymal origin in small intestine
- 27 – mast cells in duodenum
- 28 – plasma cells in colon
- 29 – ganglia in duodenum

Kidney

- 30 – Bowman's capsule, tubules
- 31 – podocytes

Liver

- 32 – glycogen-granules
- 33 – bile ducts
- 34 – bile canaliculi and Kupffer cells

Lymphoid tissue

- 35 – different parts of a lymph node
- 36 – different parts of the spleen
- 37 – cells of hematopoietic origin in lymph node
- 38 – B-lymphocytes in tonsil
- 39 – T-lymphocytes in appendix and lymph node
- 40 – granulocytes in spleen
- 41 – histiocytes in spleen
- 42 – macrophages in tonsil
- 43 – plasma cells in tonsil

Nervous tissue

- 44 – astrocytes in cerebellum
- 45 – astrocytes and gyrus dentatus in hippocampus
- 46 – plexus choroideus in hippocampus
- 47 – pyramidal neuronal cells in cerebral cortex
- 48 – dotlike pattern in cerebellum and hippocampus
- 49 – subtype of nerve fiber in cerebellum
- 50 – peripheral nerve

Pancreas

- 51 – endocrine and exocrine pancreas
- 52 – ducts in pancreas

Placenta

- 53 – decidual cells, trophoblasts
- 54 – endometrial glandular cells
- 55 – accumulation of trophoblasts
- 56 – rodlike structures in nuclei of trophoblasts
- 57 – parts of an embryo

Reproductive system

- 58 – ciliated cells in endometrium
- 59 – ciliated cells and secretory cells in fallopian tube
- 60 – follicles in ovary
- 61 – spermatogonia and sertoli cells in testis
- 62 – spermatocytes, spermatids and spermatozoa in testis
- 63 – Leydig cells in testis

Salivary gland

- 64 – ducts in a salivary gland
- 65 – mucous and serous acini

Skin

- 66 – cell layers in squamous epithelium
- 67 – dendritic antigen-presenting cells
- 68 – melanocytes

Other

- 69 – proliferating cells in intestine and lymphoid tissue

Tumor cells or not?

Breast cancer

- 70 – atypic lobular hyperplasia or lobular cancer in situ
- 71 – cancer in situ
- 72 – benign glandular cells

Cervical cancer

- 73 – tumor stroma, fibroblasts

Endometrial cancer

- 74 – subpopulation of tumor cells

Malignant glioma

- 75 – endothelial cell proliferations
- 76 – oligodendrocyte and phagocytic macrophage

Malignant lymphoma

- 77 – Hodgkin cells
- 78 – reactive lymphocytes

Pancreatic cancer

- 79 – pancreatitis

Prostate cancer

- 80 – loss of basal layer
- 81 – Gleason grade IV

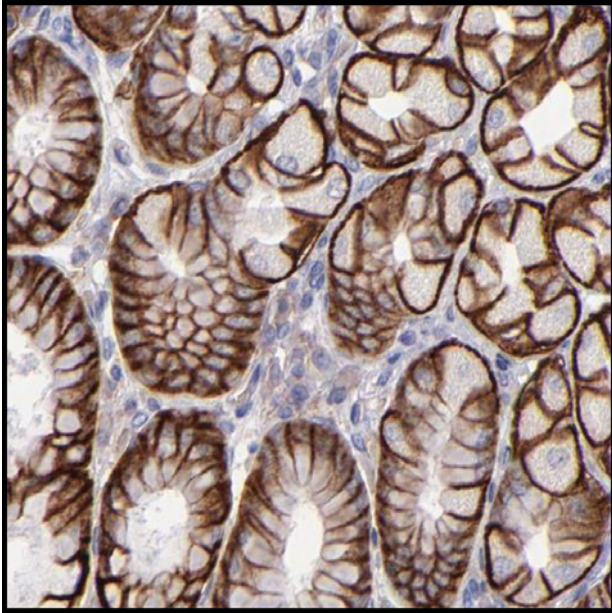
Skin cancer

- 82 – sebaceous glands

Urothelial cancer

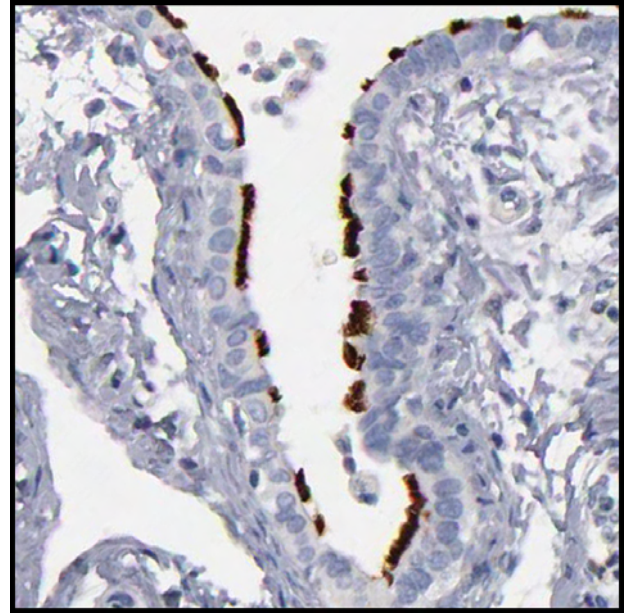
- 83 – what area is cancer?
- 84 – smooth muscle cells

Plasma membrane



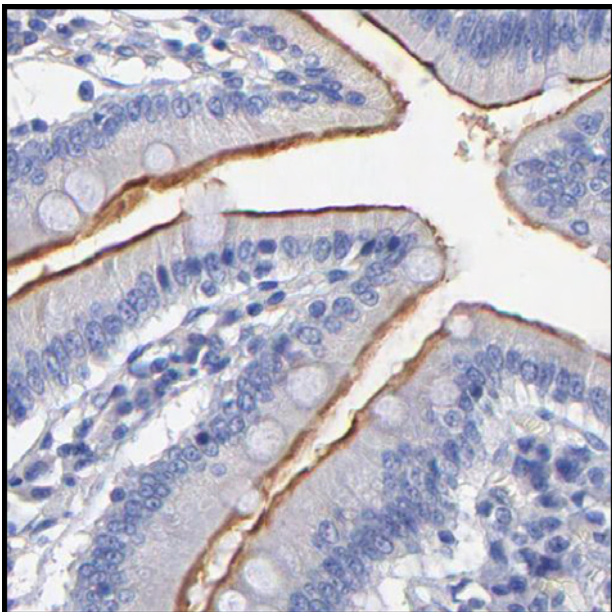
Antibody: CAB002427
Tissue: Stomach

Cilia



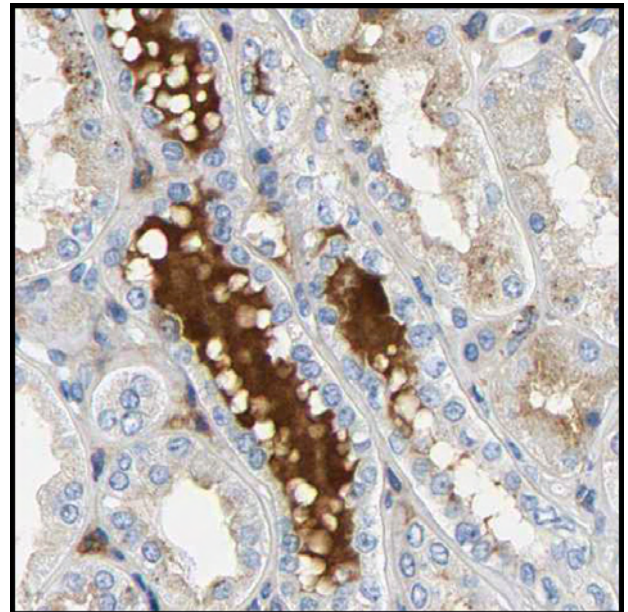
Antibody: HPA001874
Tissue: Fallopian tube

Microvilli



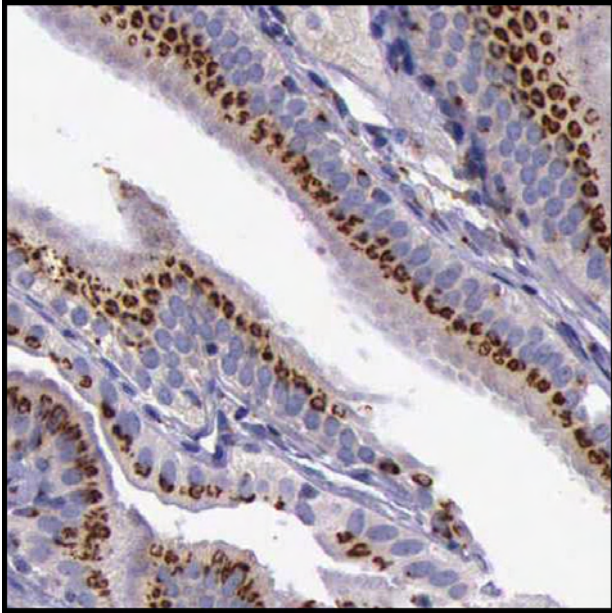
Antibody: HPA003228
Tissue: Small intestine

Extra cellular



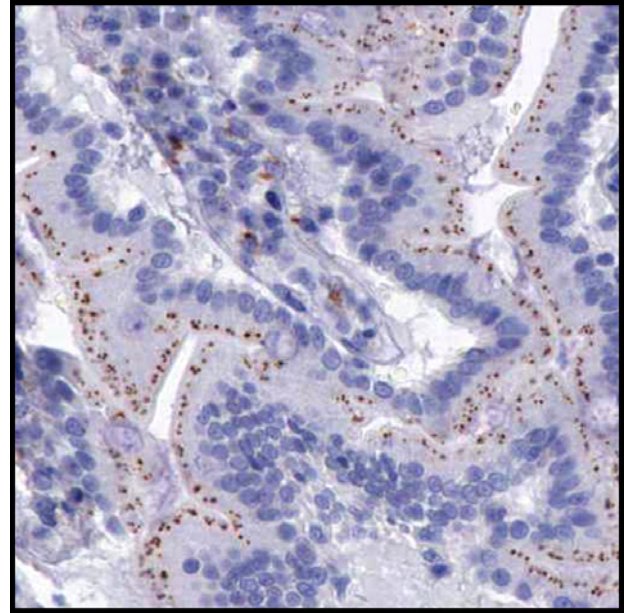
Antibody: CAB005036
Tissue: Kidney

Golgi apparatus



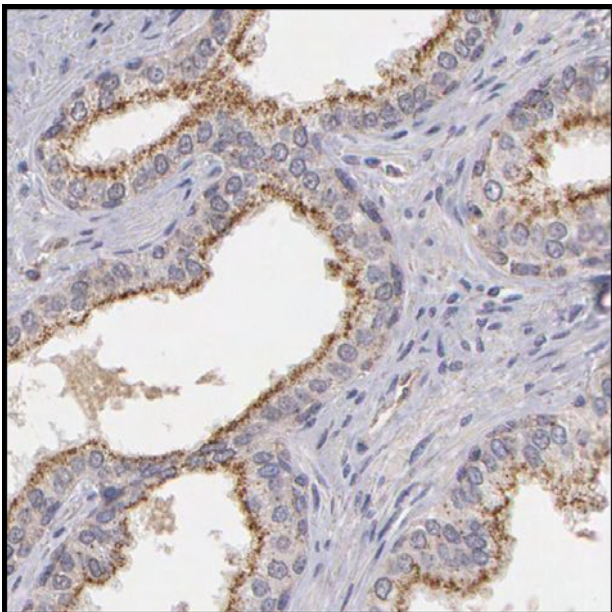
Antibody: HPA000992
Tissue: Gall bladder

Lysosomes



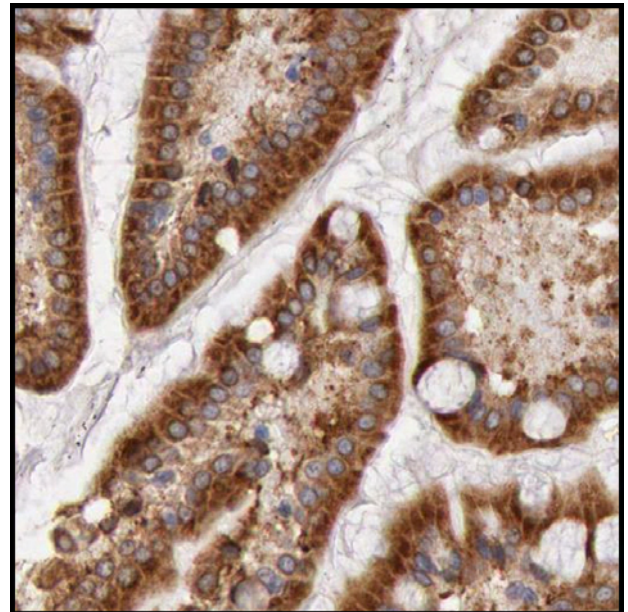
Antibody: HPA000966
Tissue: Duodenum

Peroxisomes



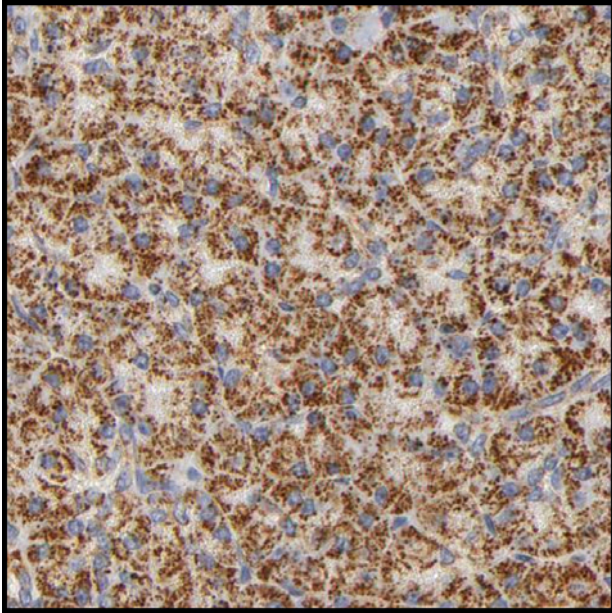
Antibody: CAB001515
Tissue: Prostate

Endoplasmic reticulum



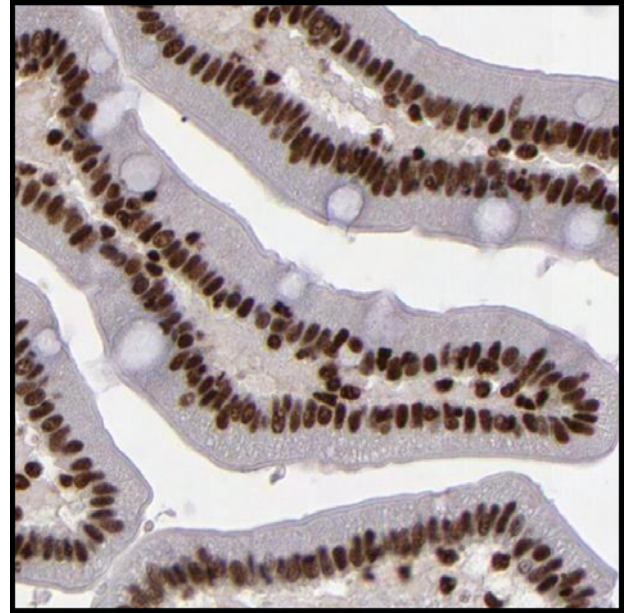
Antibody: HPA001318
Tissue: Small intestine

Mitochondria



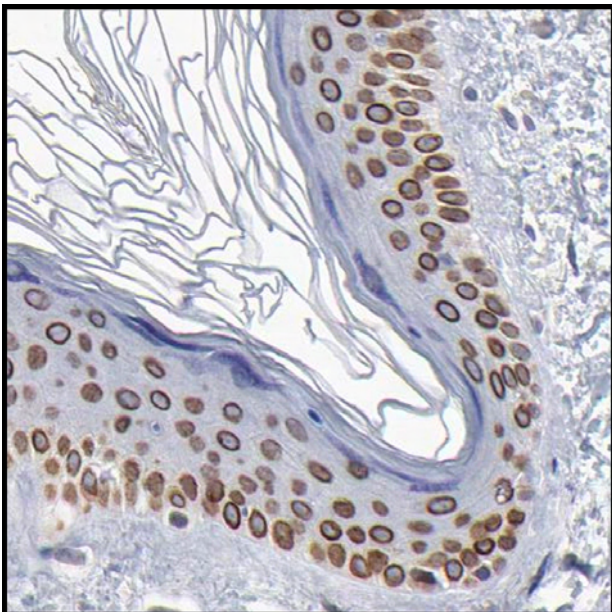
Antibody: CAB004080
Tissue: Pancreas

Nucleus



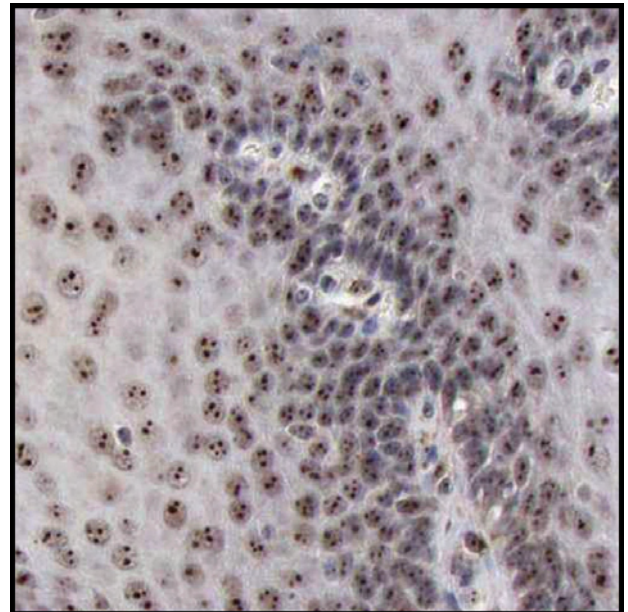
Antibody: HPA002691
Tissue: Duodenum

Nuclear membrane



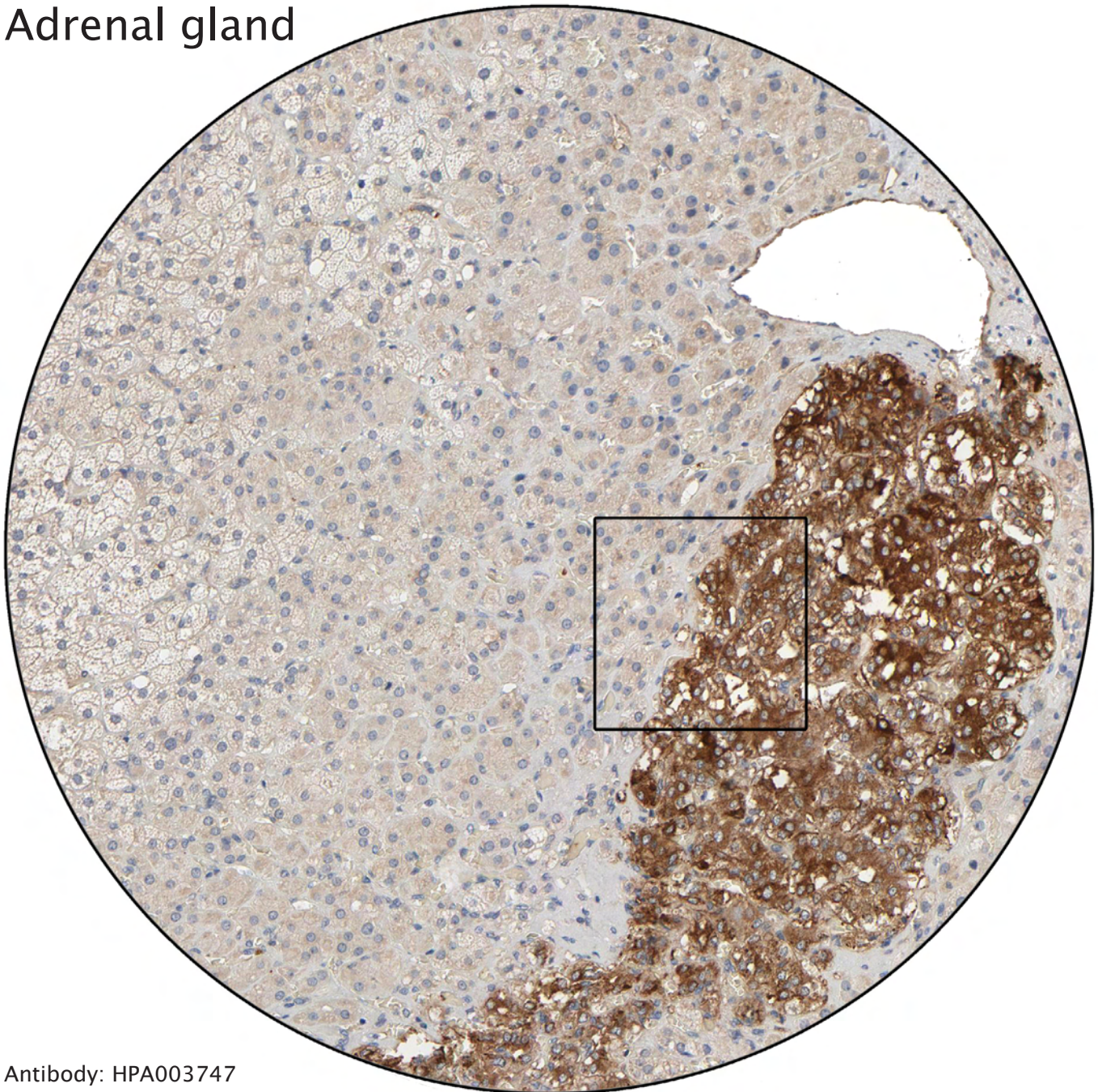
Antibody: HPA003435
Tissue: Skin

Nucleoli

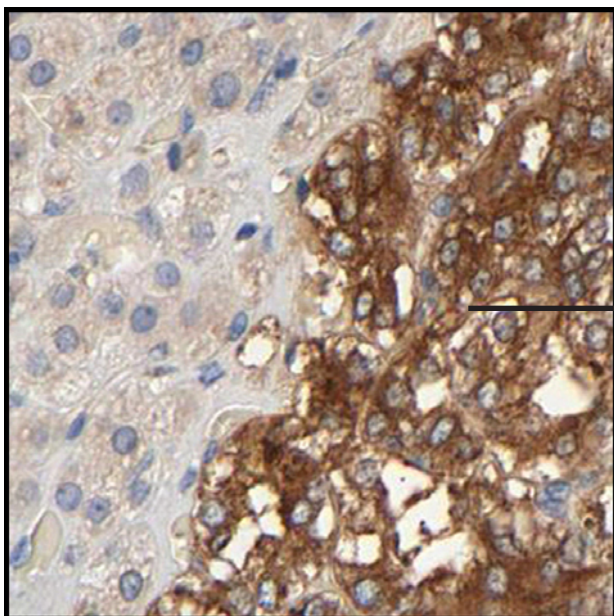


Antibody: HPA001141
Tissue: Esophagus

Adrenal gland

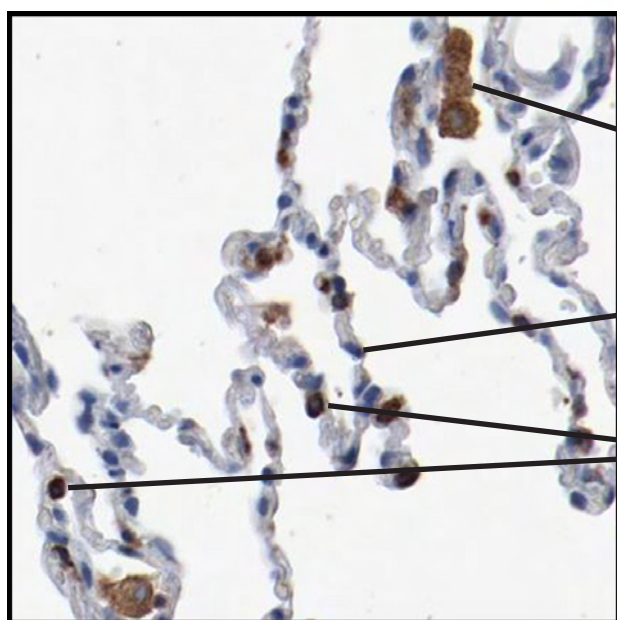
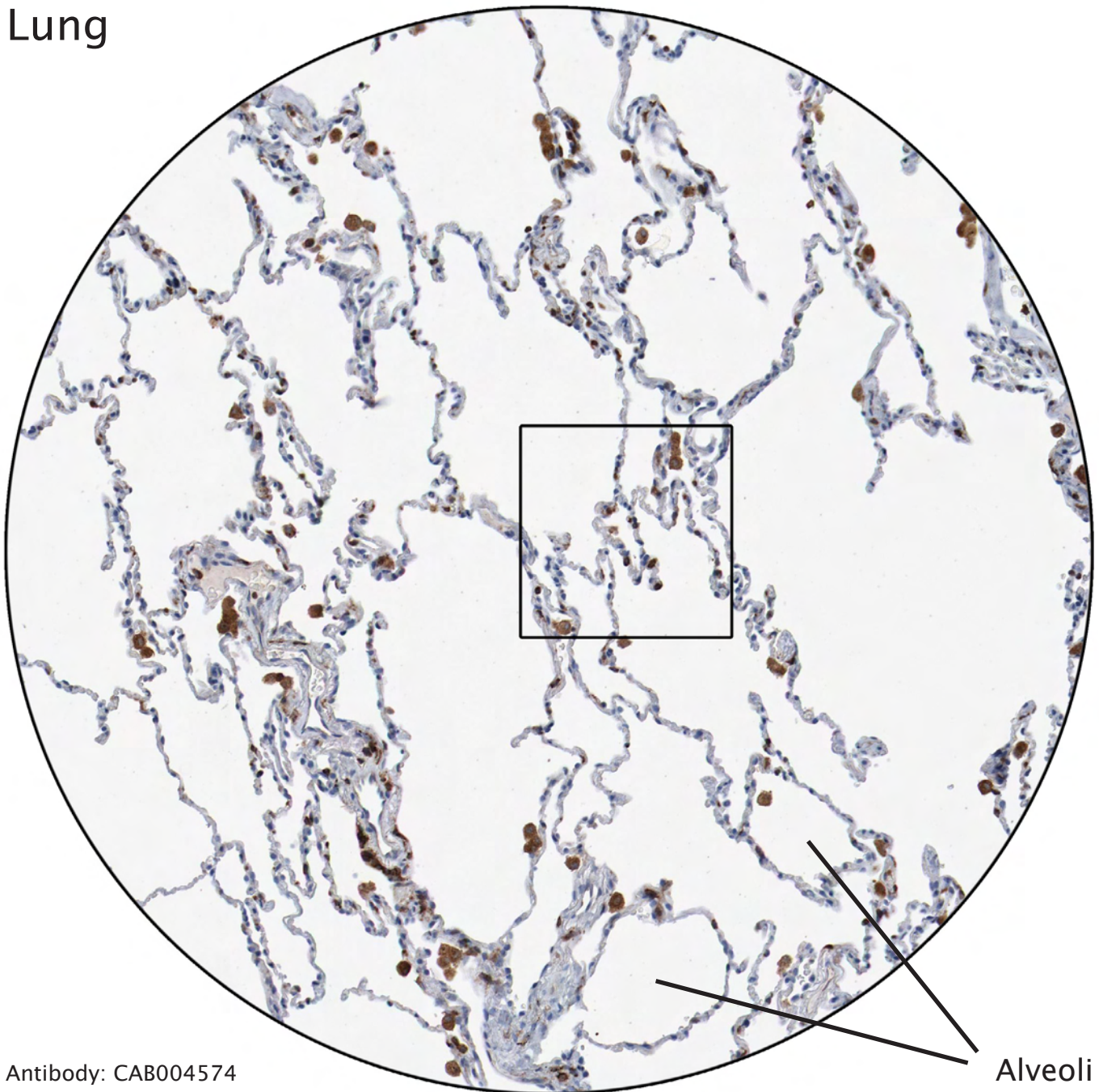


Antibody: HPA003747



The strongly stained neuro-endocrine cells represent adrenal medulla. The cortical cells are negative.

Lung



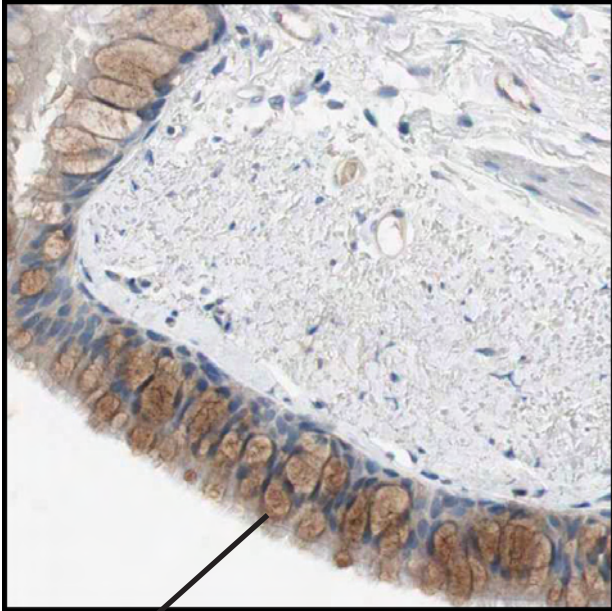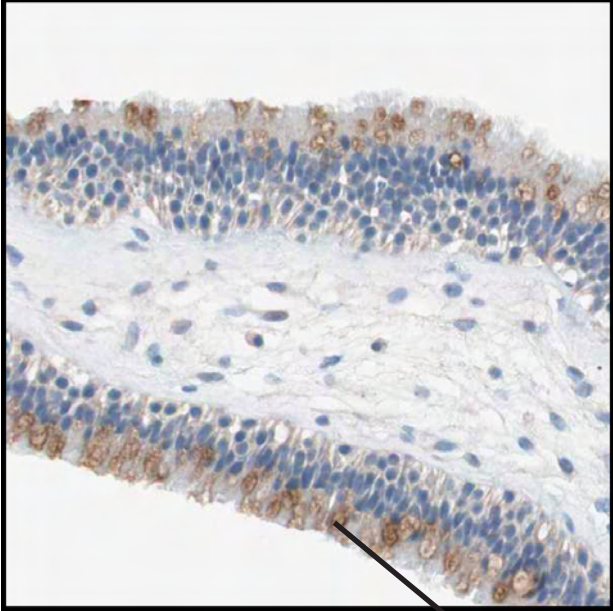
Macrophages strongly stained.

Type I pneumocytes negative.

Typ II pneumocytes distinctly positive.

Nasopharynx

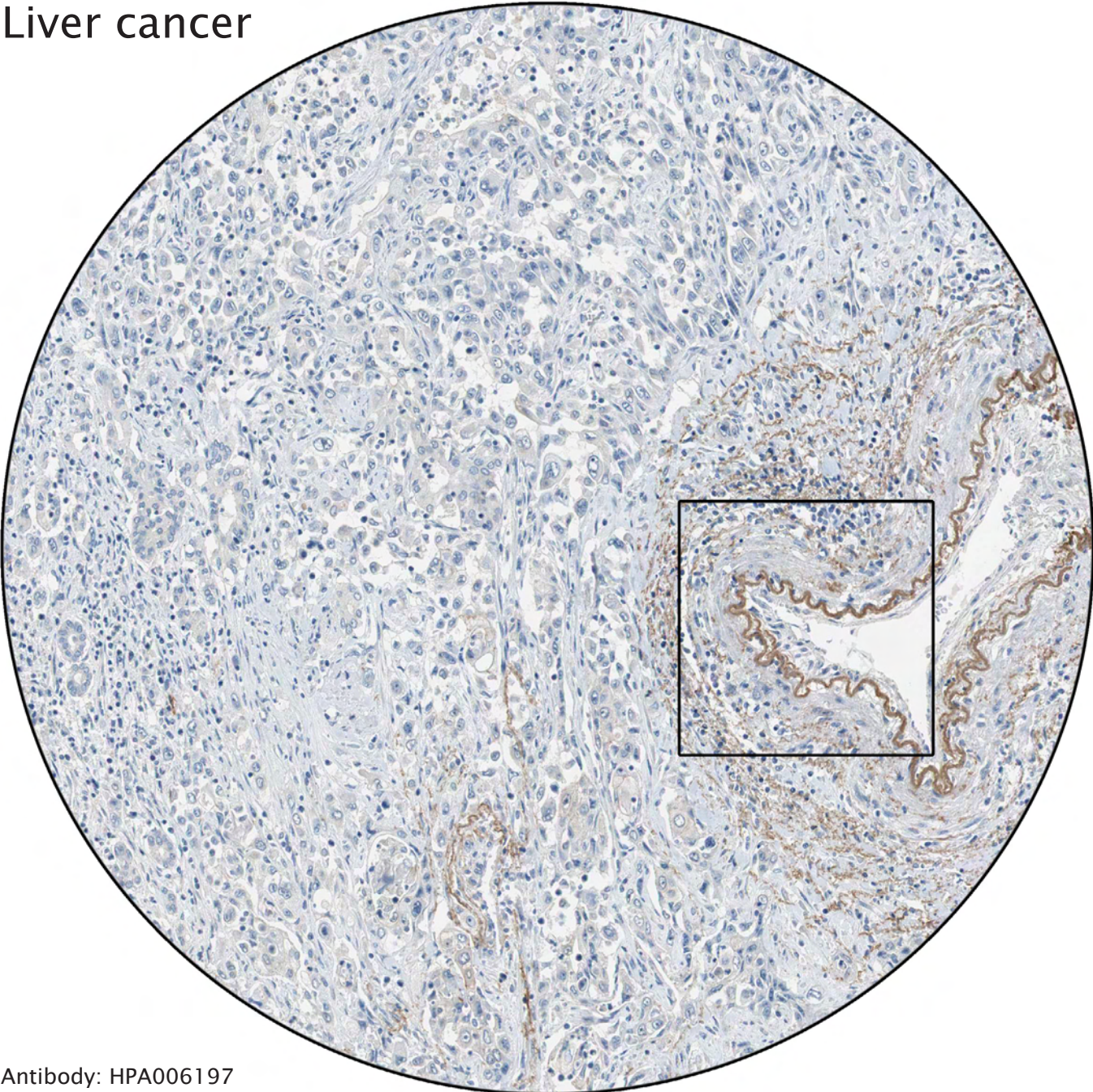
Bronchus



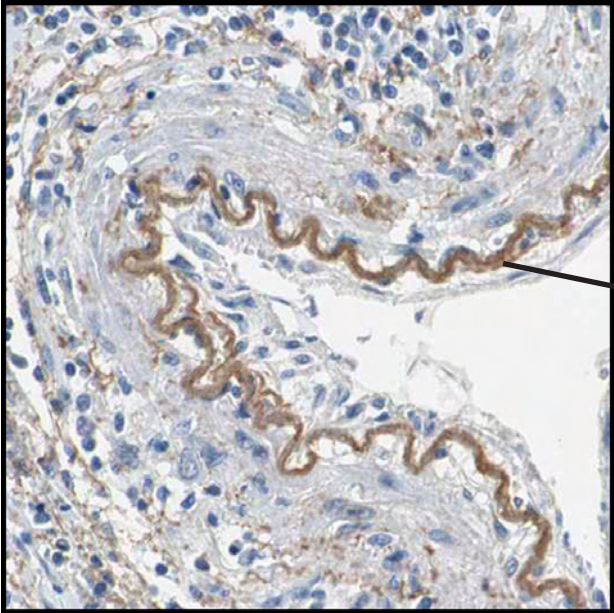
Antibody: HPA007040

Distinct staining of goblet cells.

Liver cancer

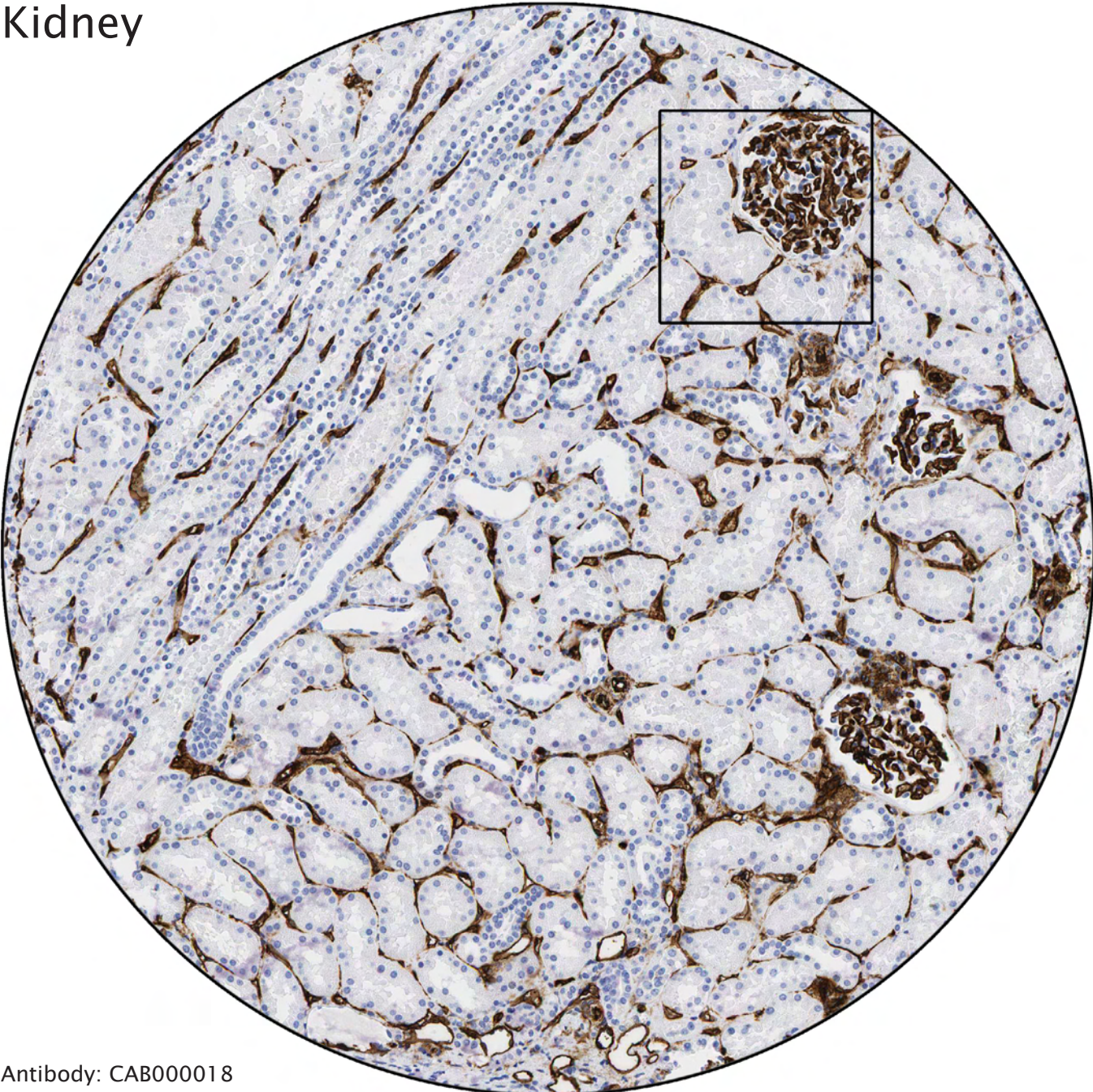


Antibody: HPA006197

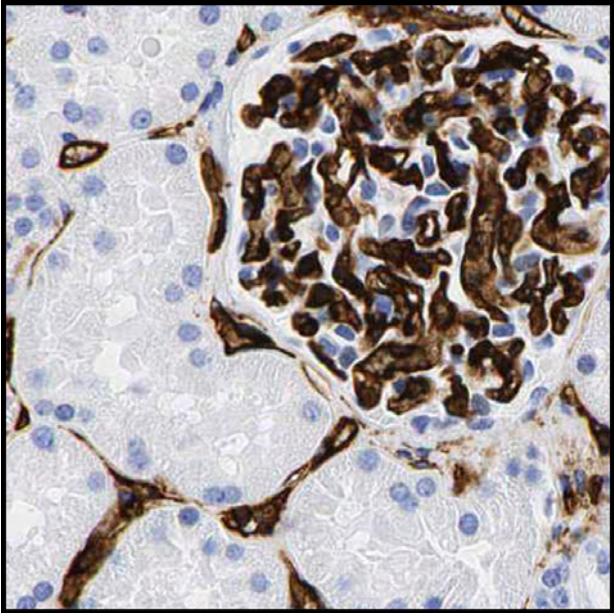


Internal elastic lamina. The layer closest to the endothelium in artery walls.

Kidney

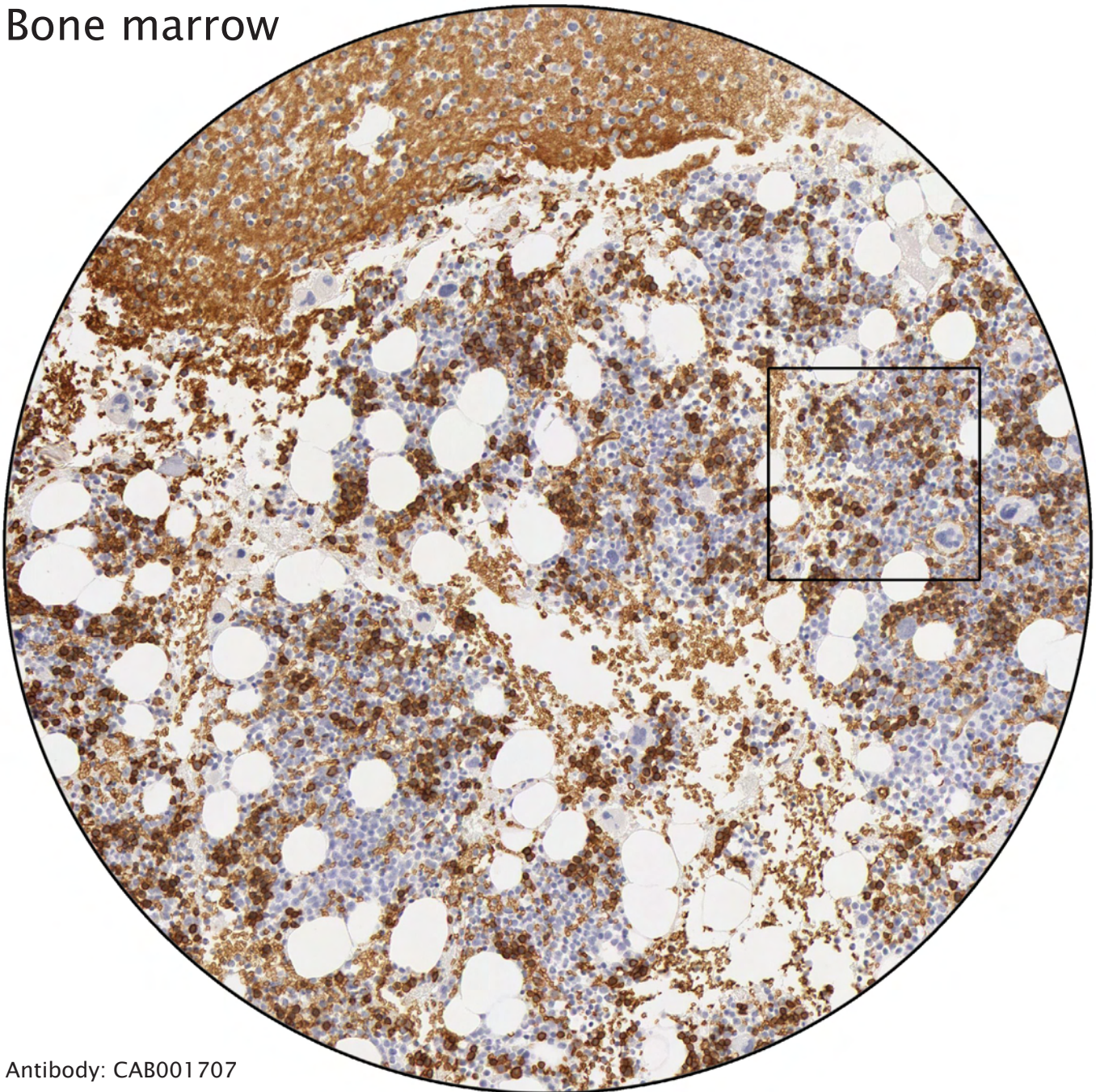


Antibody: CAB000018

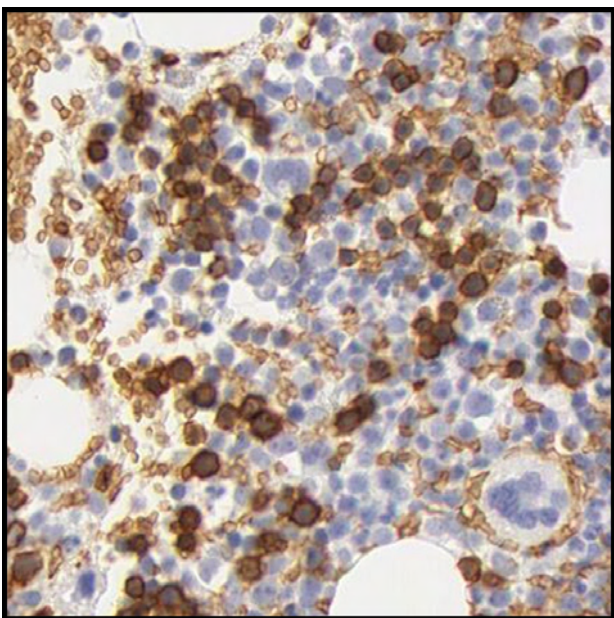


Distinct staining of endothelial cells. All other cells are negative.

Bone marrow



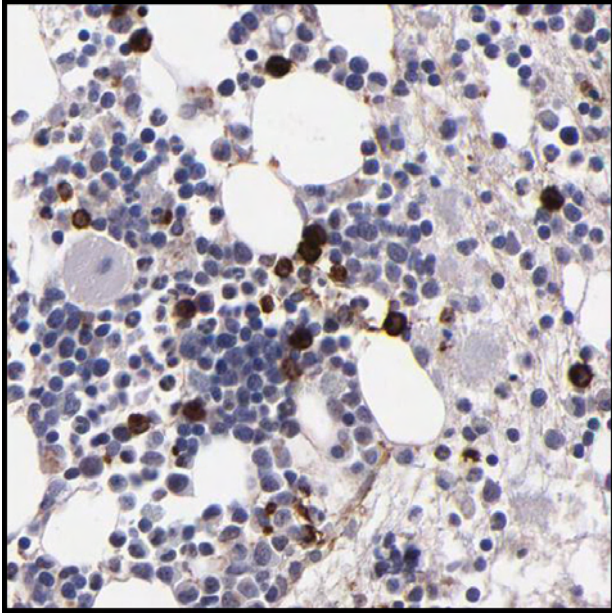
Antibody: CAB001707



Erythropoiesis. Both mature erythrocytes and cells undergoing erythropoiesis are distinctly stained.

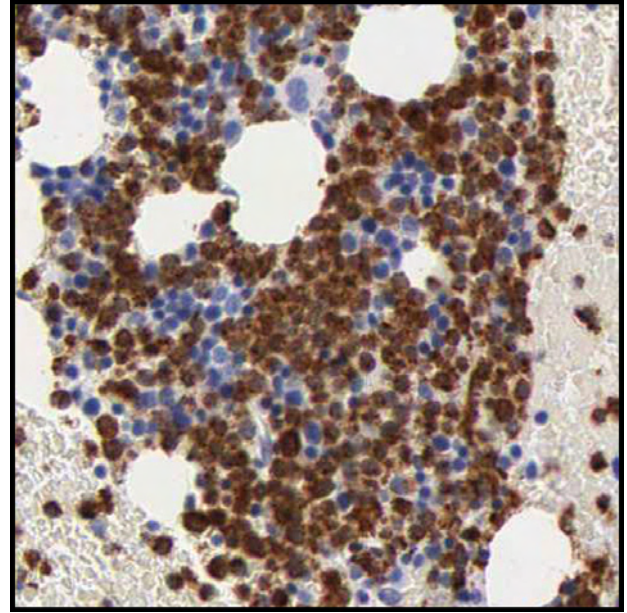
Bone marrow

Antibody: HPA002127



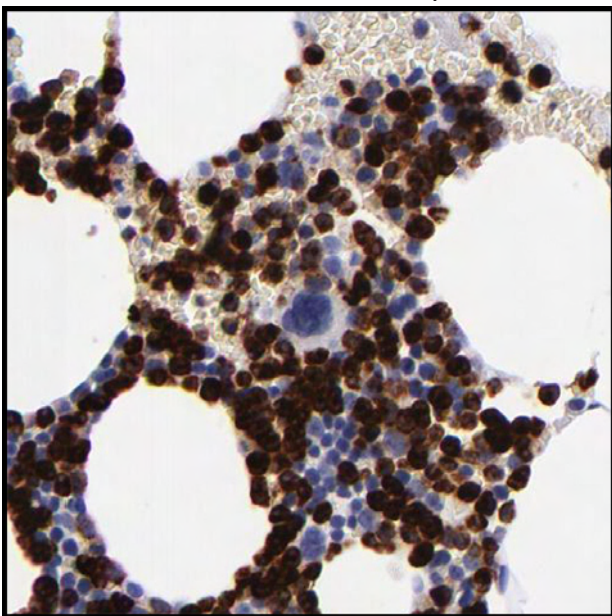
Monocytoïd cells strongly positive.

Antibody: CAB000110



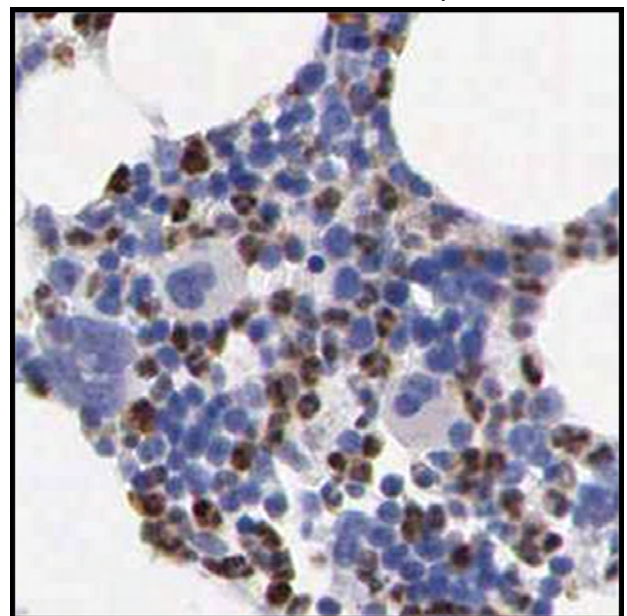
Distinct staining of myelopoietic and monocytoïd cells.

Antibody: HPA002274



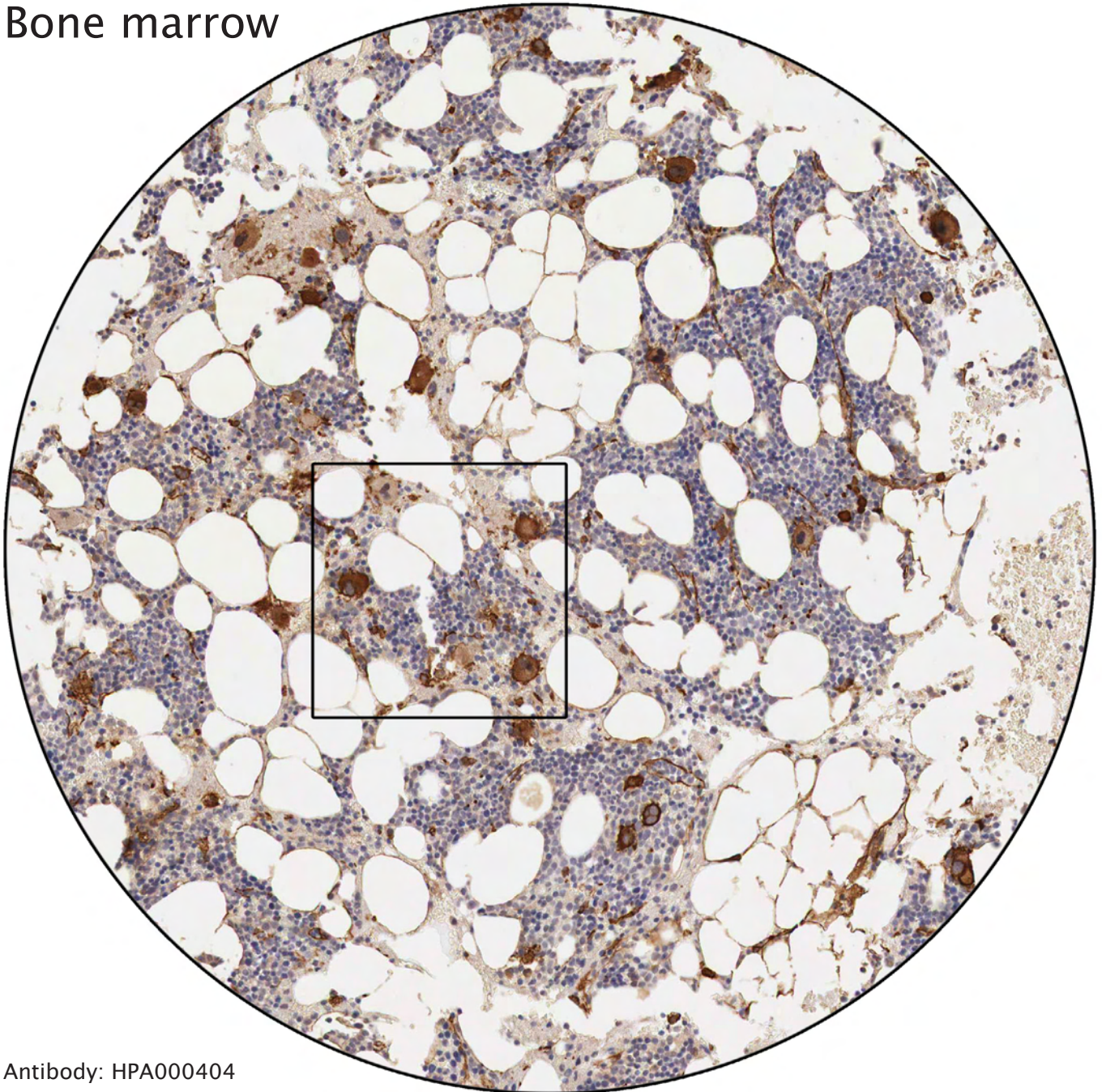
Strong immunoreactivity in all cells except erythrocytic and thrombocytopoietic cells.

Antibody: HPA000727

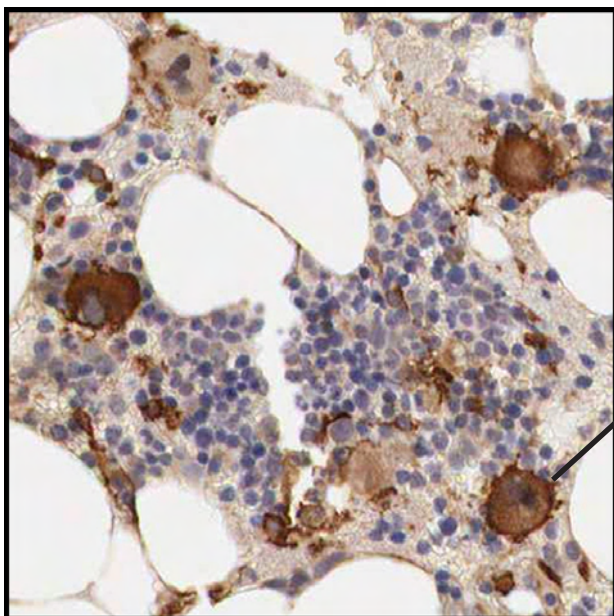


Positivity of mature myelopoietic cells.

Bone marrow

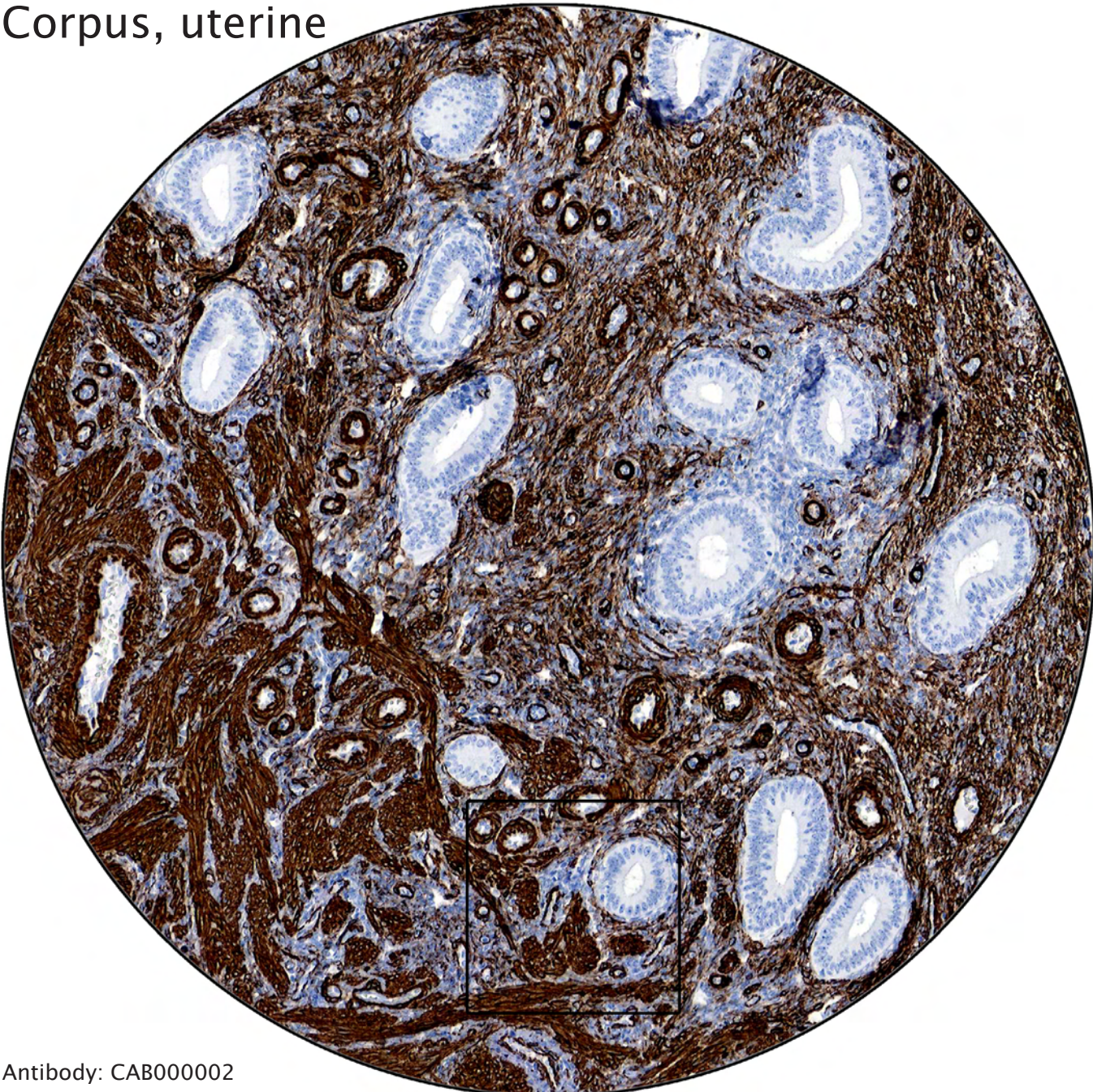


Antibody: HPA000404

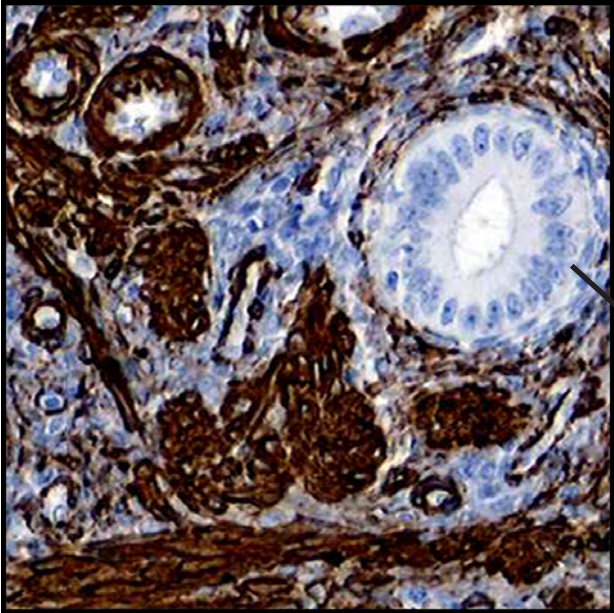


Megakaryocytes strongly stained. Platelets arise by fragmentation of the cytoplasm of mature megakaryocytes.

Corpus, uterine



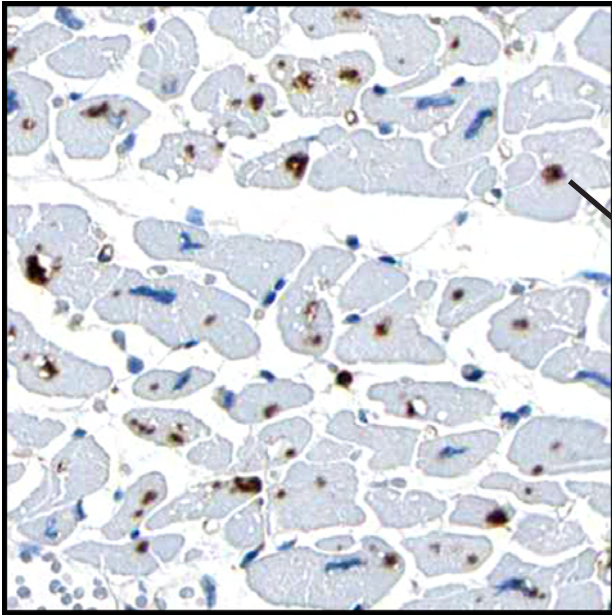
Antibody: CAB000002



Strong positivity of smooth muscle cells.

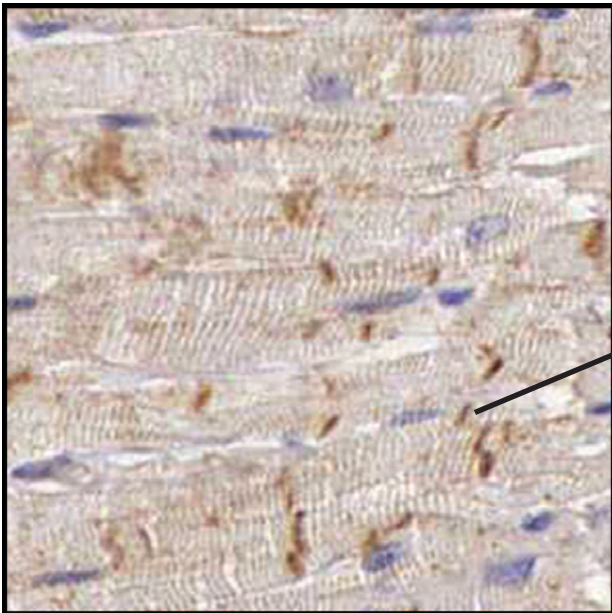
Glandular cells negative.

Heart muscle



Strong positivity of undefined intracytoplasmic structures. The nuclei are negative.

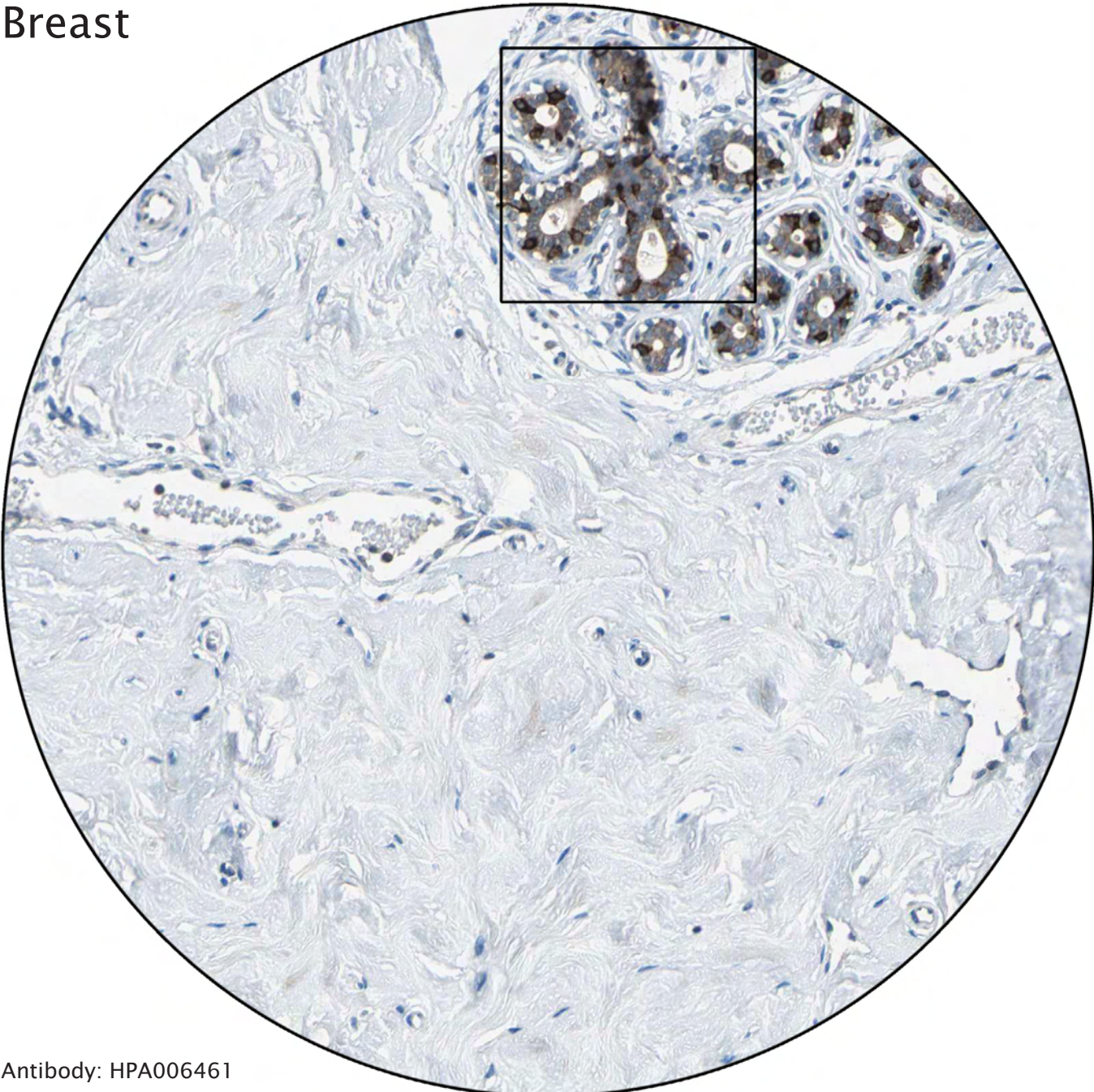
Antibody: HPA005985



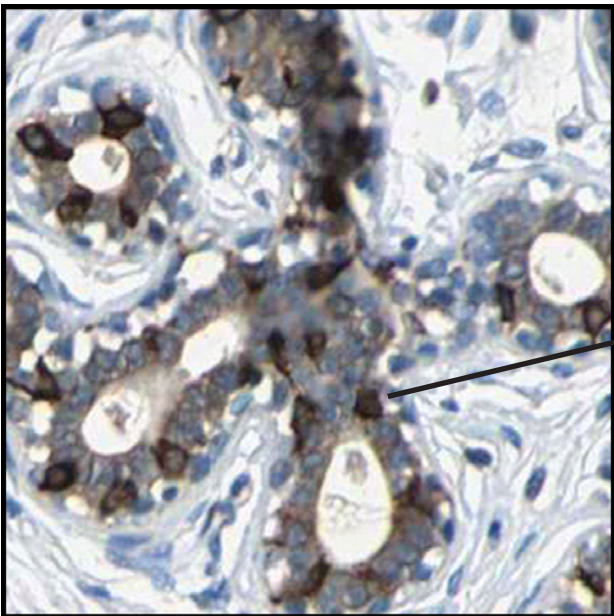
Distinct staining of intercalated discs.

Antibody: HPA001013

Breast

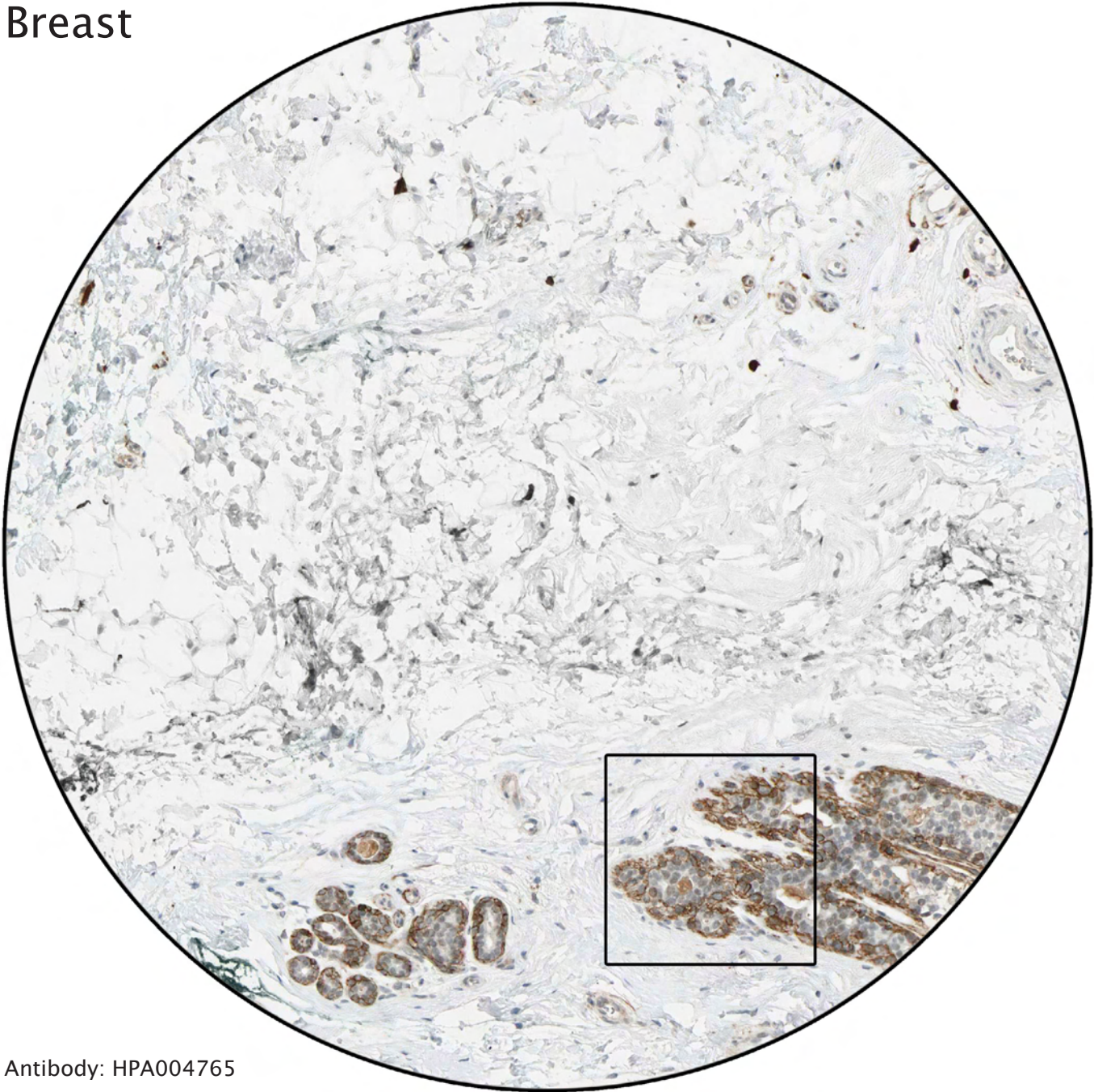


Antibody: HPA006461

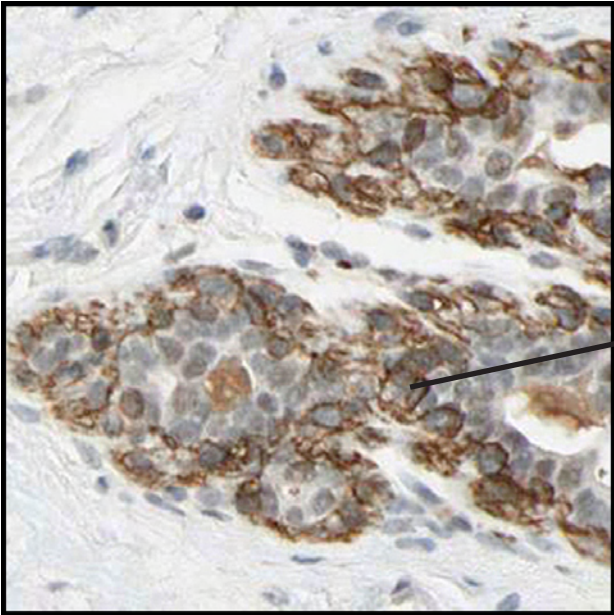


The strongly stained cells are probably normal glandular cells with a special type of activity (expressed protein). The number of positive cells is too high to resemble endocrine cells.

Breast

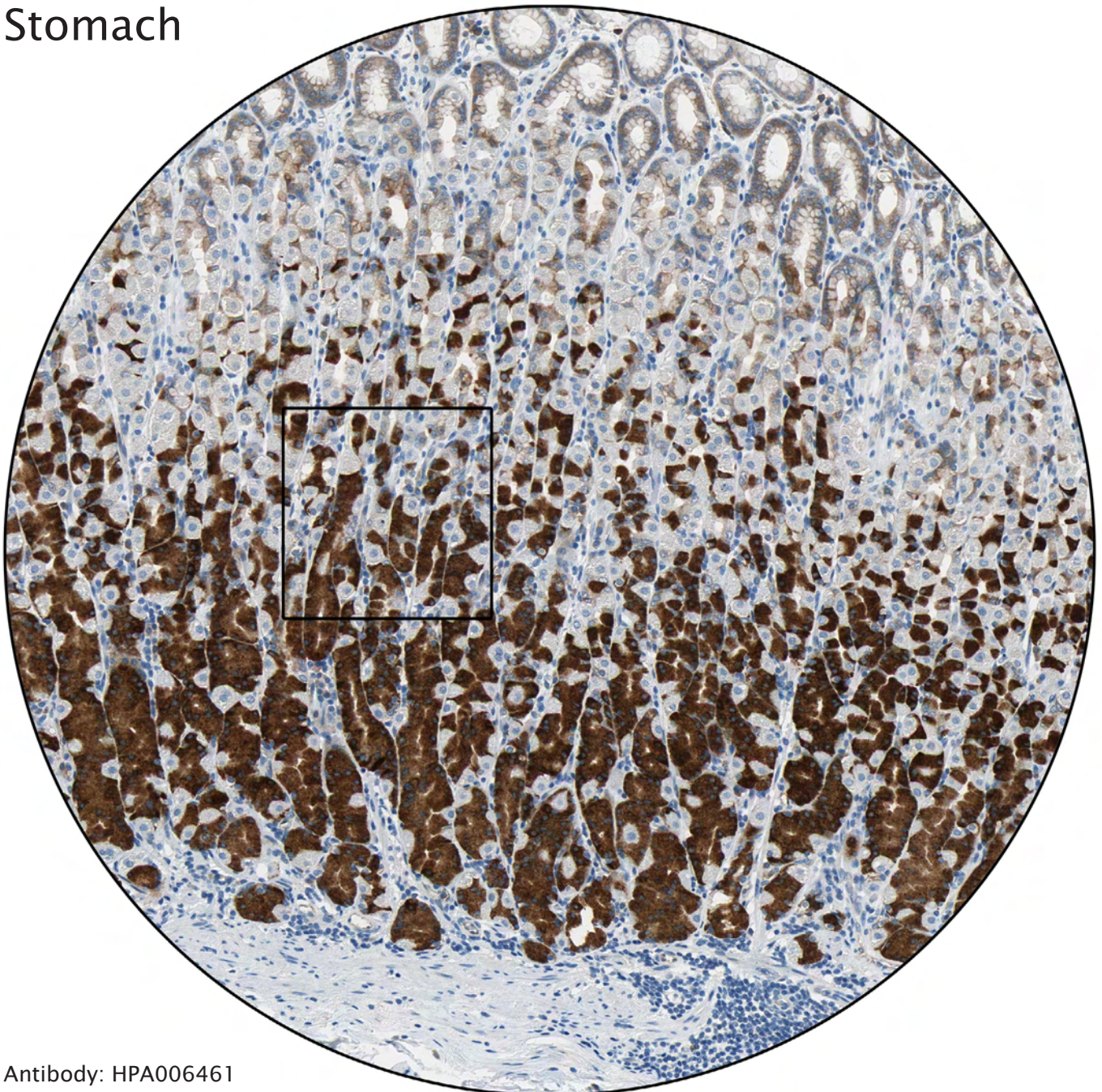


Antibody: HPA004765

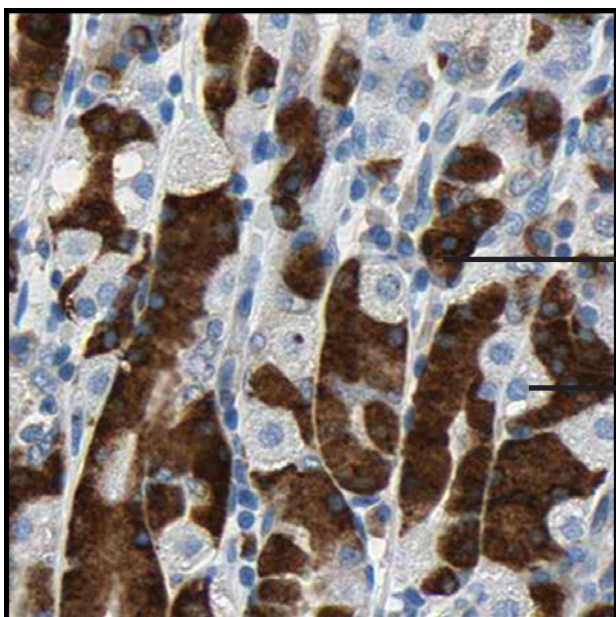


Myoepithelial layer distinctly stained.

Stomach



Antibody: HPA006461

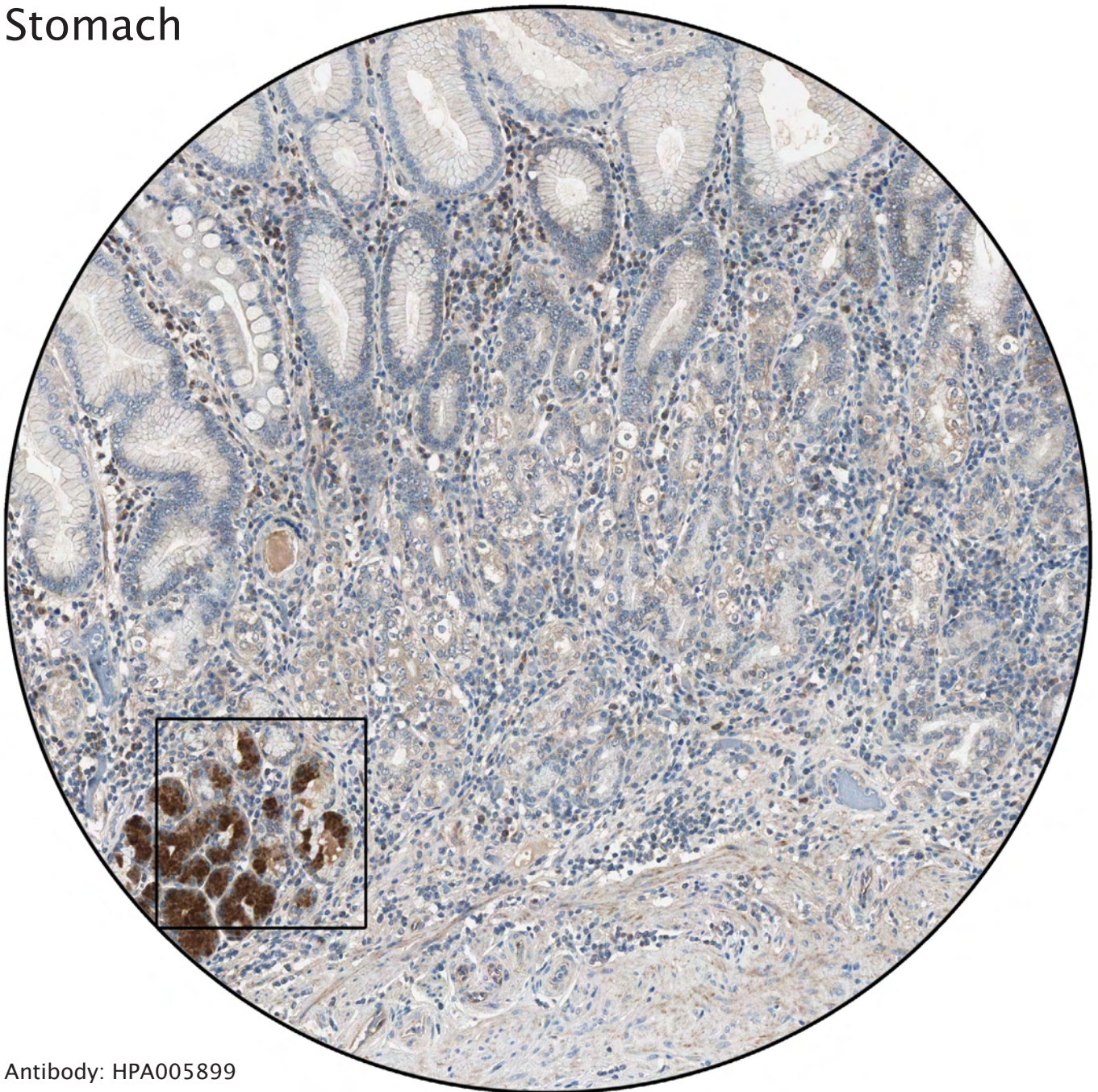


Strongly stained chief cells.

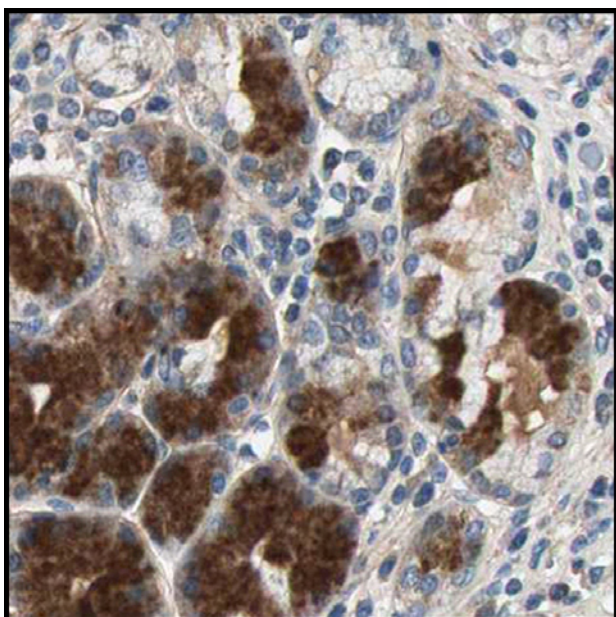
Negative parietal cells.

----- Different celltypes and intracellular structures -----

Stomach

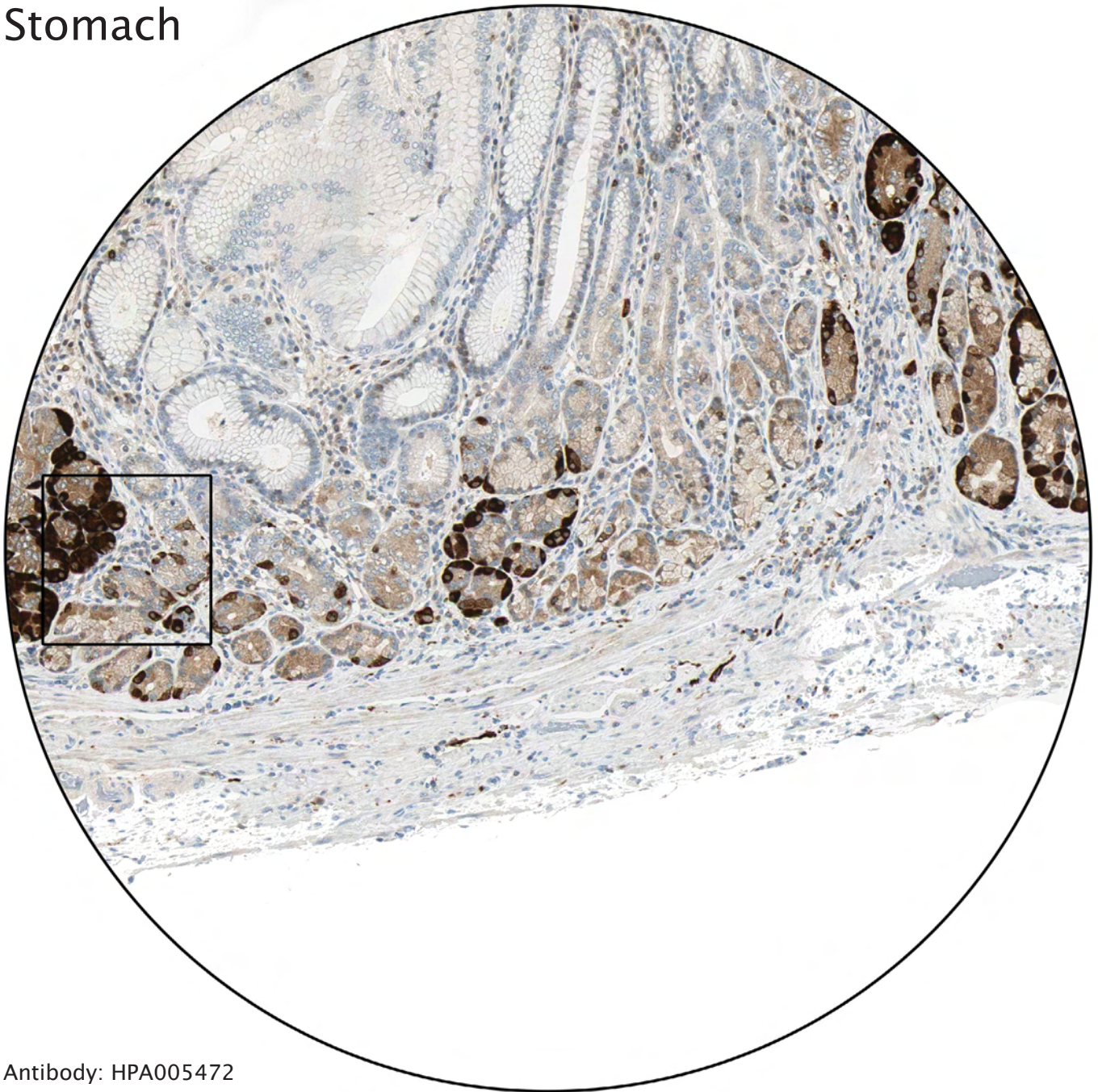


Antibody: HPA005899

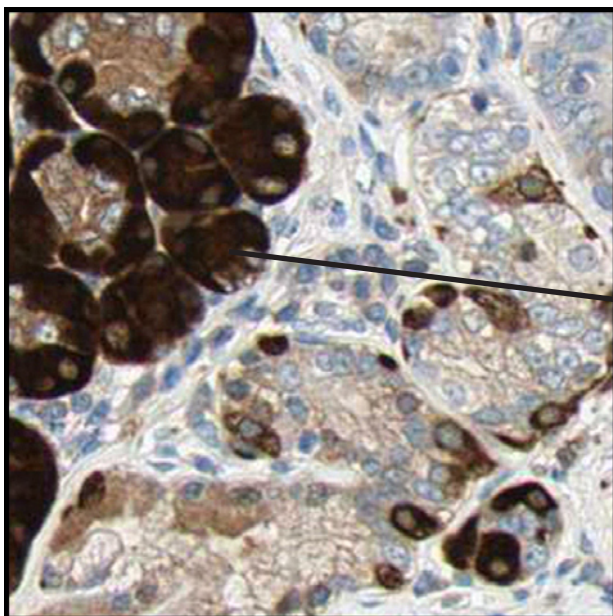


The strongly positive cells probably represent chief cells.

Stomach

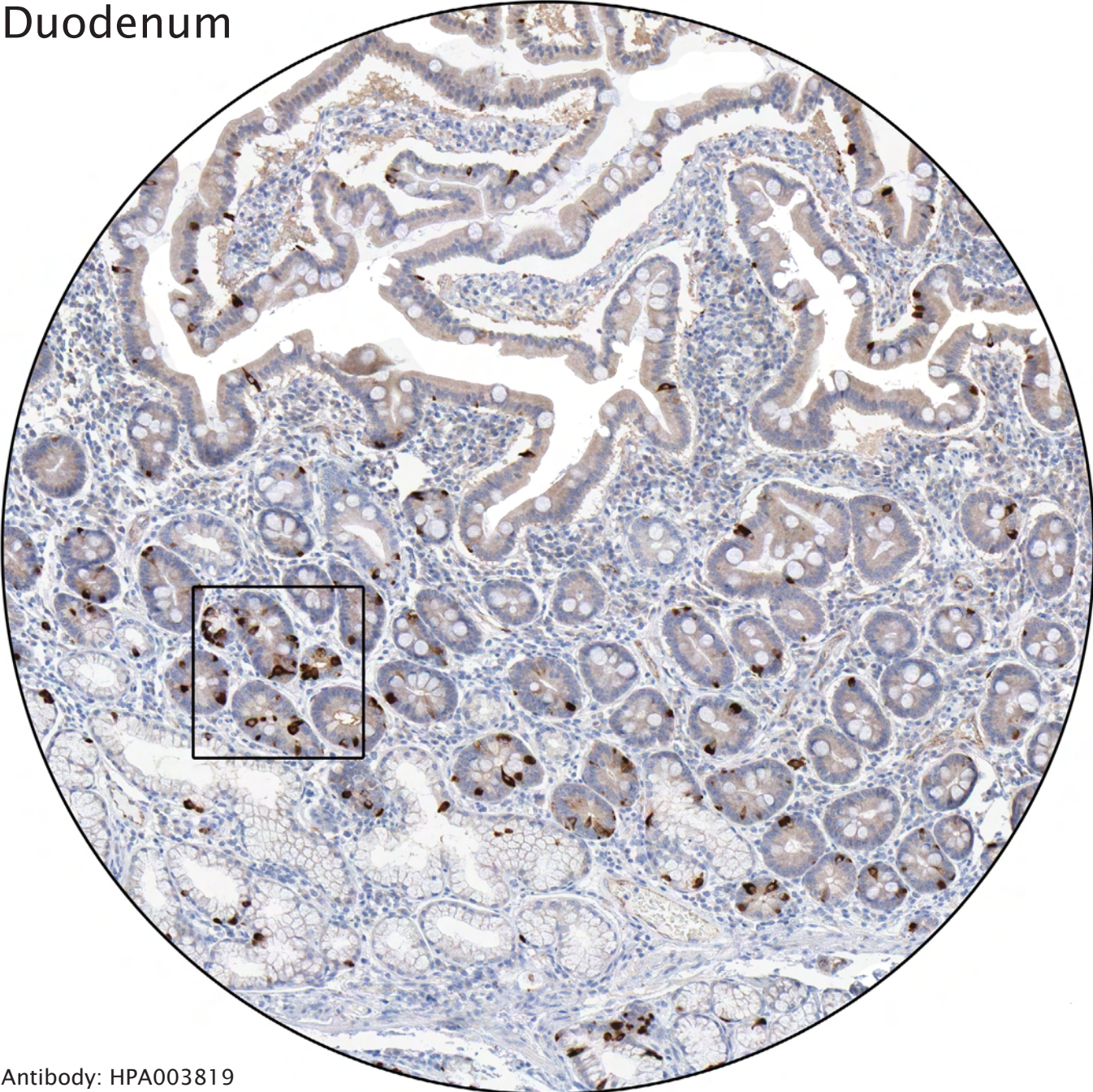


Antibody: HPA005472

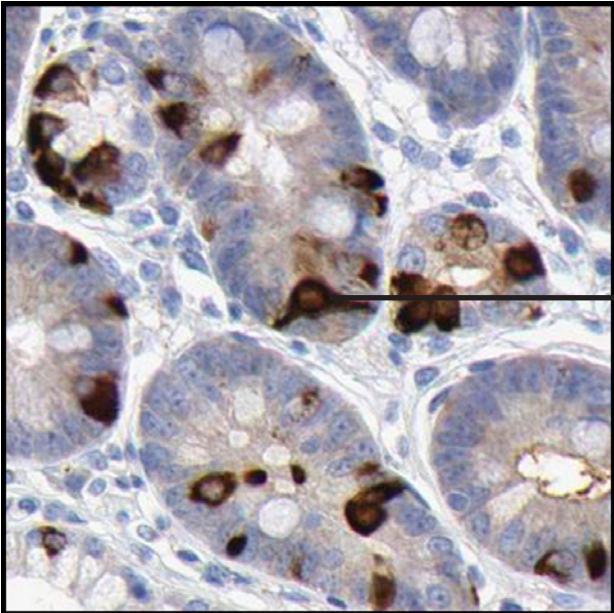


The strongly stained cells probably represent hyperplasia of endocrine cells. In normal stomach mucosa however, the number of endocrine cells is lower.

Duodenum

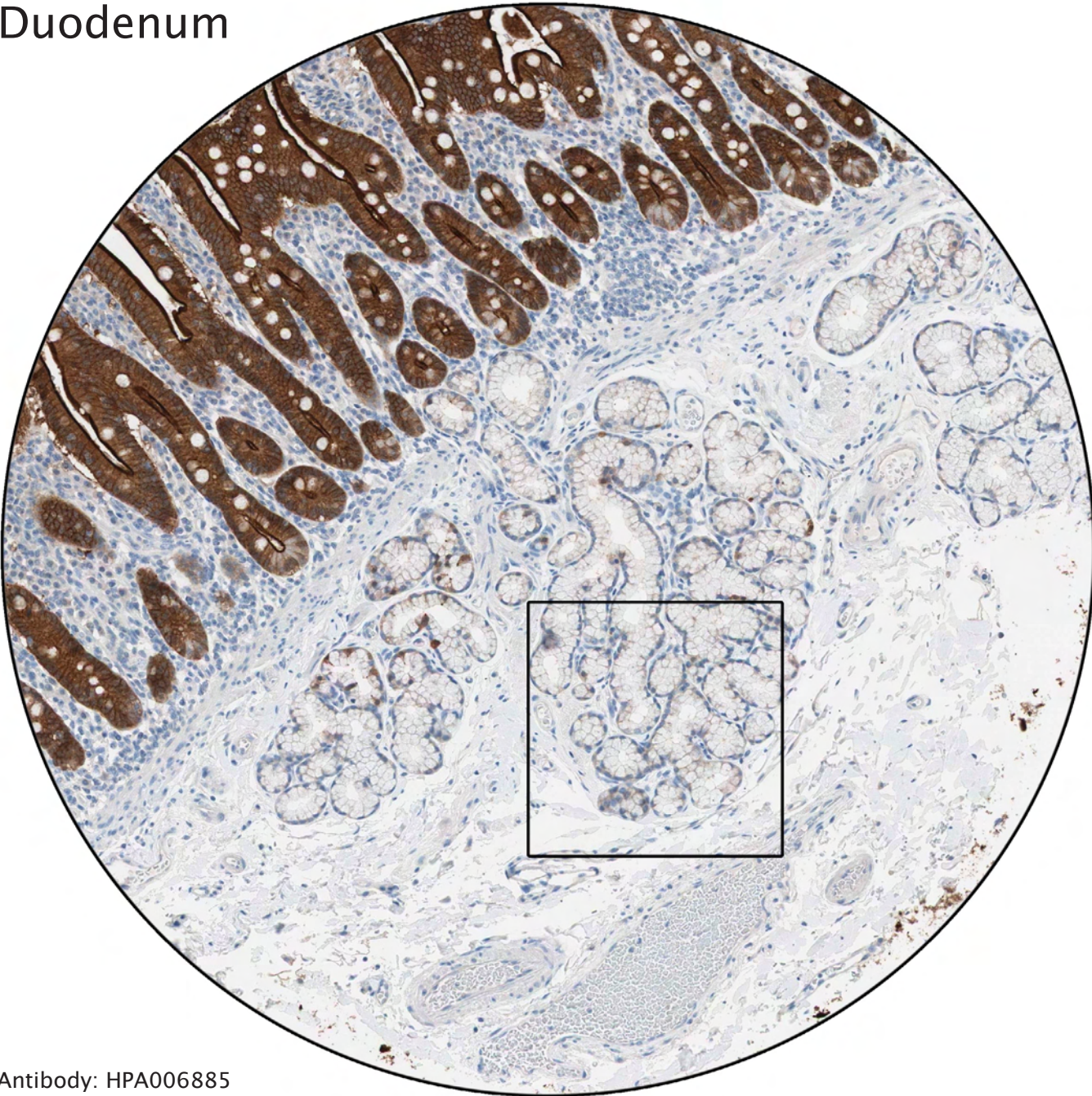


Antibody: HPA003819

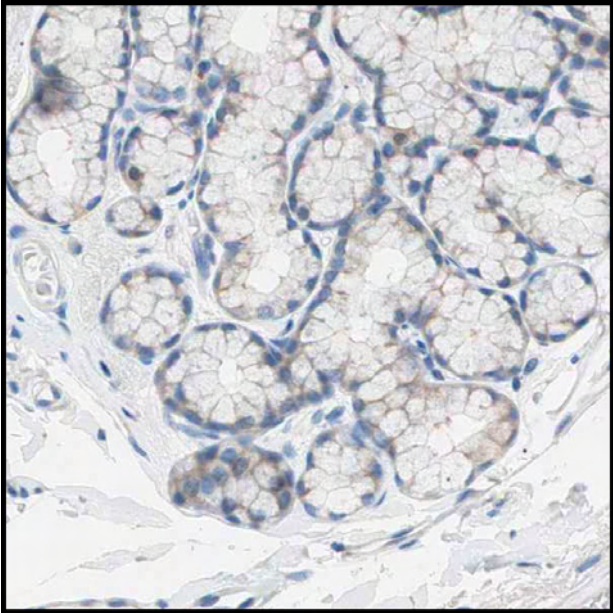


Strong immunoreactivity of endocrine cells.

Duodenum

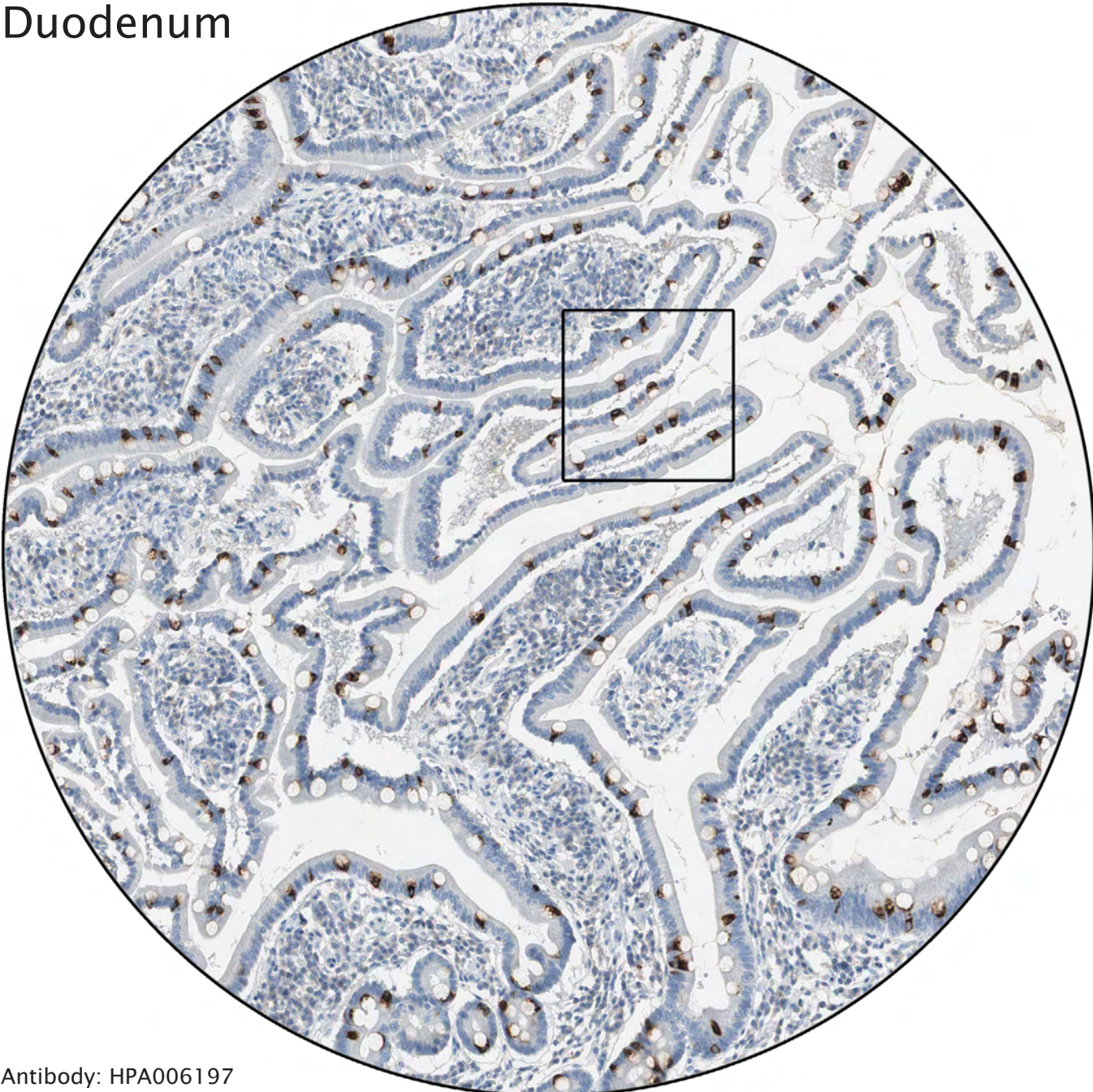


Antibody: HPA006885

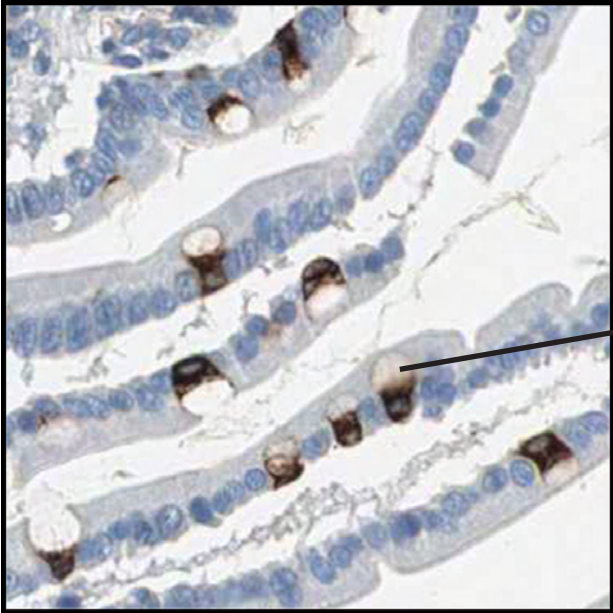

Glands of Brunner, mucous glands situated in the submucosa.

Duodenum

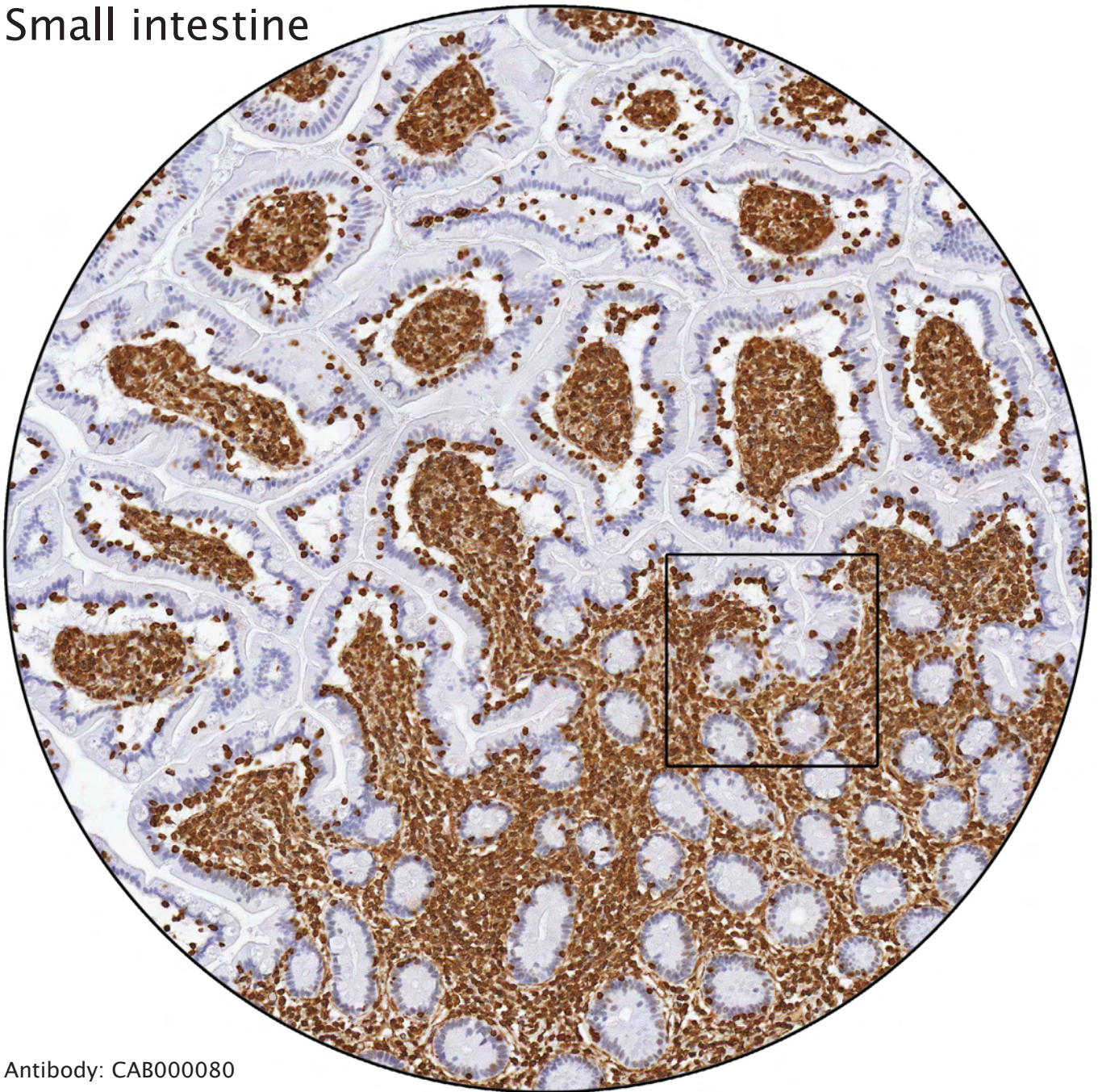

Antibody: HPA006197

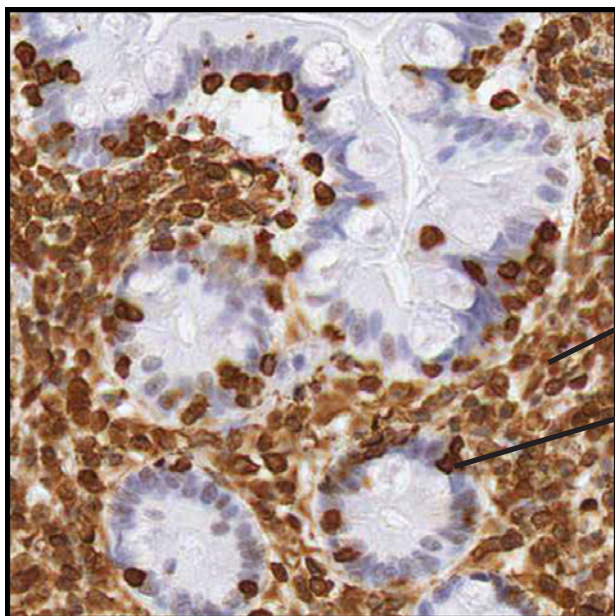


Goblet cells, which produce mucus to protect the intestinal mucosa.

Small intestine



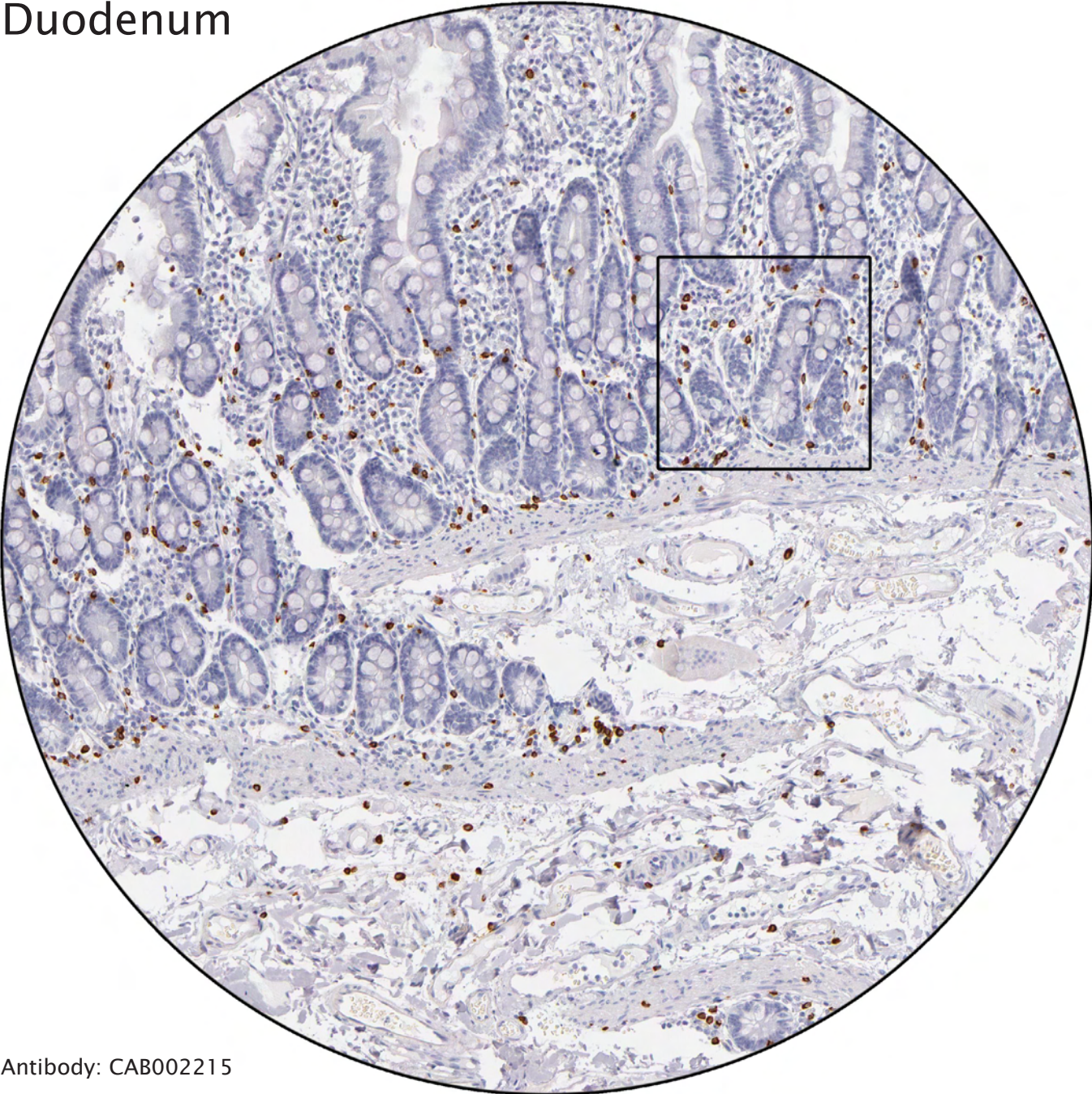Antibody: CAB000080



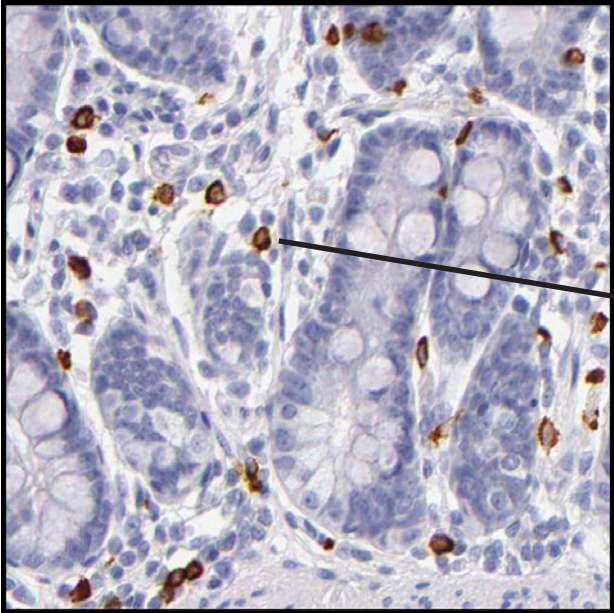
Cells of mesenchymal origin distinctly positive.

Strong staining of lymphocytes.

Duodenum

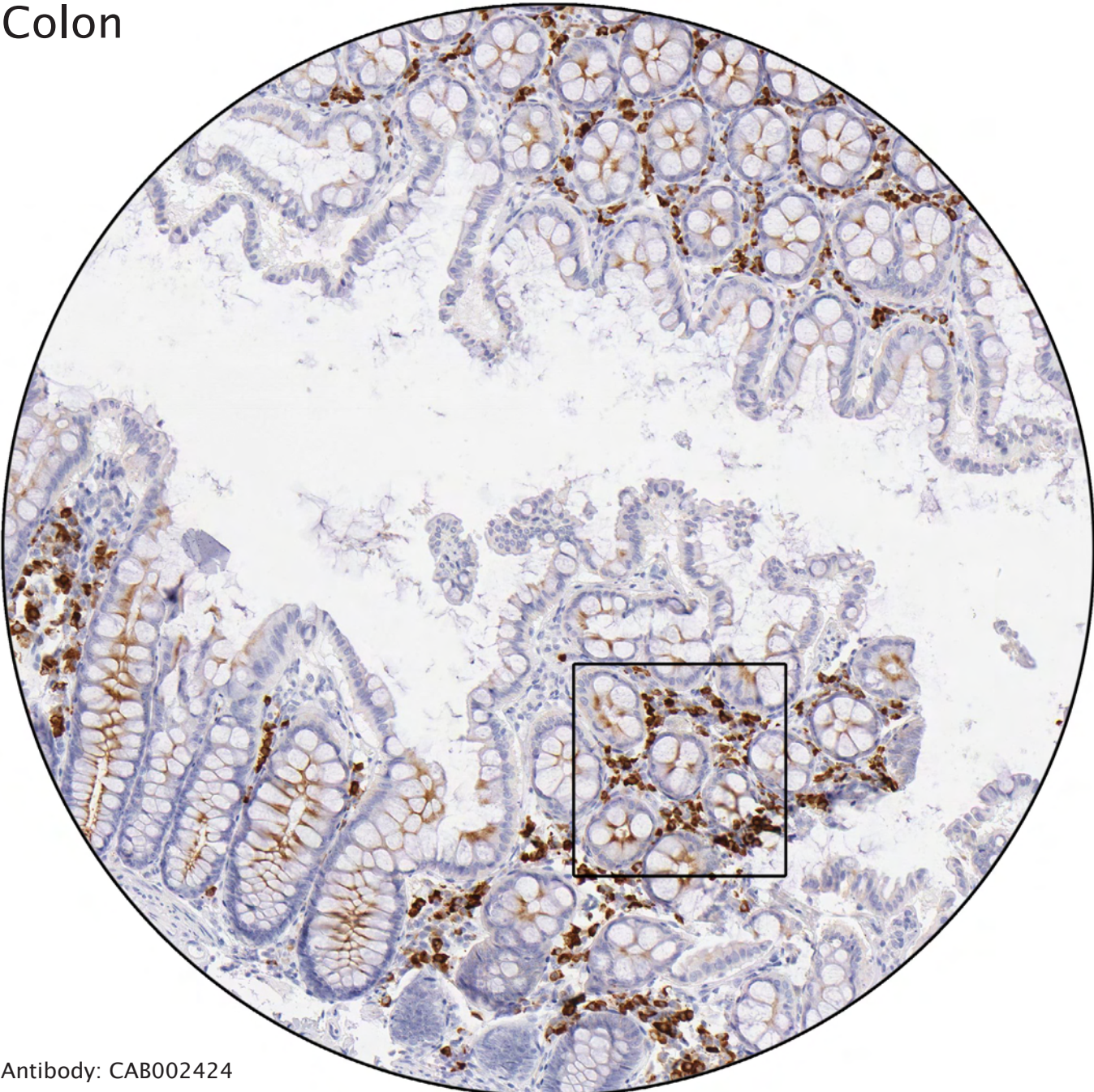


Antibody: CAB002215

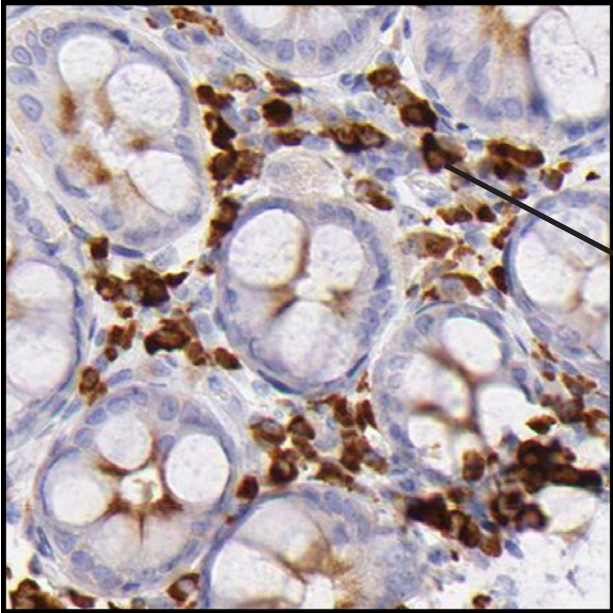


Strong positivity of mast cells.

Colon

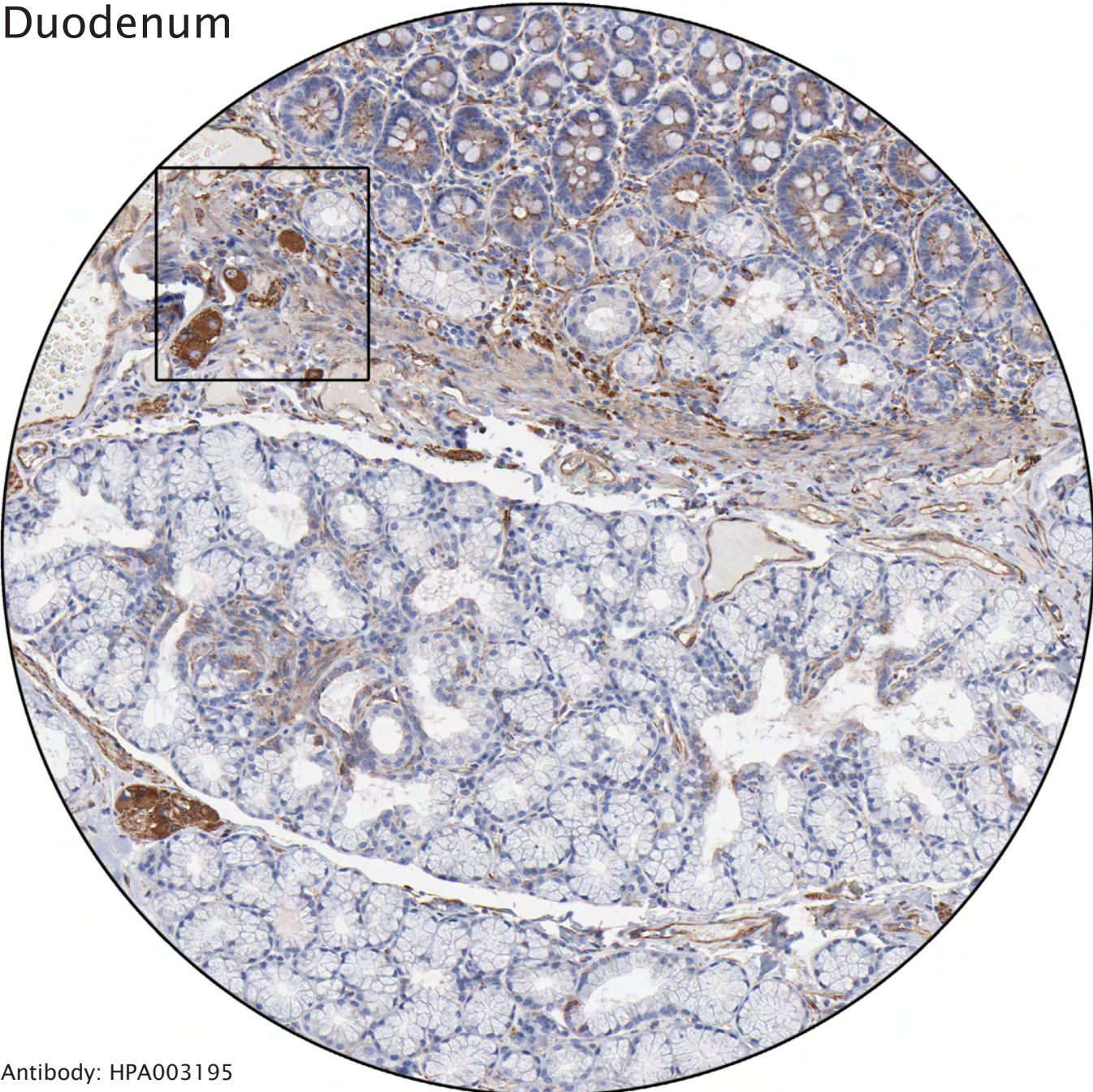


Antibody: CAB002424

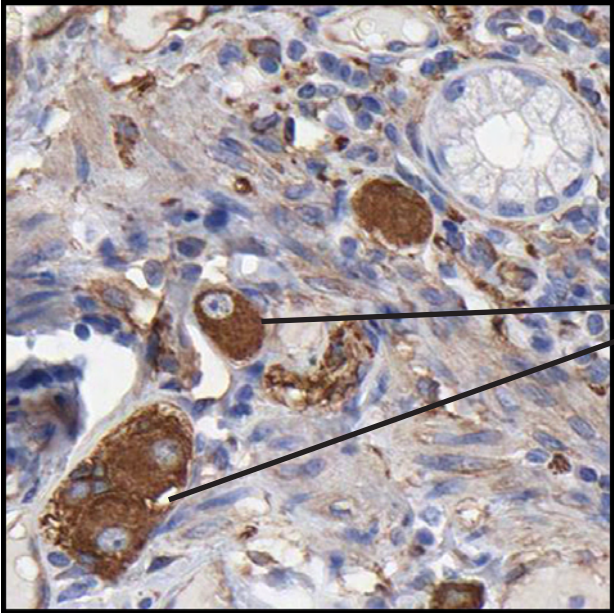


Plasma cells distinctly stained.

Duodenum

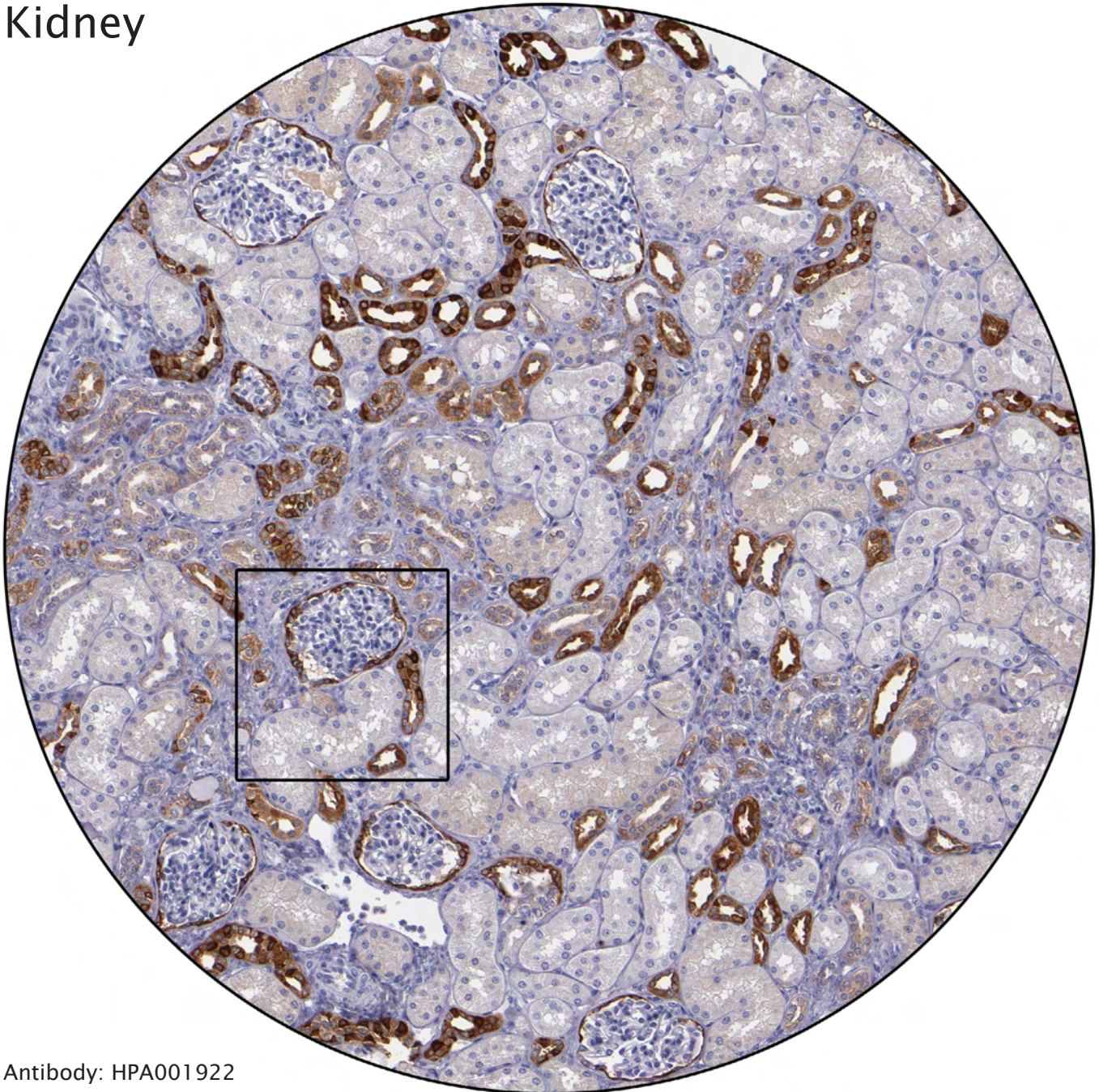


Antibody: HPA003195

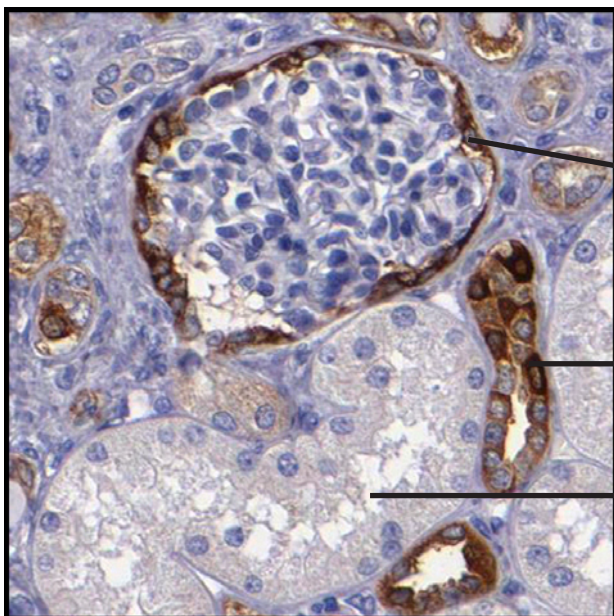


Ganglia, nerve plexa situated in the intestinal wall, involved in transmission of signals for peristaltic movements.

Kidney



Antibody: HPA001922

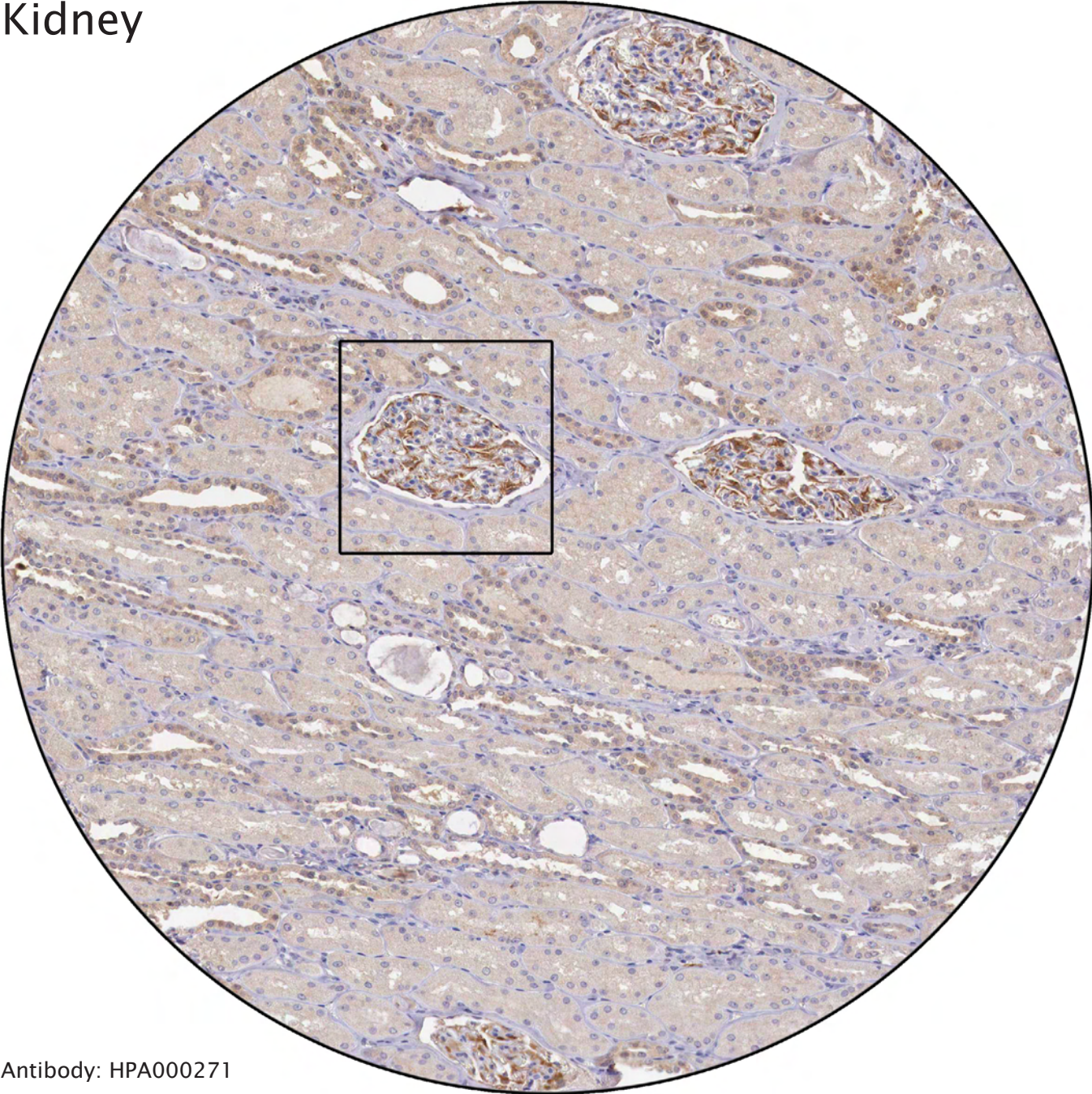


Distinct immunoreactivity of Bowman's capsule. The other cells in glomeruli are negative.

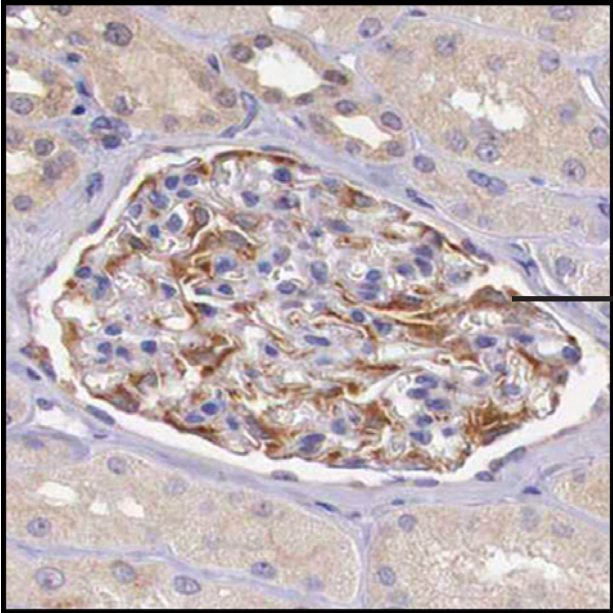
Strong positivity of distal tubules.

Negative proximal tubules.

Kidney

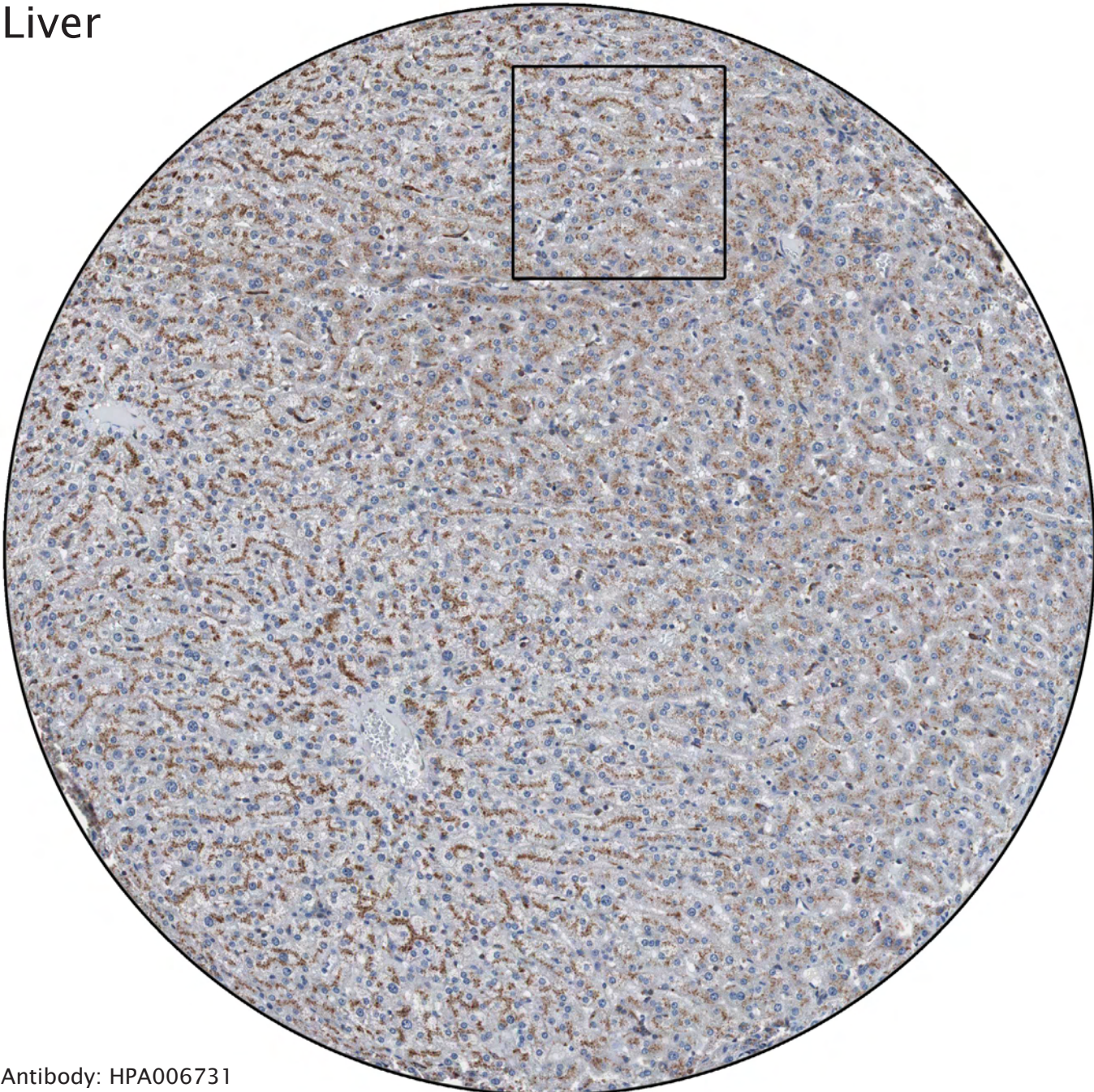

Antibody: HPA000271

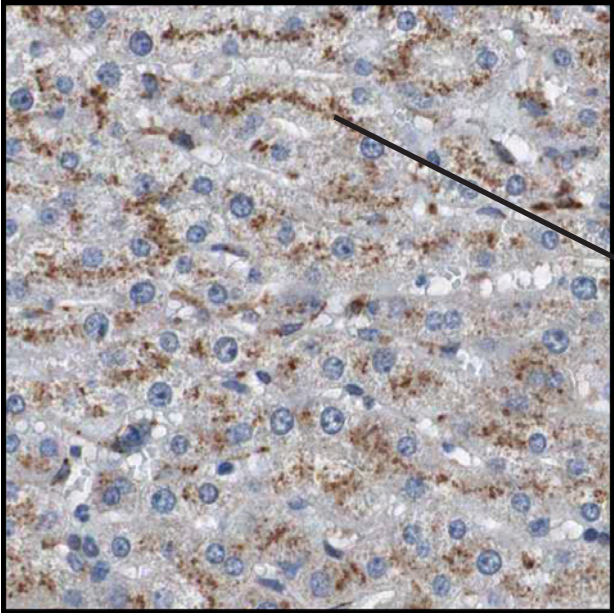


Positivity of podocytes, which have “foot-like” processes connecting to basal membranes of capillaries.

Liver

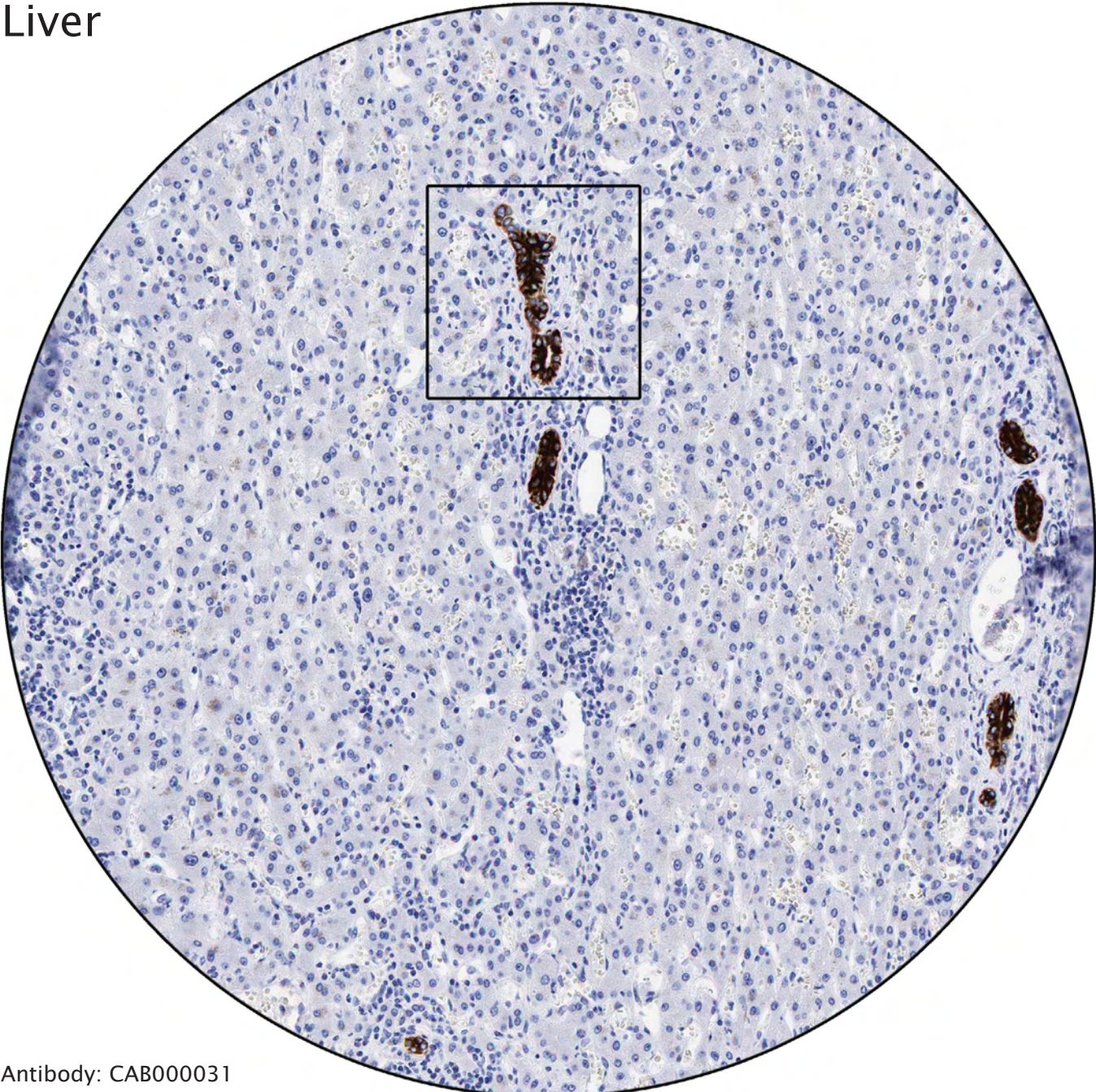


Antibody: HPA006731

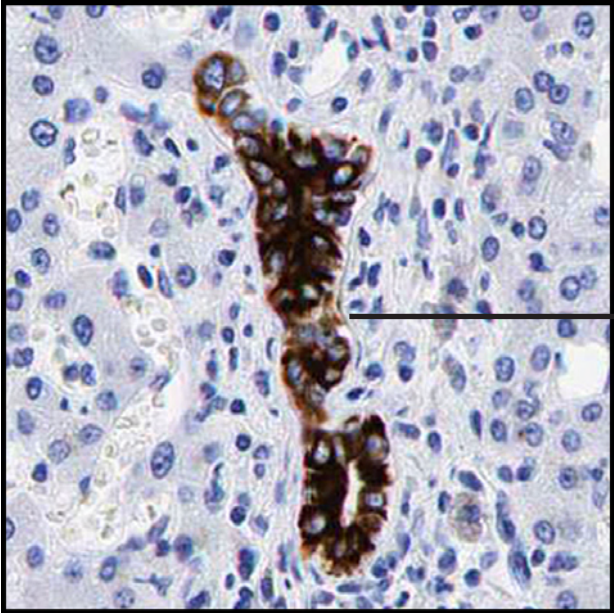

Glycogen-granules in cytoplasm of hepatocytes.

Liver

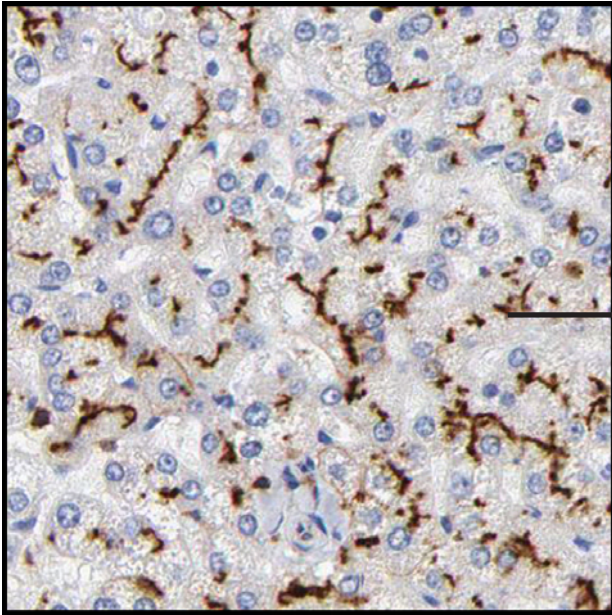


Antibody: CAB000031



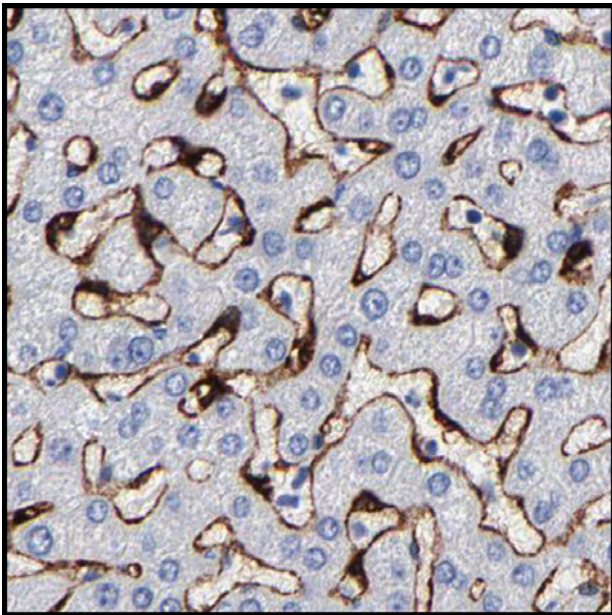
Distinct staining of bile ducts.

Liver



Strong staining of bile canaliculi.

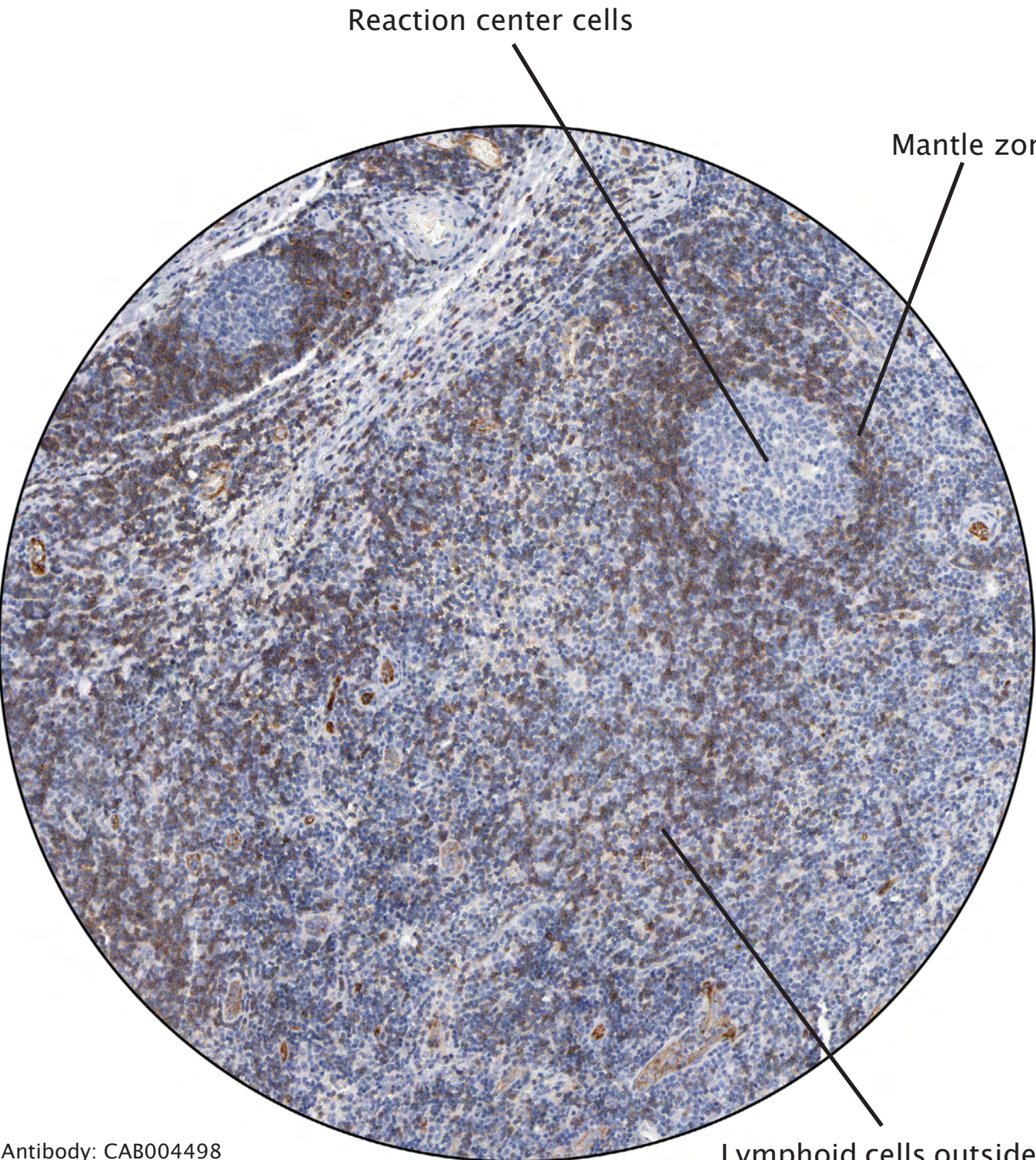
Antibody: CAB004498



Distinct positivity of sinusoids and Kupffer cells (fixed macrophages lining the hepatic sinusoids).

Antibody: CAB003789

Lymph node



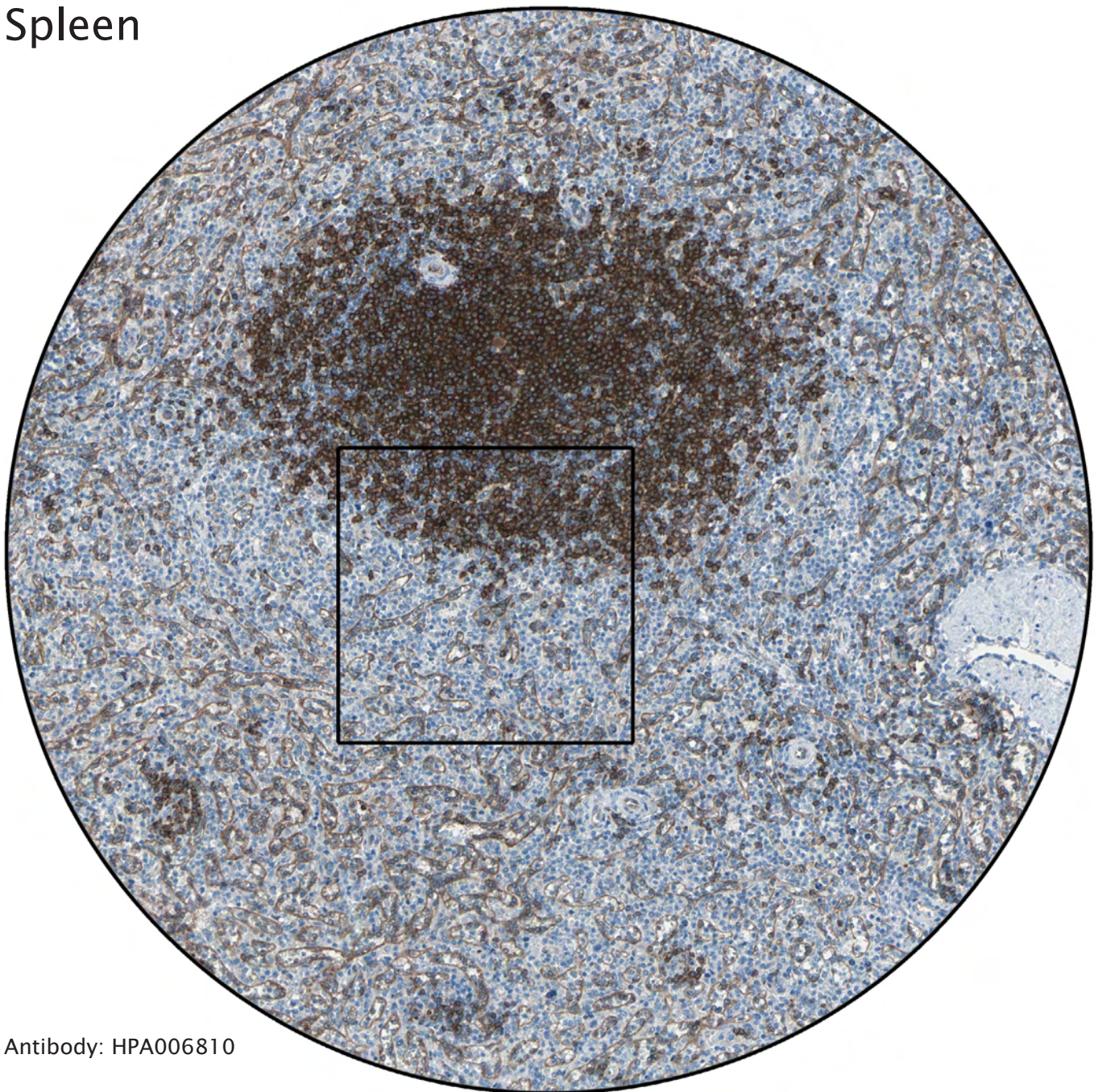
Reaction center cells

Mantle zone

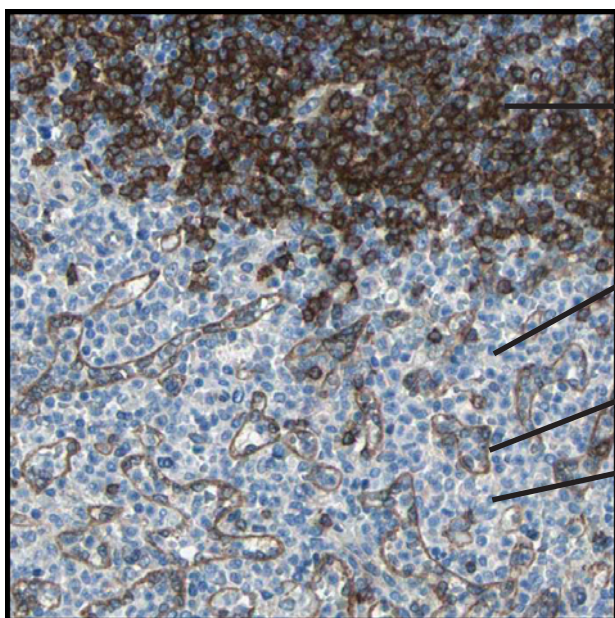
Antibody: CAB004498

Lymphoid cells outside reaction centra

Spleen



Antibody: HPA006810



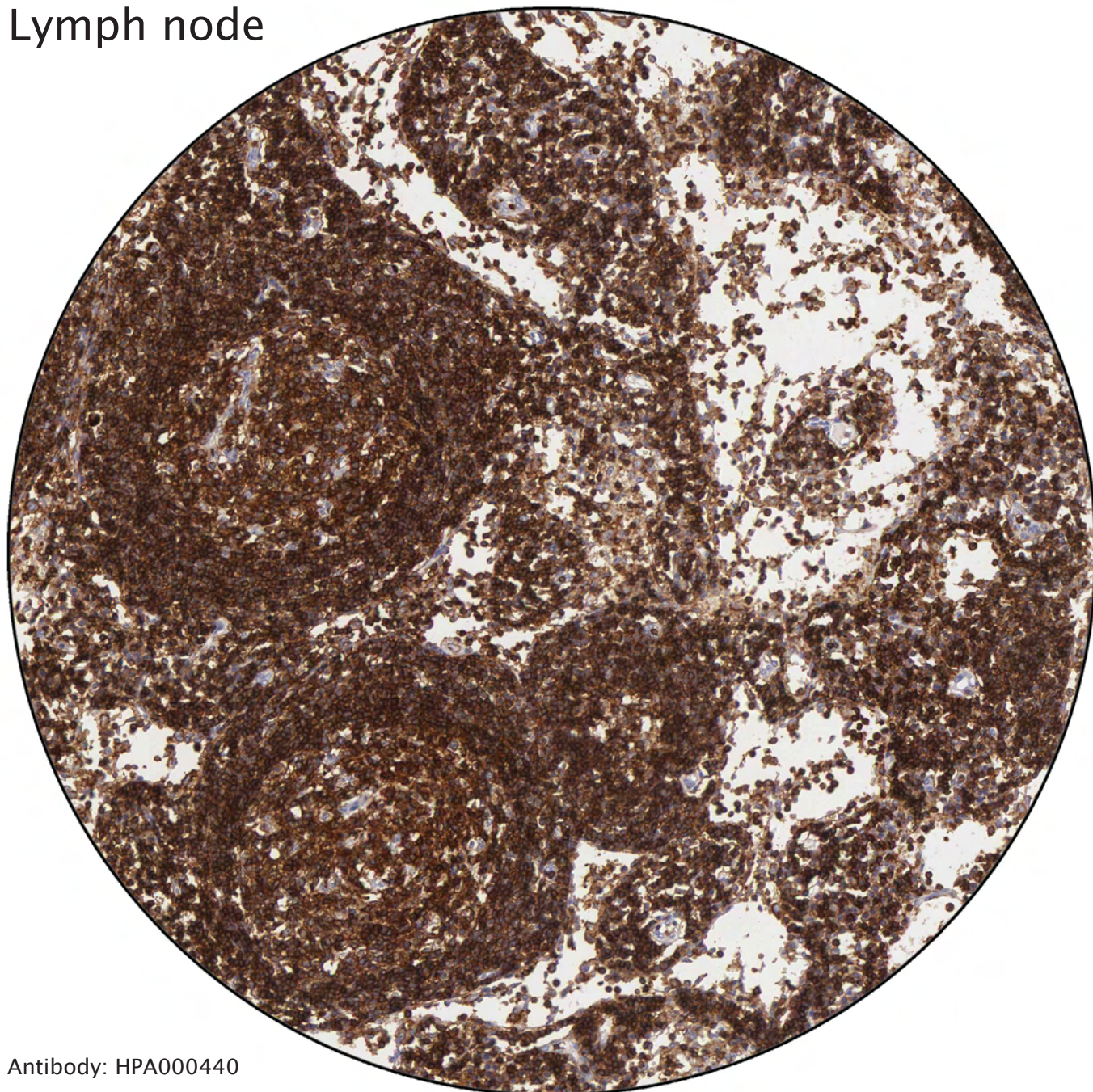
Strong staining of white pulp, composed of lymphoid tissue.

Red pulp, which is composed of sinusoids and splenic cords.

Sinusoids weakly stained.

Splenic cords are composed of a network of reticular fibers and also contain macrophages and plasma cells.

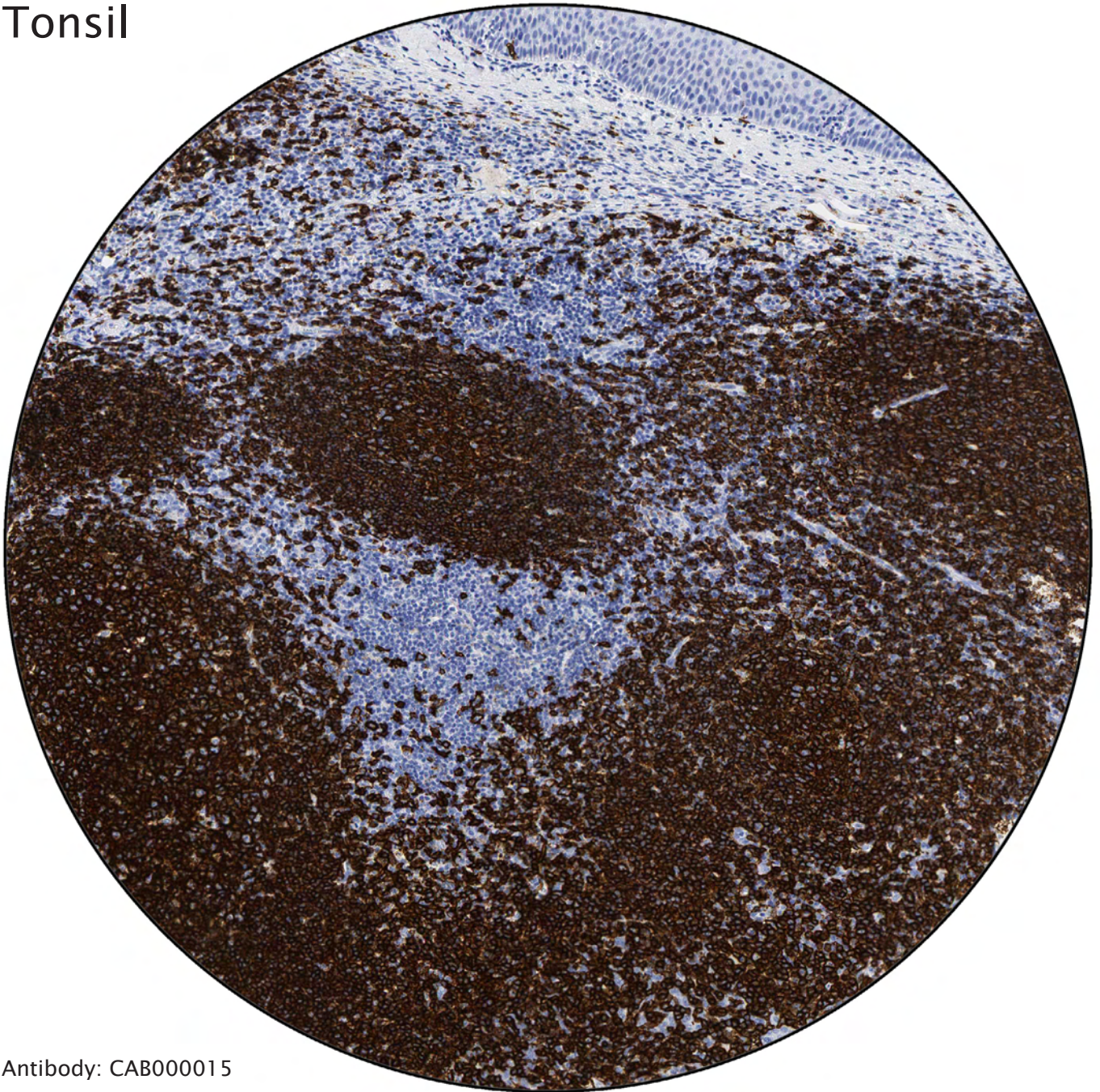Lymph node



Antibody: HPA000440

Cells of hematopoietic origin stained with
a general marker for leukocytes.

Tonsil

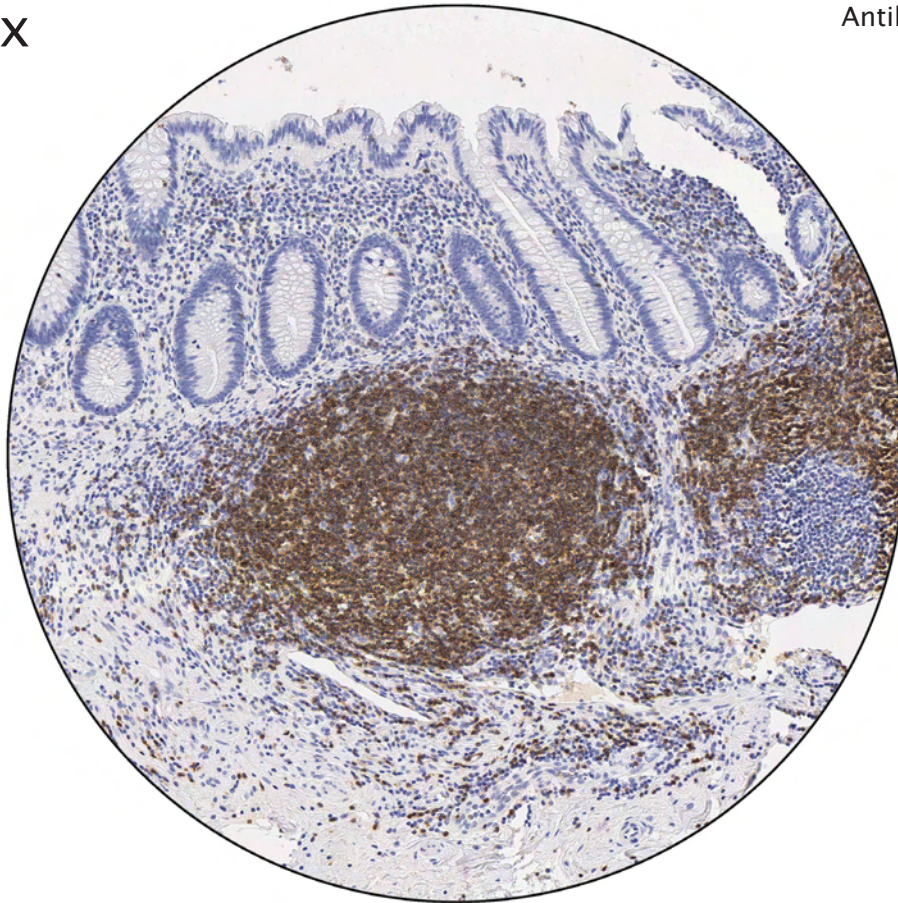

Antibody: CAB000015

The strongly stained cells are B-lymphocytes.

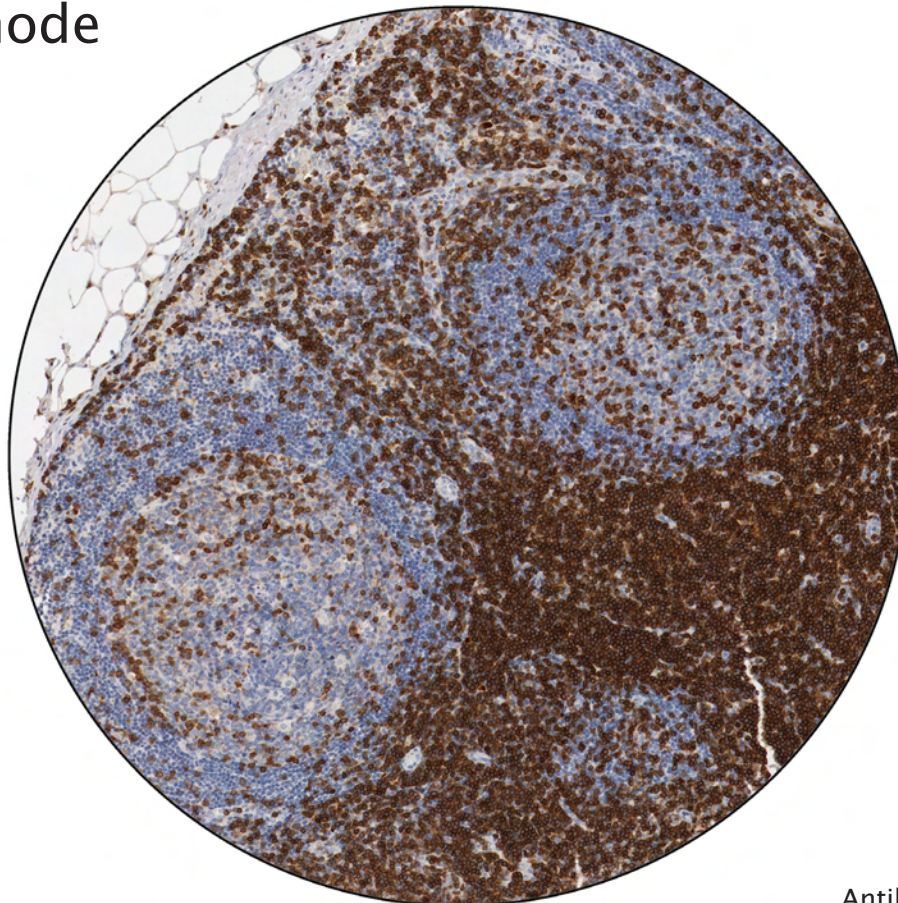
Appendix

Antibody: CAB000010



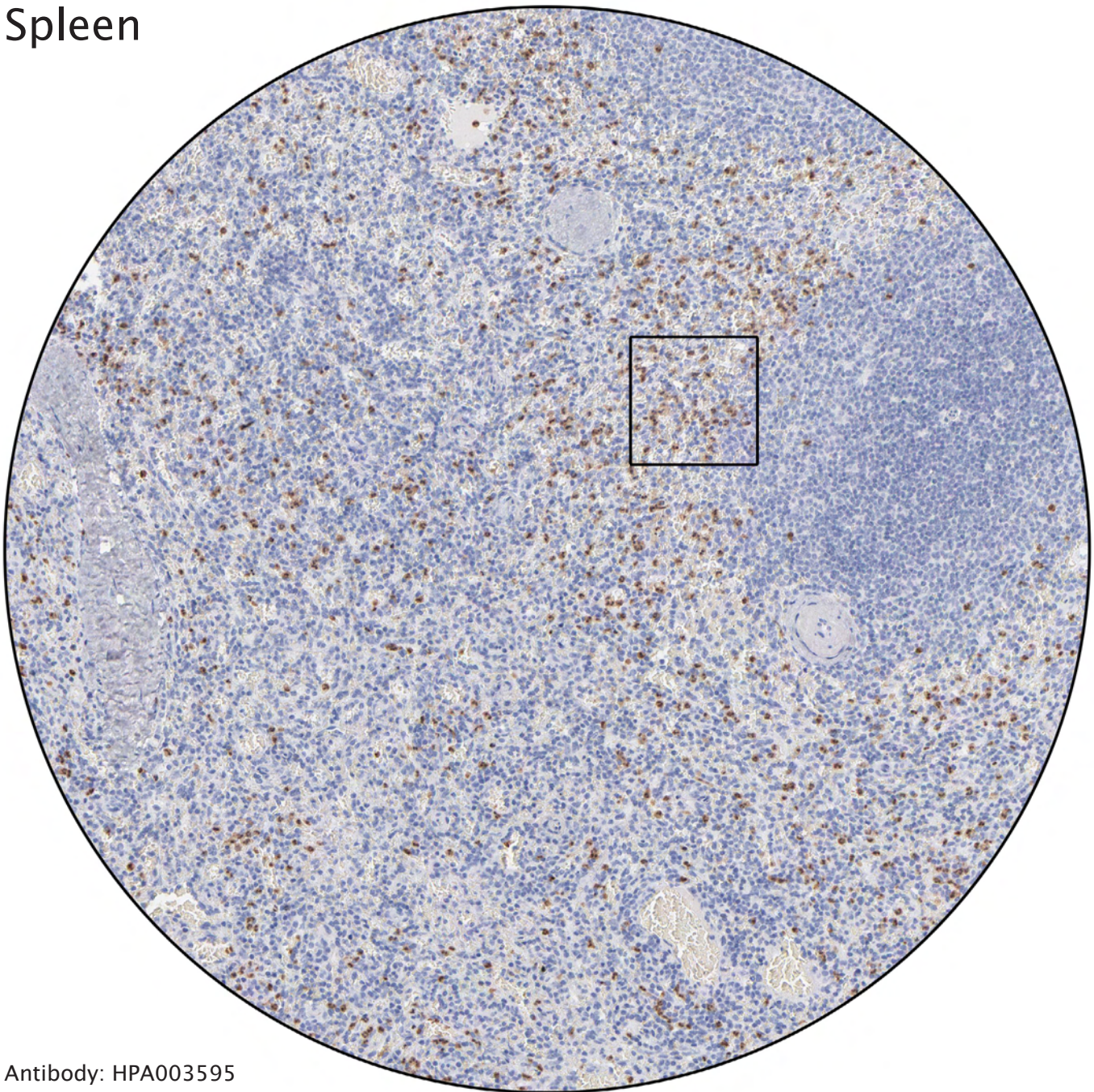
Distinct positivity of T-lymphocytes. In appendix, lymphoid plaques mainly consist of T-lymphocytes.

Lymph node

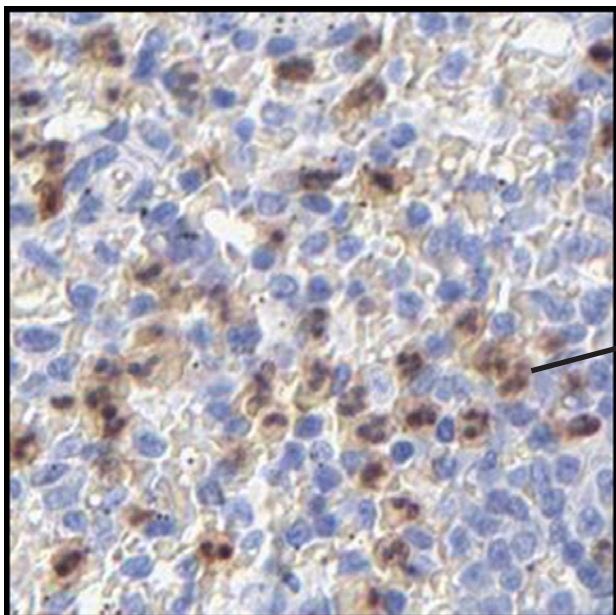


Antibody: CAB004651

Spleen

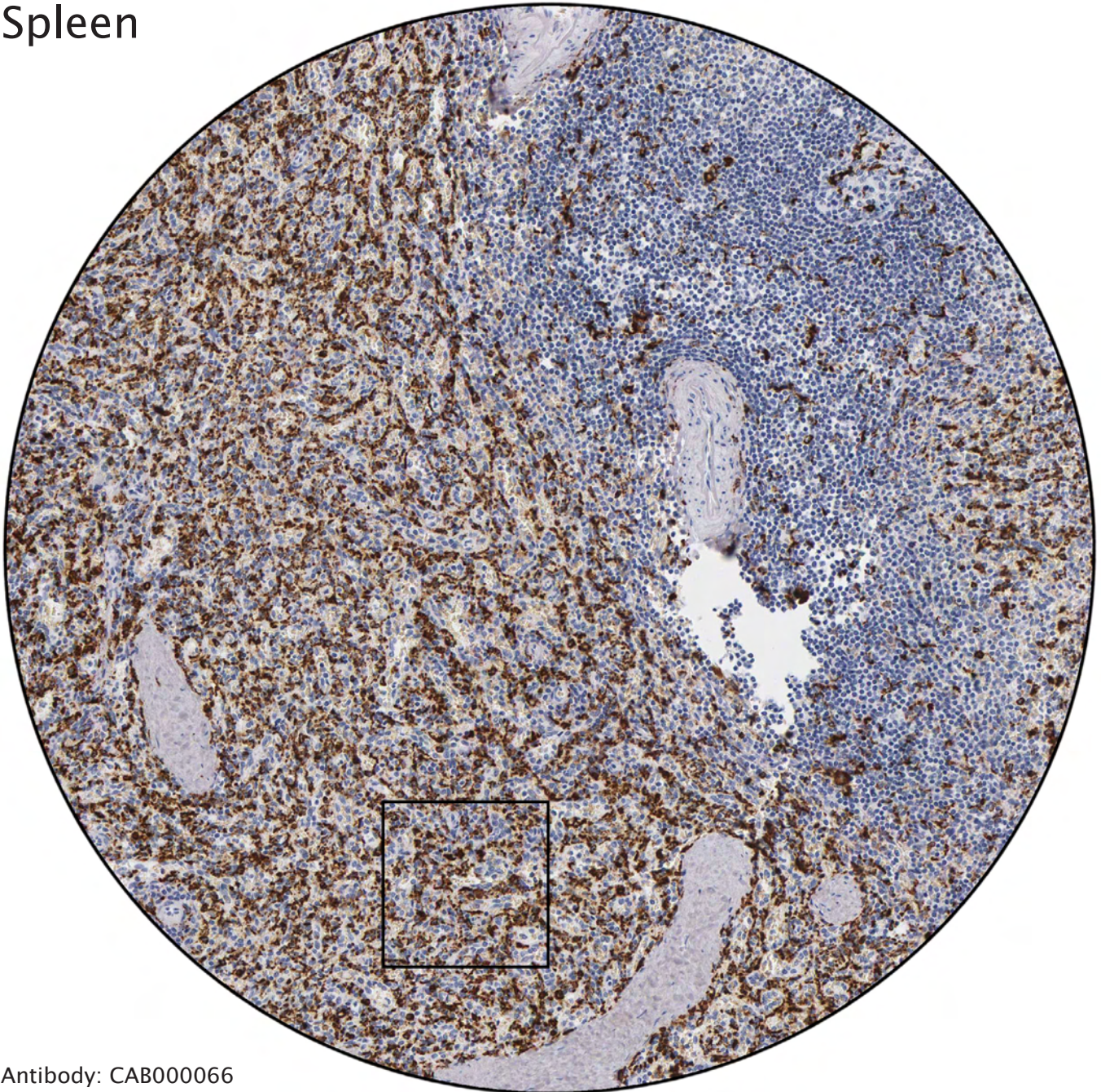


Antibody: HPA003595

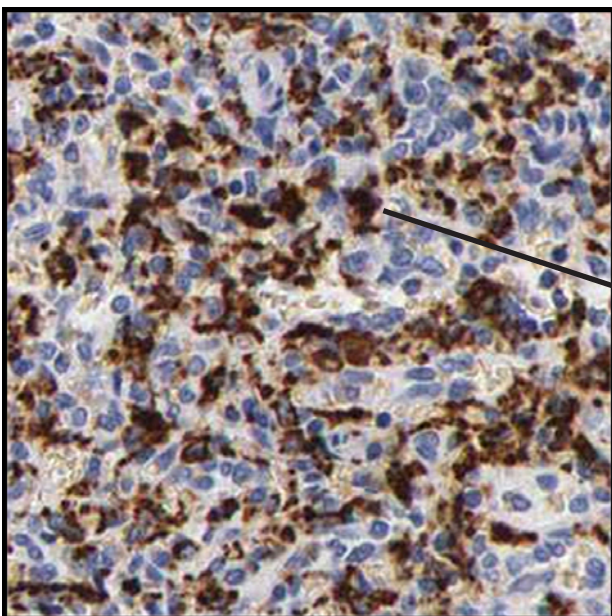


The distinctly stained cells are granulocytes, which have multi-lobulated nuclei.

Spleen

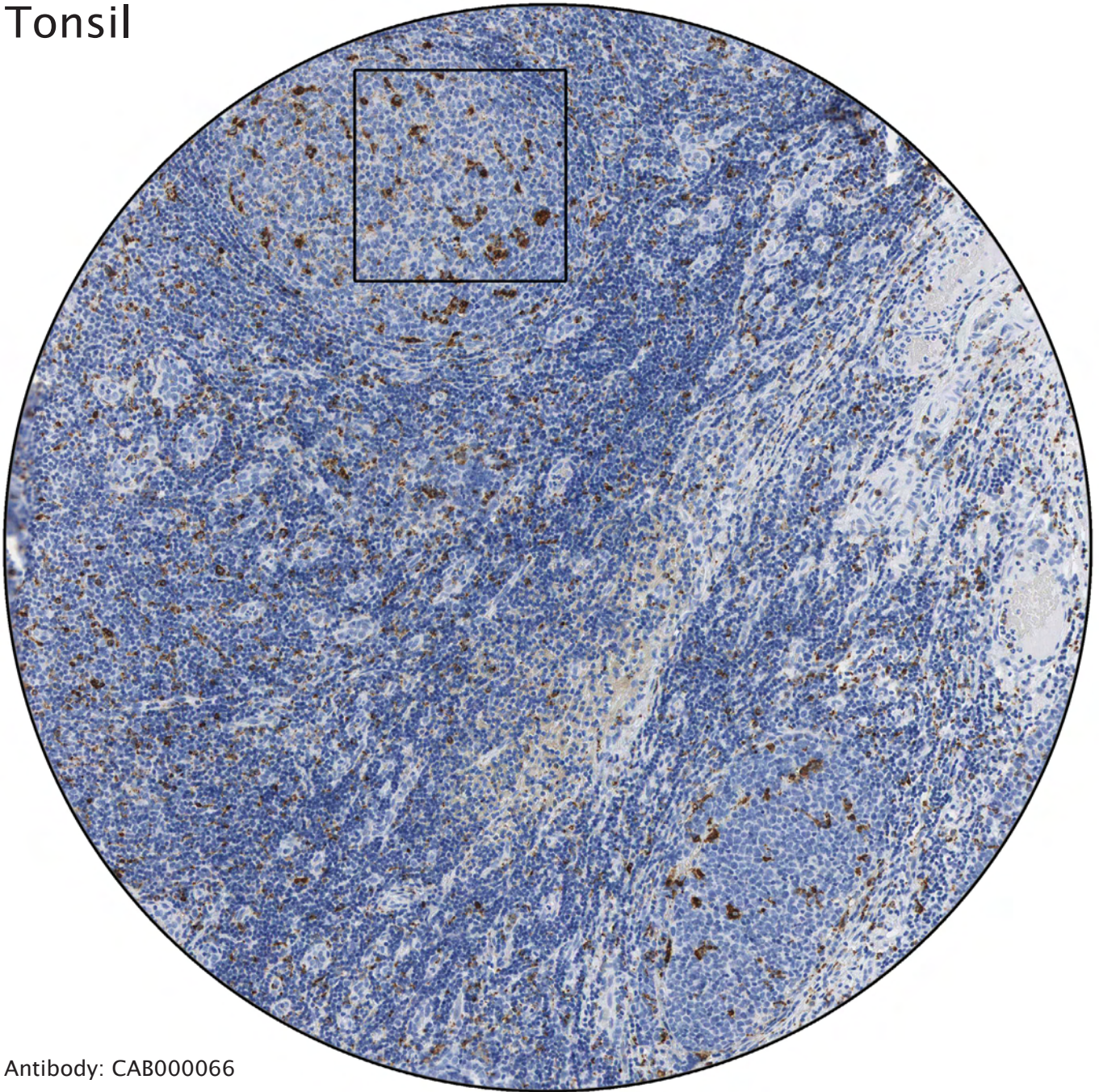


Antibody: CAB000066

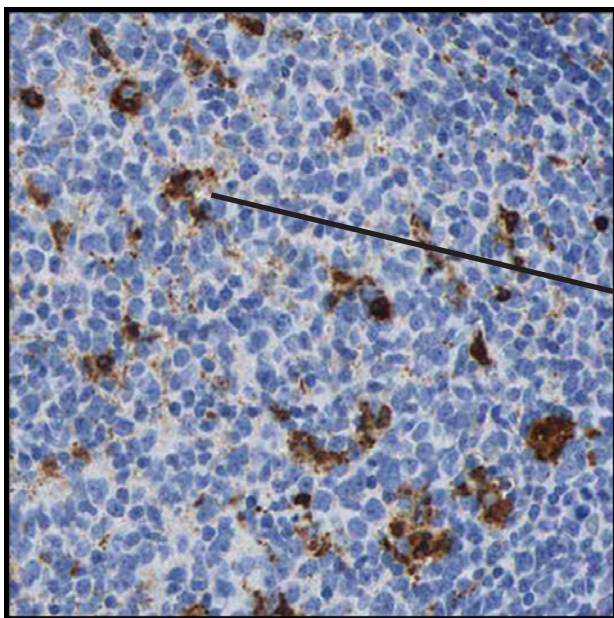


Strong positivity of histiocytes (macrophages), monocyte-derived cells localized in connective tissue.

Tonsil

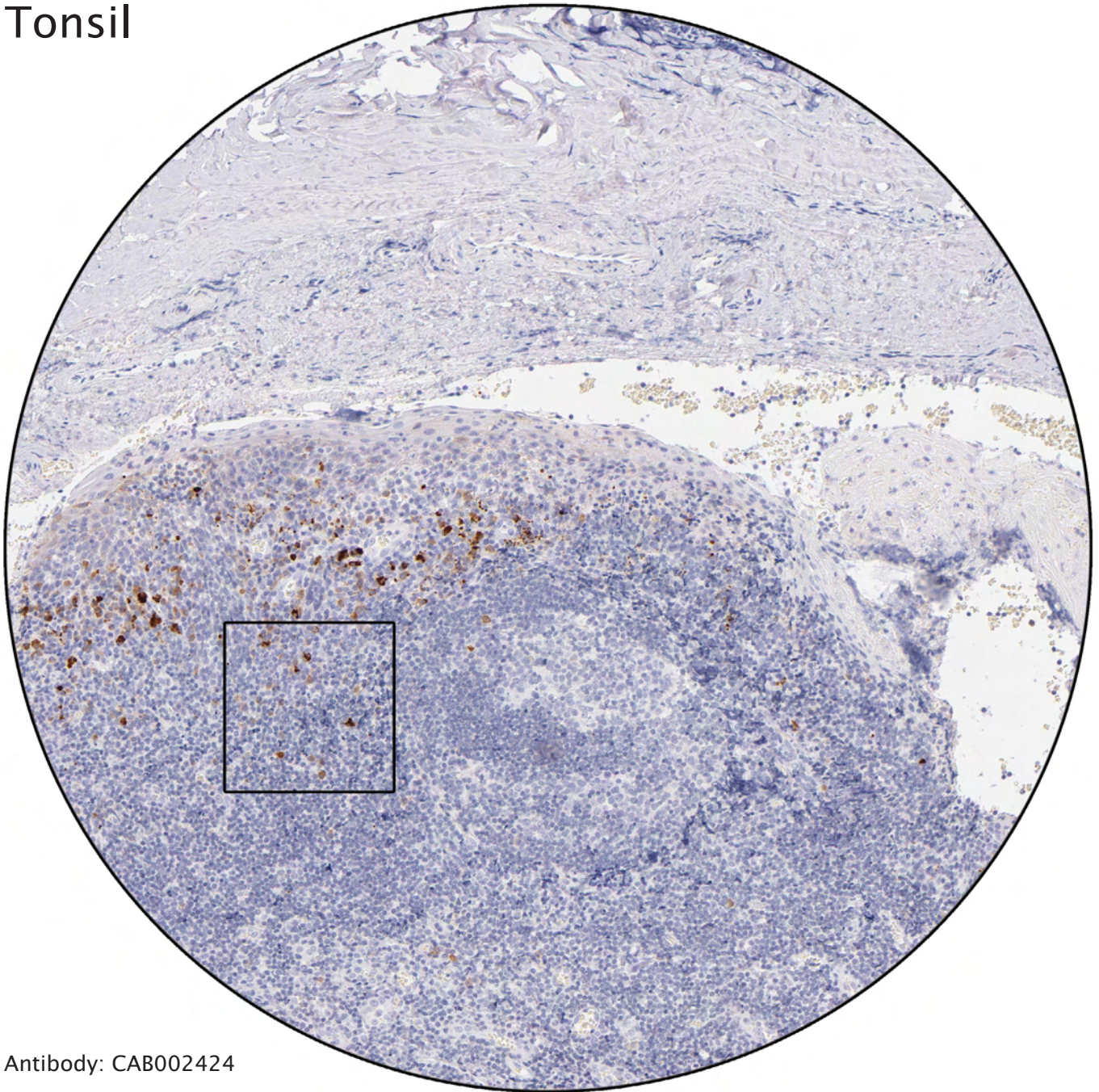


Antibody: CAB000066

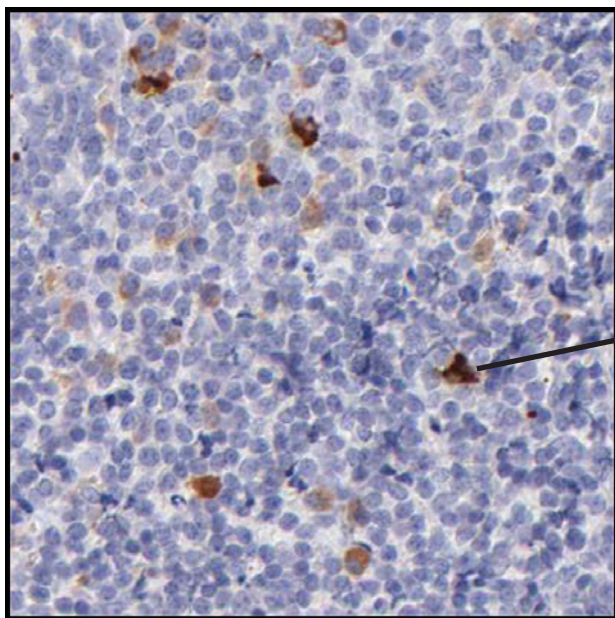


Distinct immunoreactivity of macrophages.

Tonsil

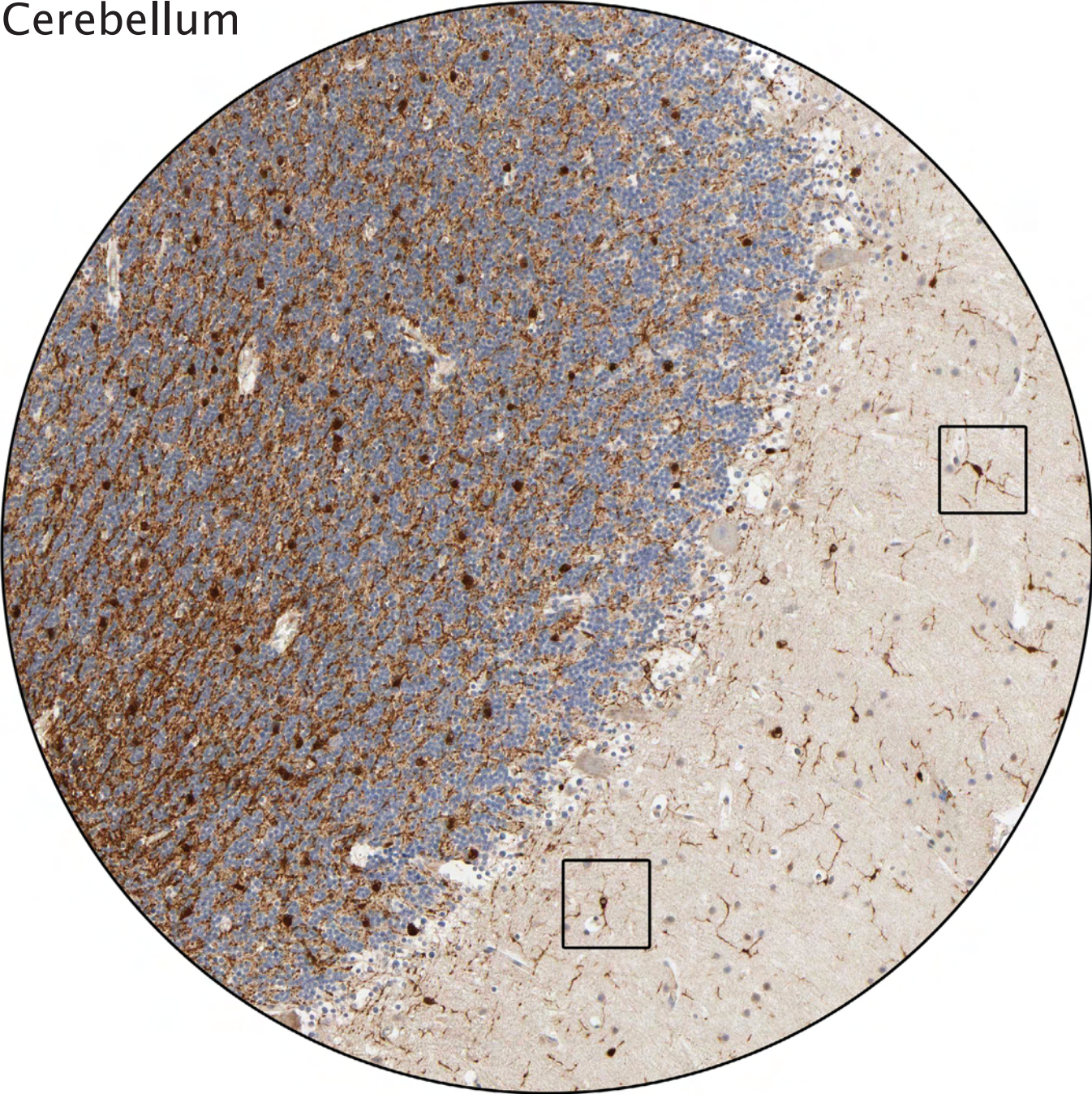


Antibody: CAB002424



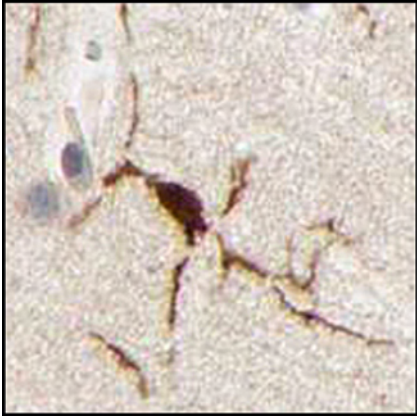
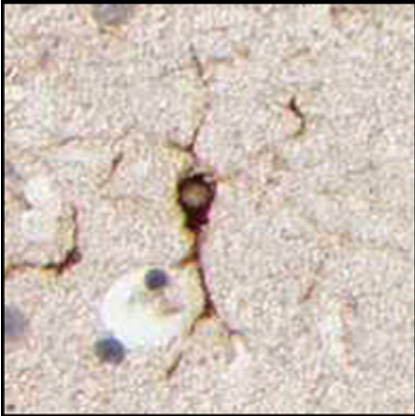Strong staining of plasma cells.

Cerebellum



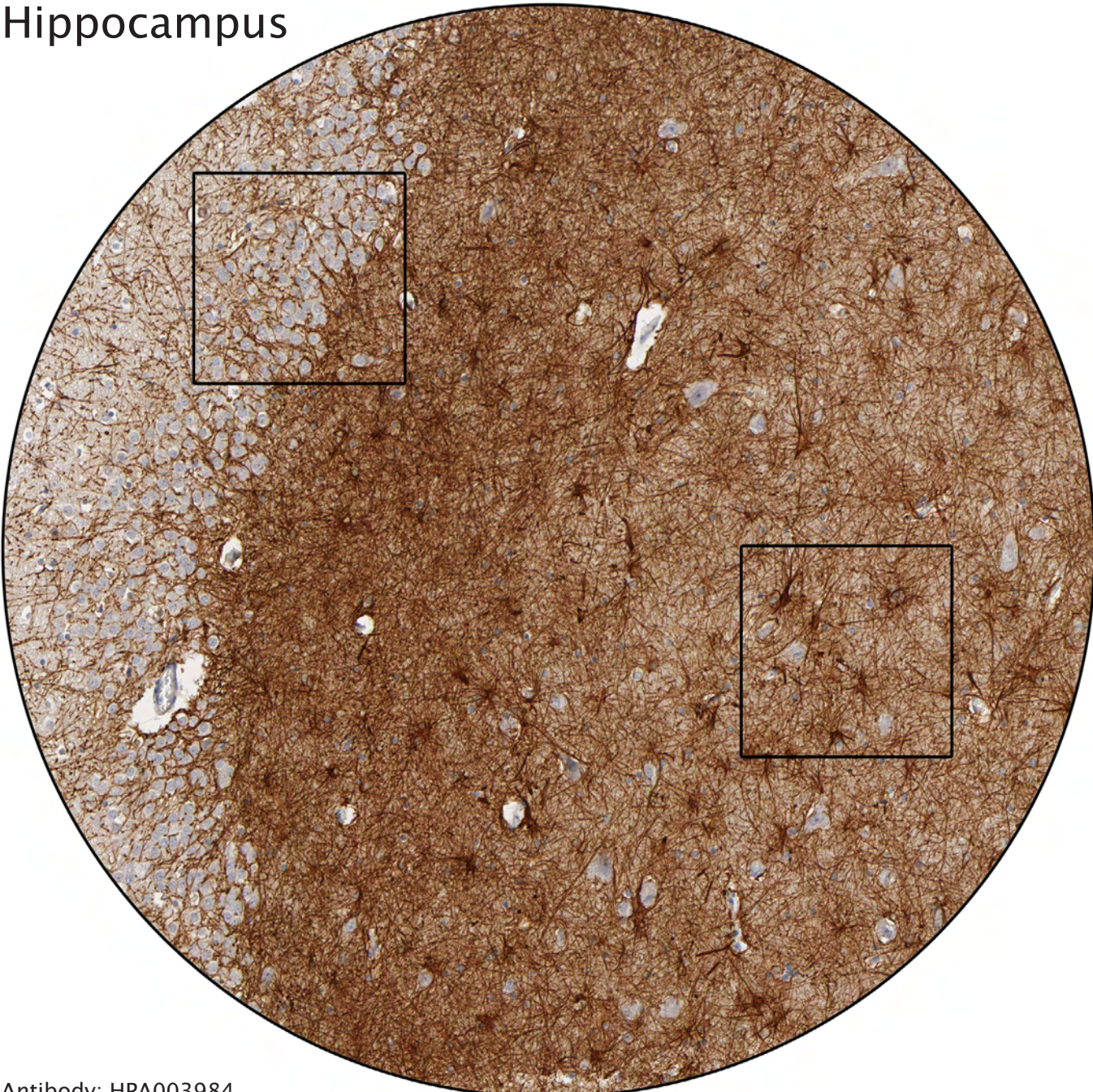
Antibody: HPA003894

Astrocytes



----- Different celltypes and intracellular structures -----

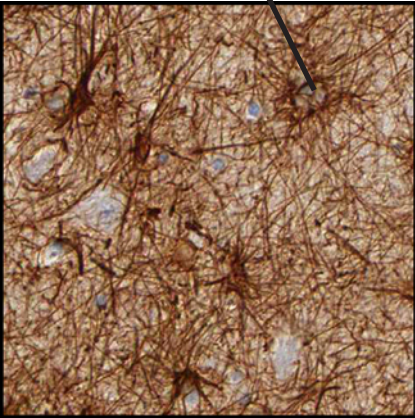
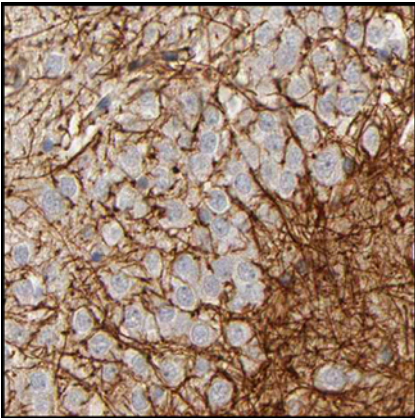
Hippocampus



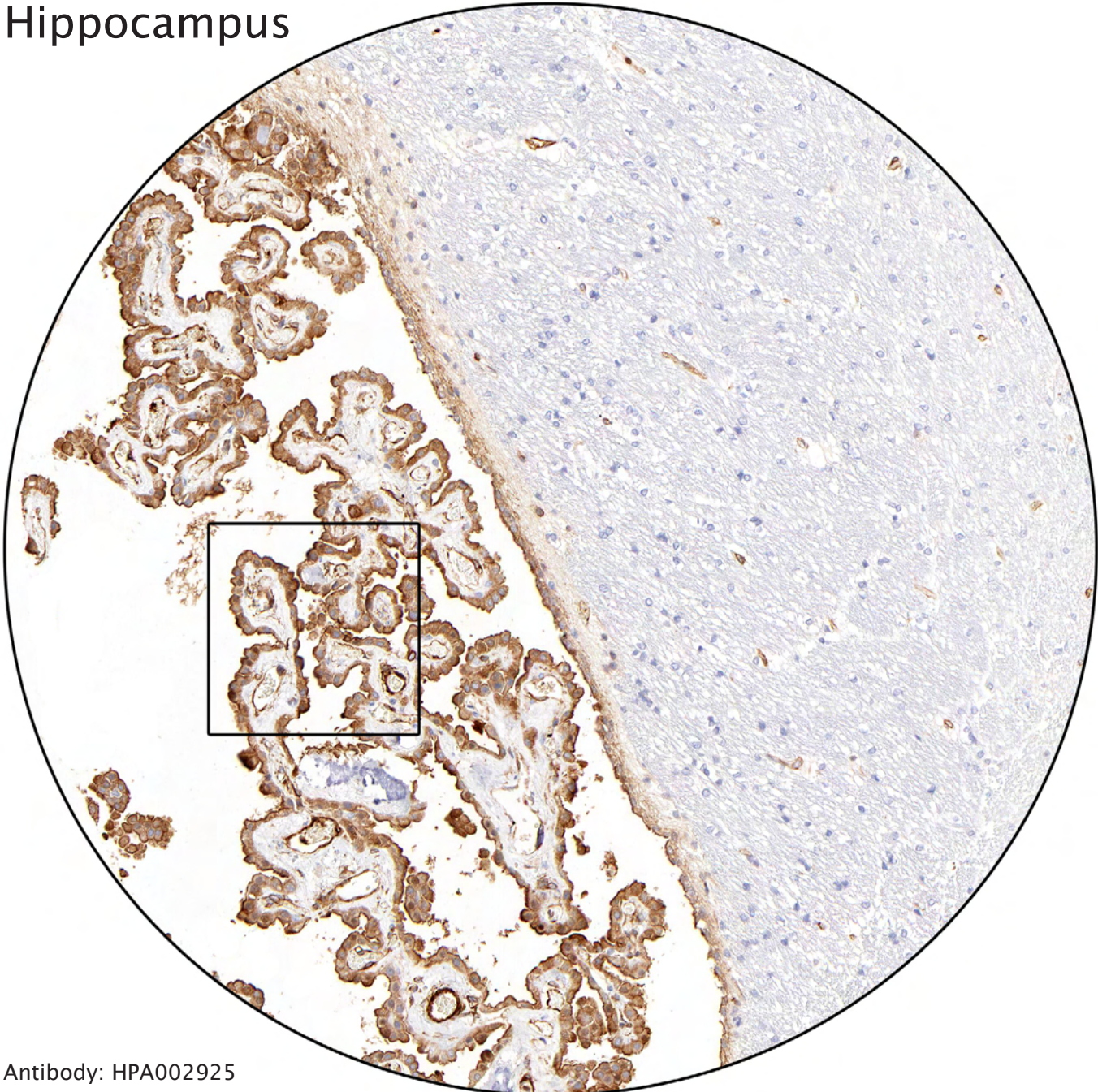
Antibody: HPA003984

Gyrus dentatus. A region for production of new nerve cells.

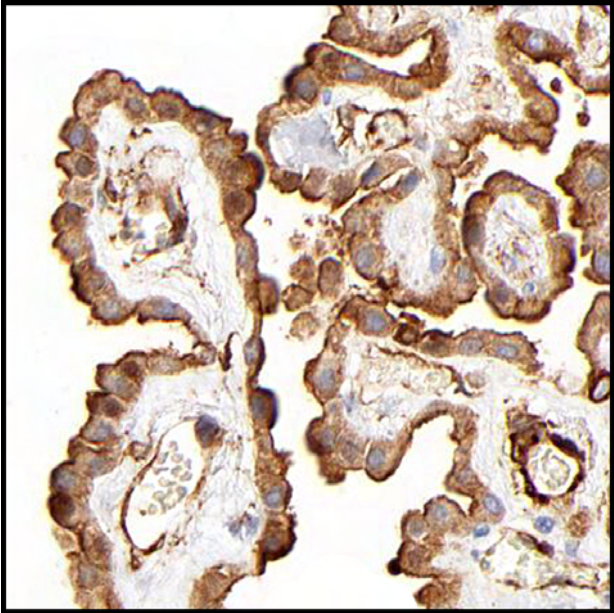
Astrocytes



Hippocampus

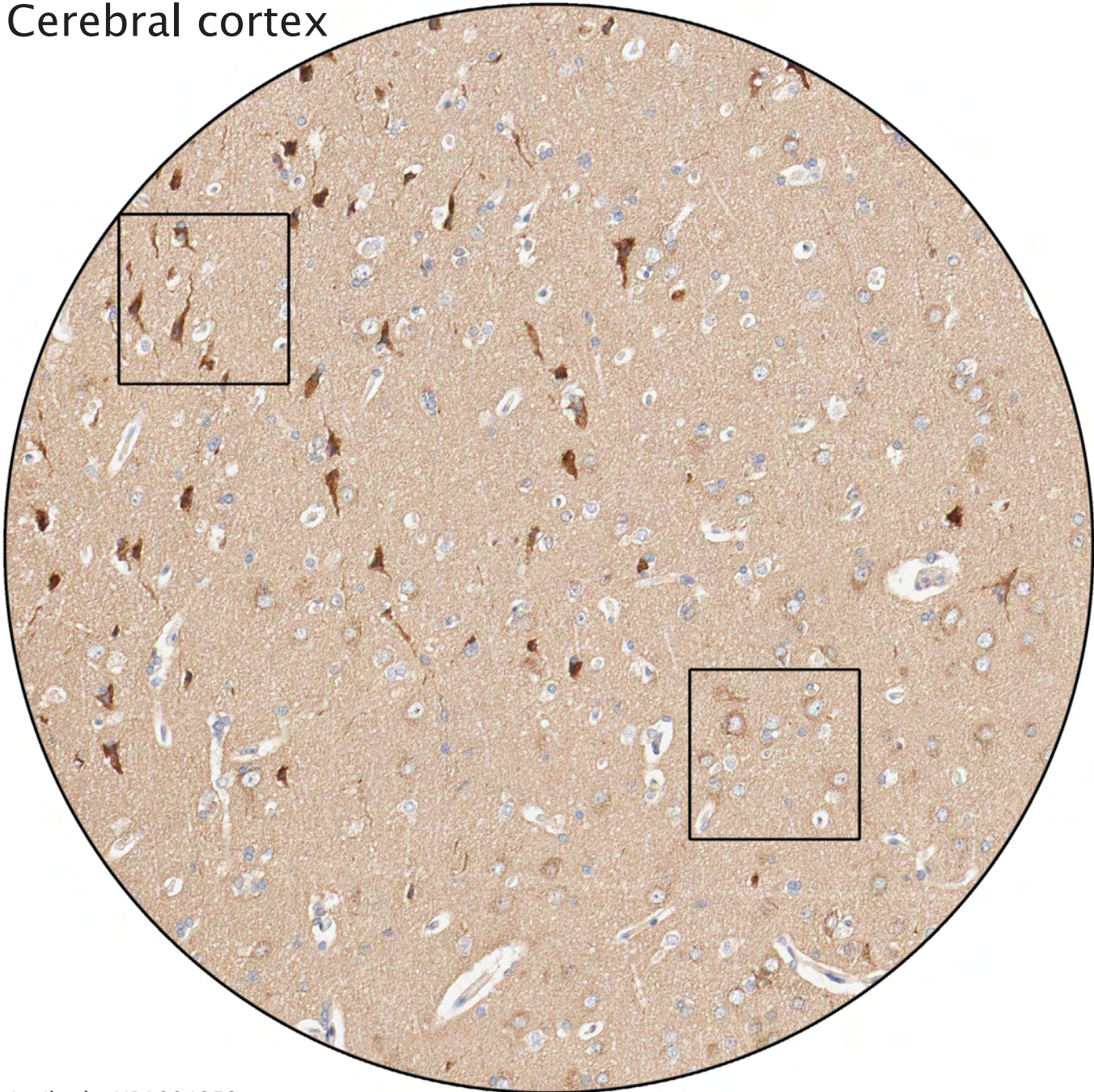


Antibody: HPA002925



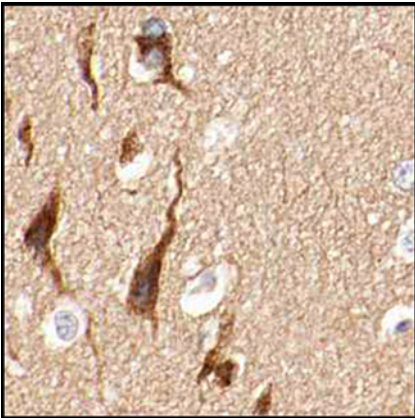
Plexus choroideus, a papillary tissue in the lateral ventricles which produces cerebrospinal fluid.

Cerebral cortex

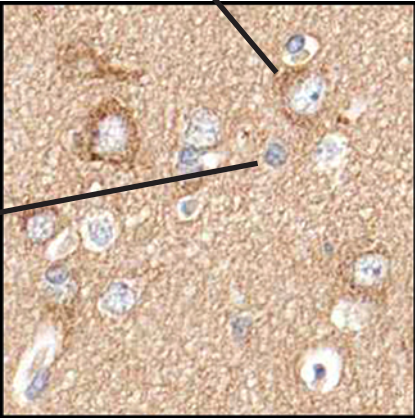


Antibody: HPA004059

Pyramidal neuronal cells strongly stained.

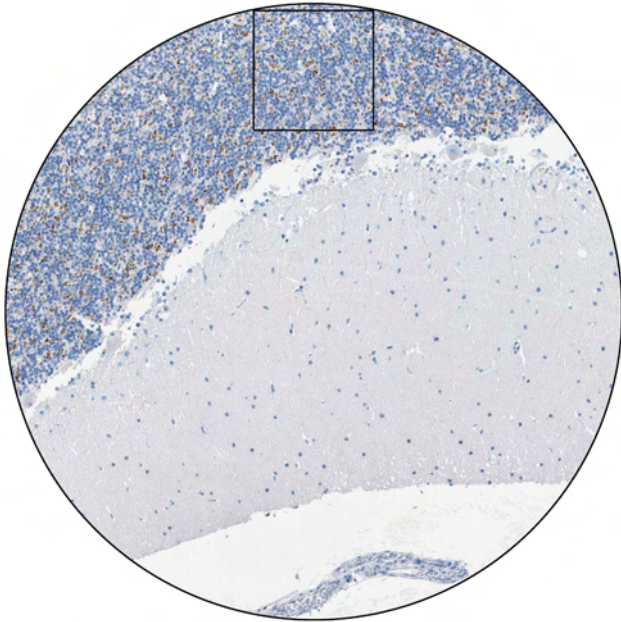


Motor neurons weakly positive.



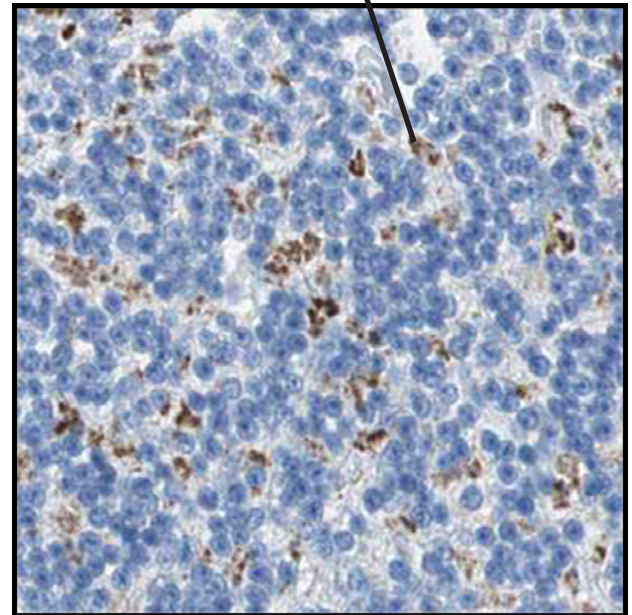
Glial cells negative.

Cerebellum




Antibody: HPA007179

Distinct dotlike positivity in granular layer. Probably staining of axons or synapses, possibly from Golgi cells.

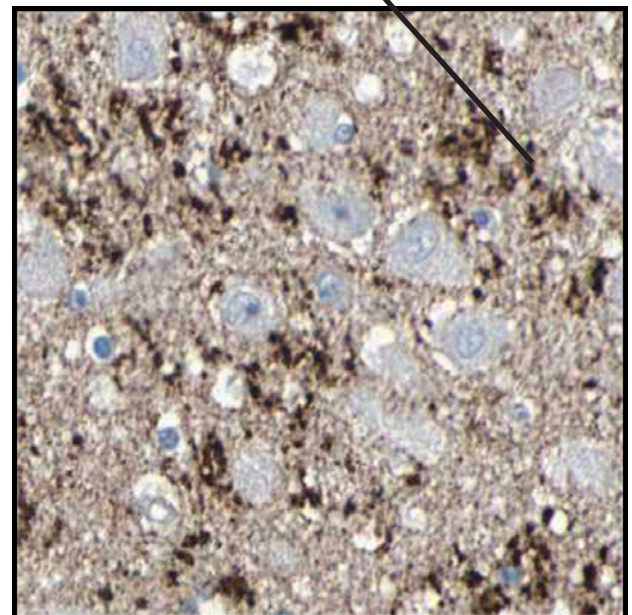


Hippocampus

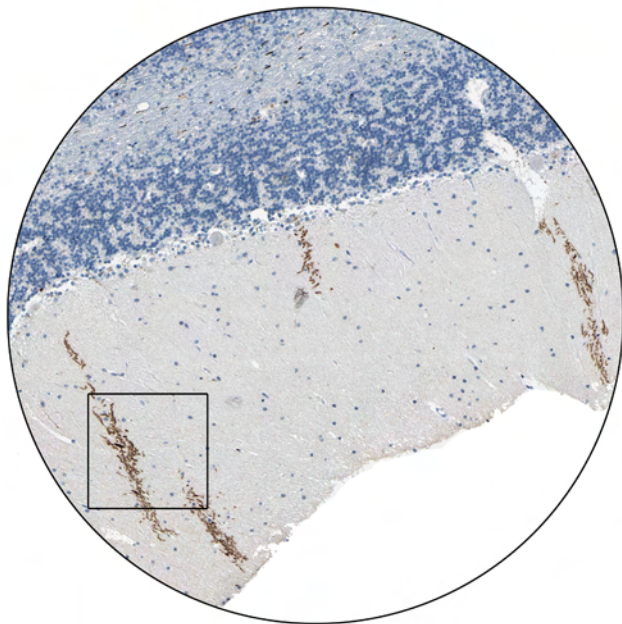


Antibody: HPA006766

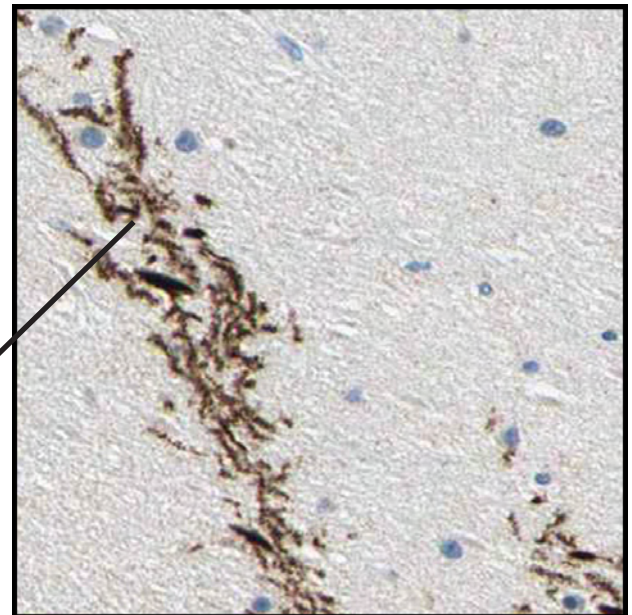Similar staining pattern in hippocampus.



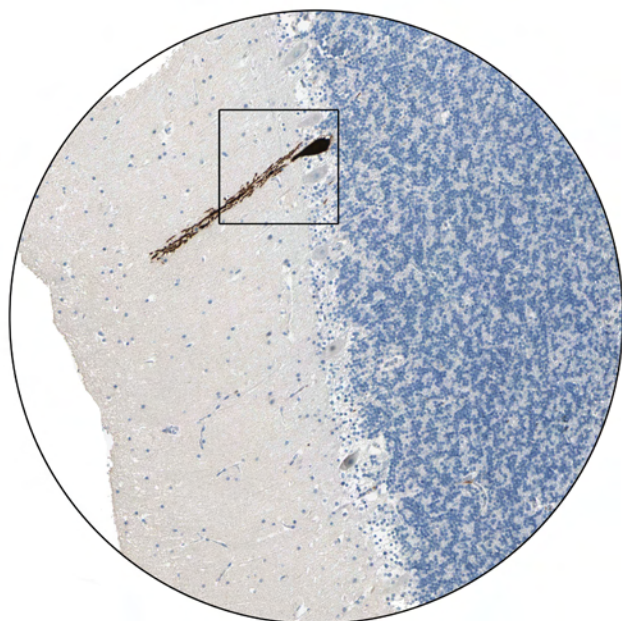
Cerebellum



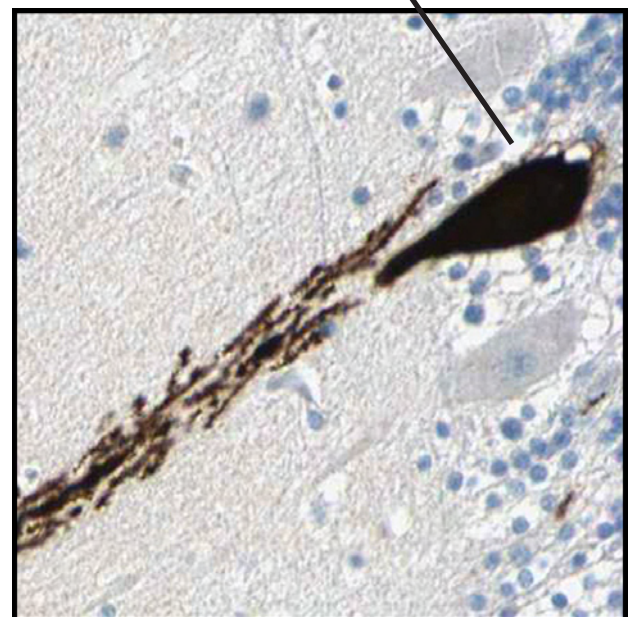Antibody: HPA005662



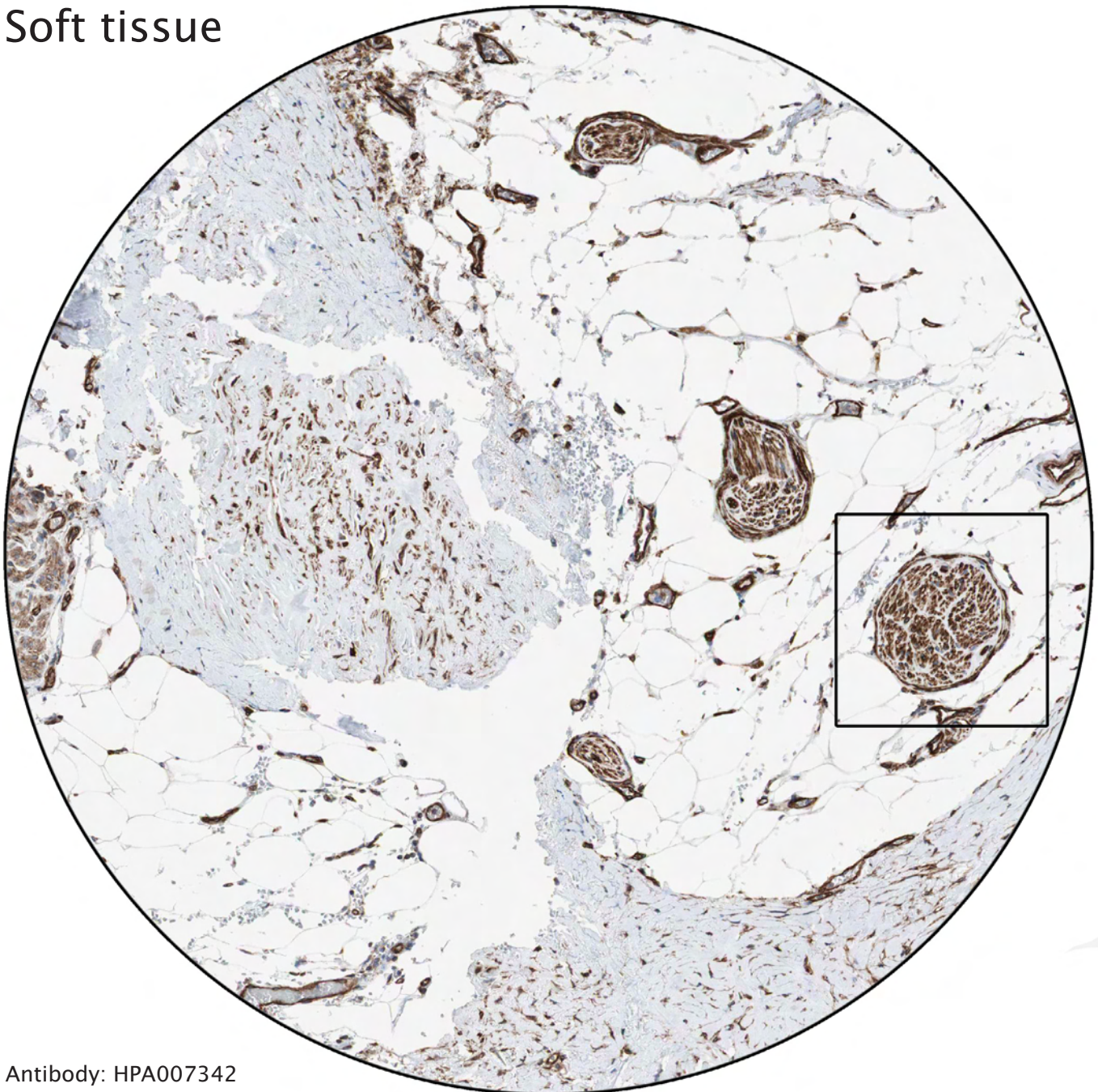
Strong staining of a specific subtype of nerve fiber.



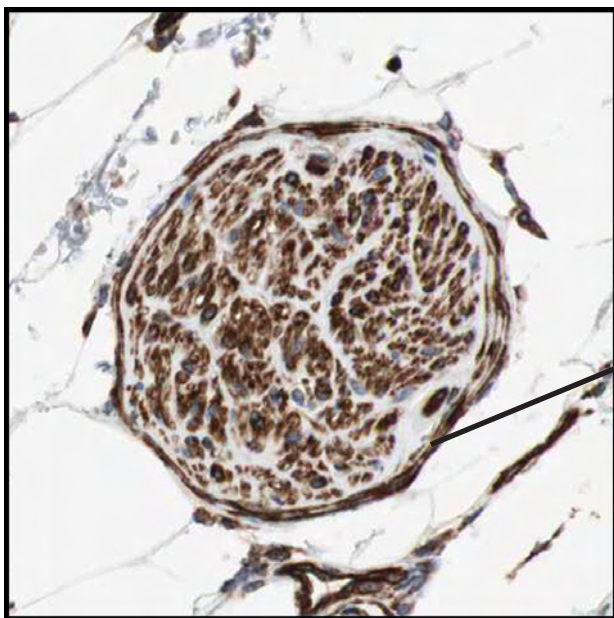
One Purkinje cell is also distinctly positive.



Soft tissue

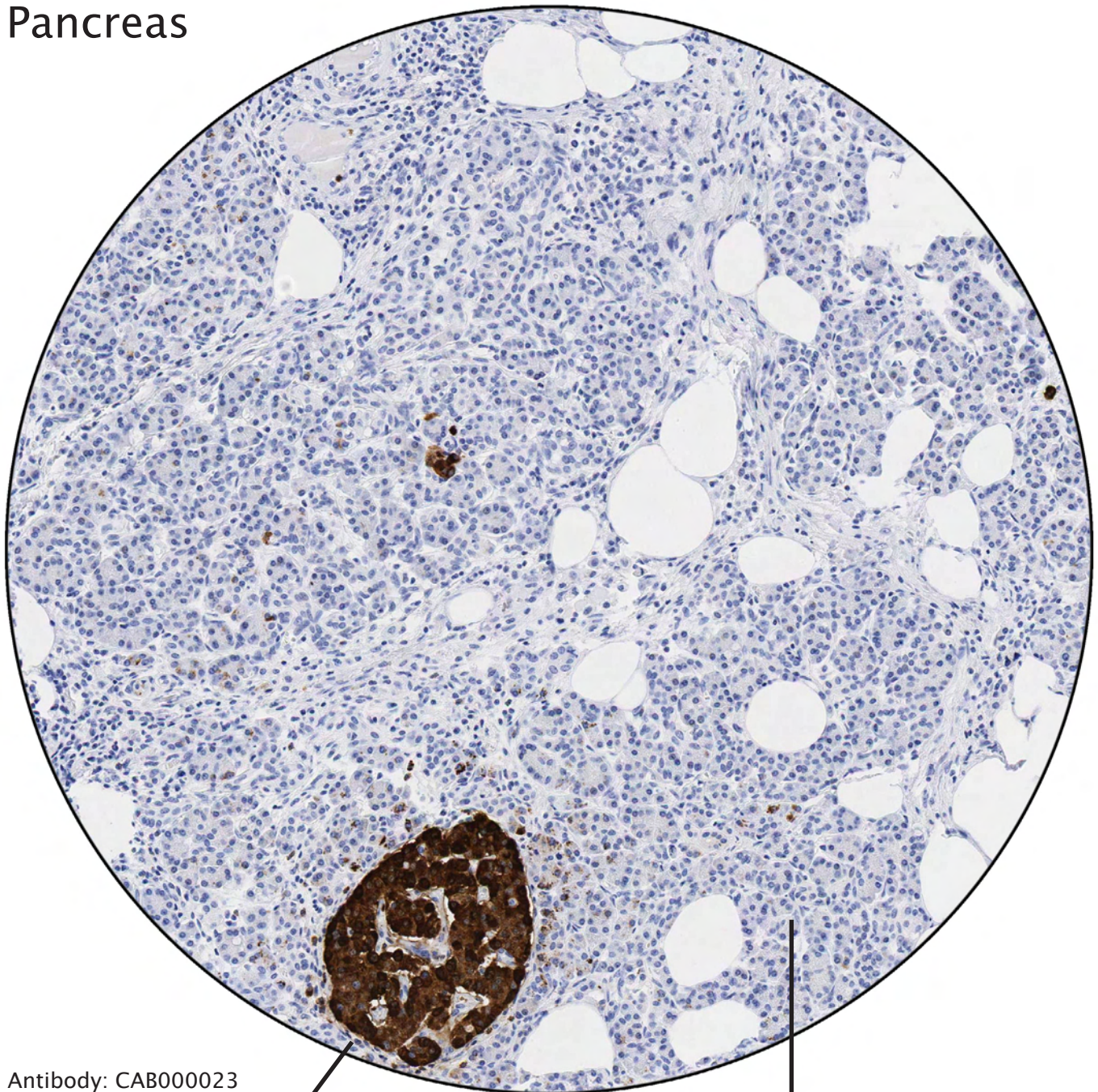


Antibody: HPA007342



Distinct staining of perineurium, the connective tissue surrounding bundles of nerve fibers.

Pancreas

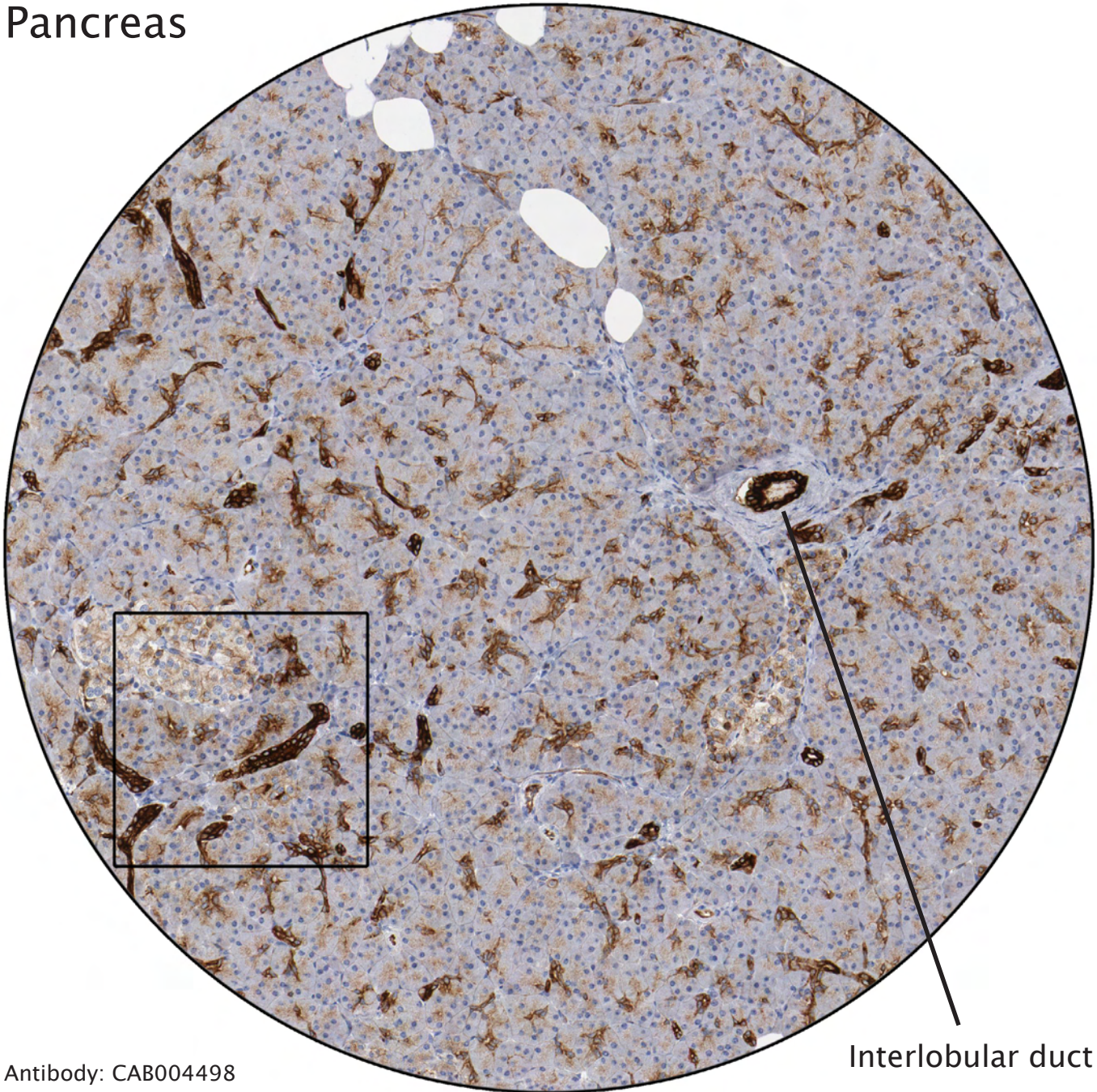


Antibody: CAB000023

Strong staining of a Langerhans islet. The four different types of endocrine cells produce the hormones: insuline, glucagon, somatostatin and pancreatic polypeptide.

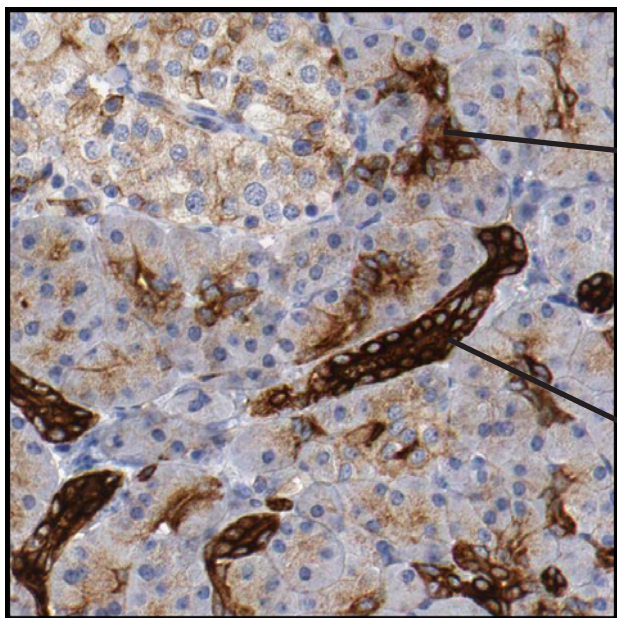
Exocrine pancreas is negative. The exocrine glands produce and secrete digestive enzymes and proenzymes.

Pancreas



Antibody: CAB004498

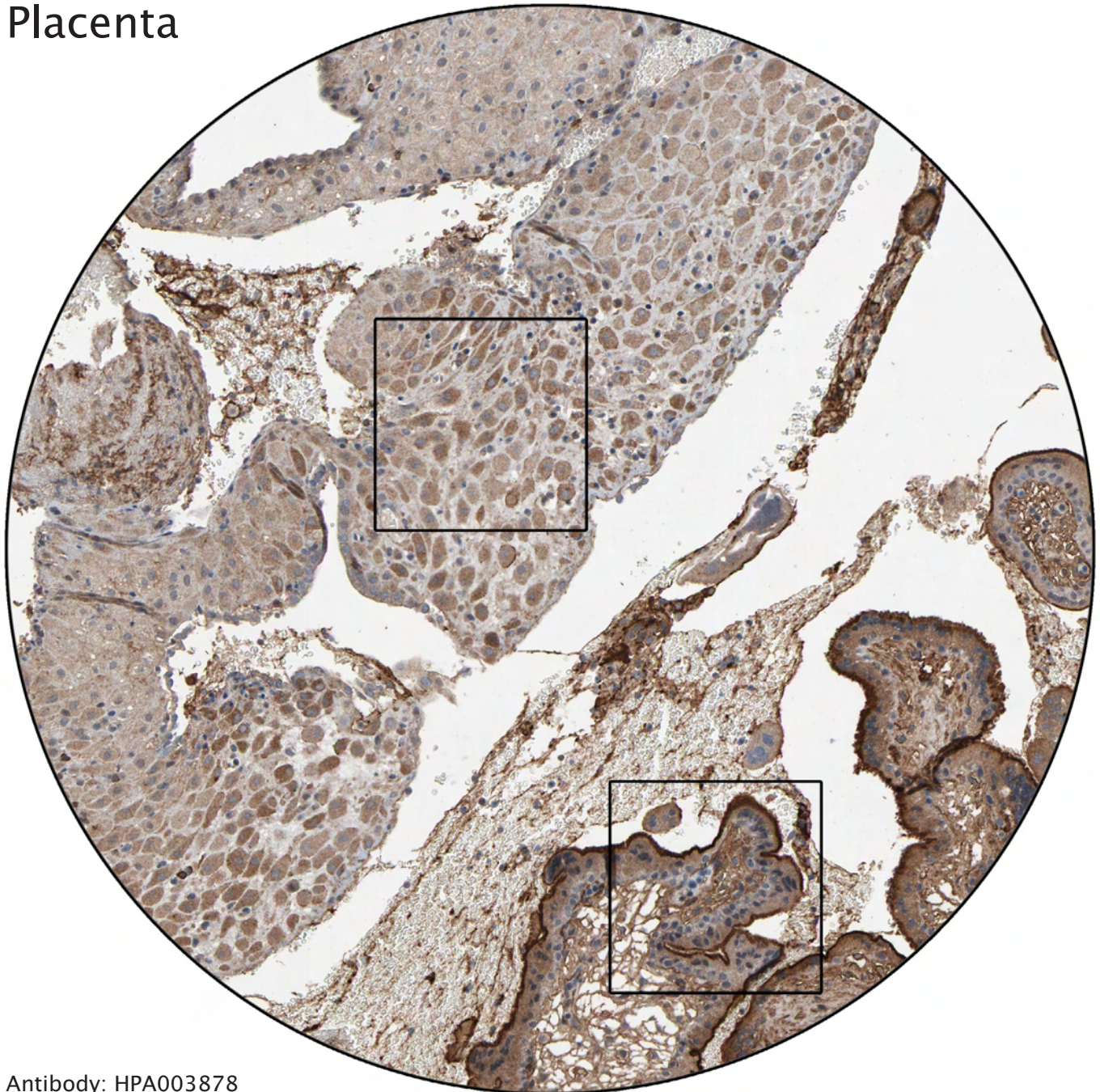
Interlobular duct



Distinct staining of intercalated ducts, surrounded by negative acini. The intercalated ducts merge to form larger intralobular ducts.

Strong positivity of an intralobular duct, which merges to form larger interlobular ducts. These in turn, merge to form the main pancreatic duct; Wirsung's duct.

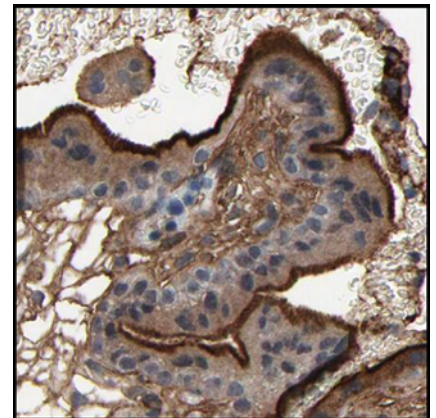
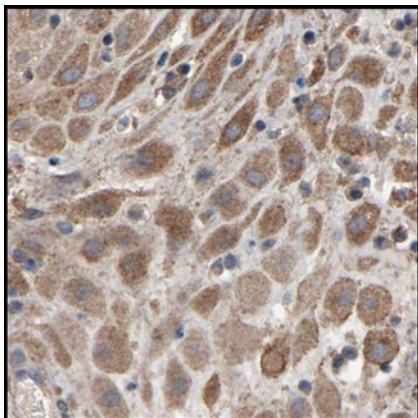
Placenta



Antibody: HPA003878

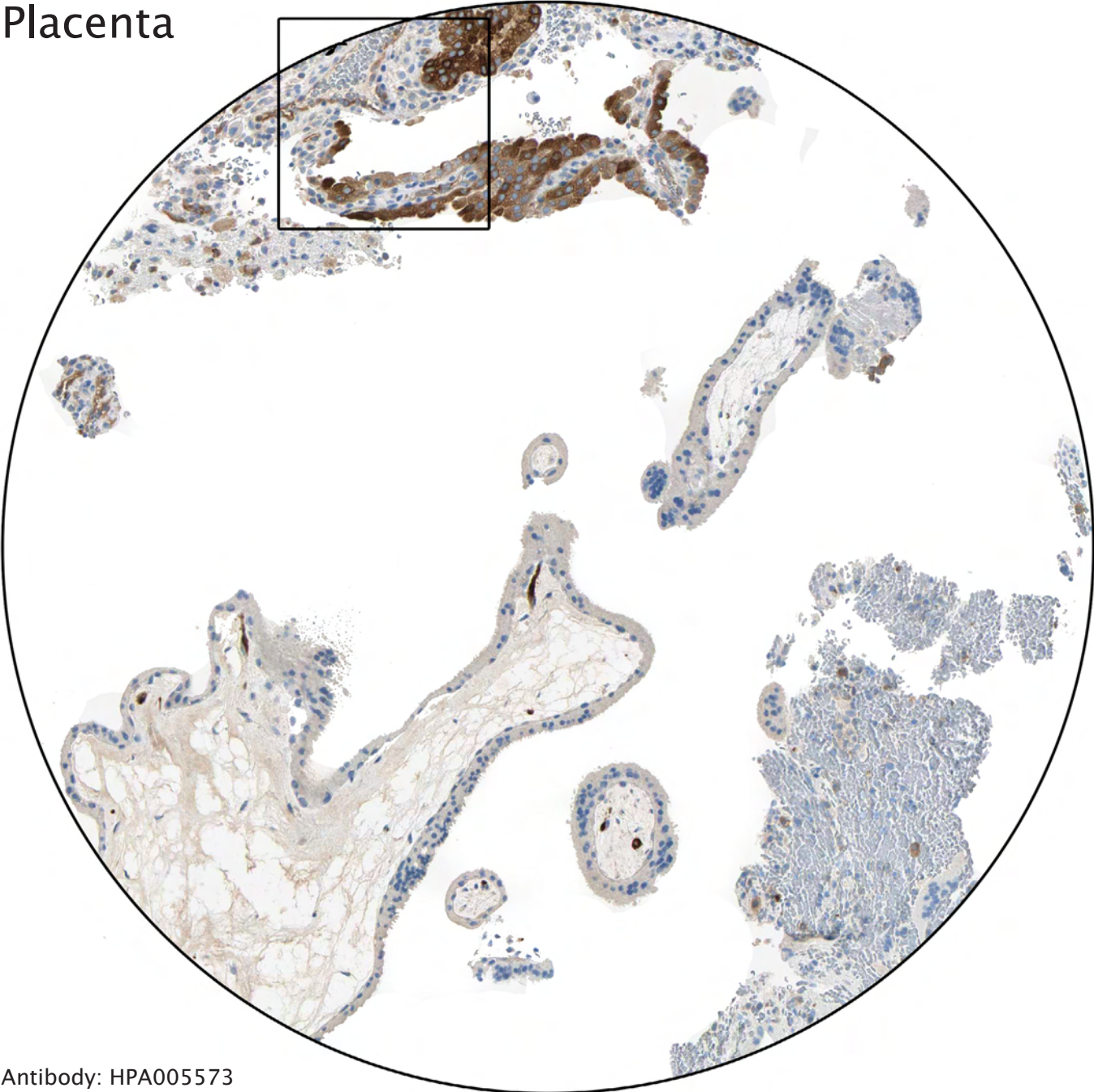
Moderate positivity of decidual cells, which are developed from smooth muscle when affected by hormones (pregnancy).

Distinct staining of microvilli in syncytiotrophoblasts. The cytotrophoblasts (inner cell layer) are weaker stained.

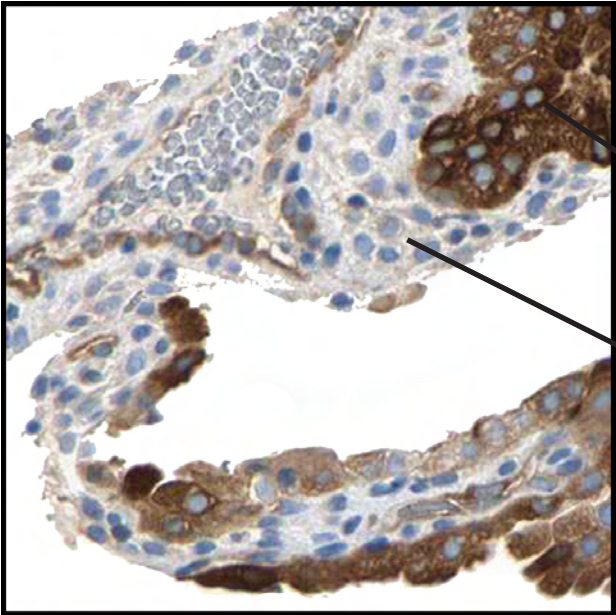


----- Different celltypes and intracellular structures -----

Placenta



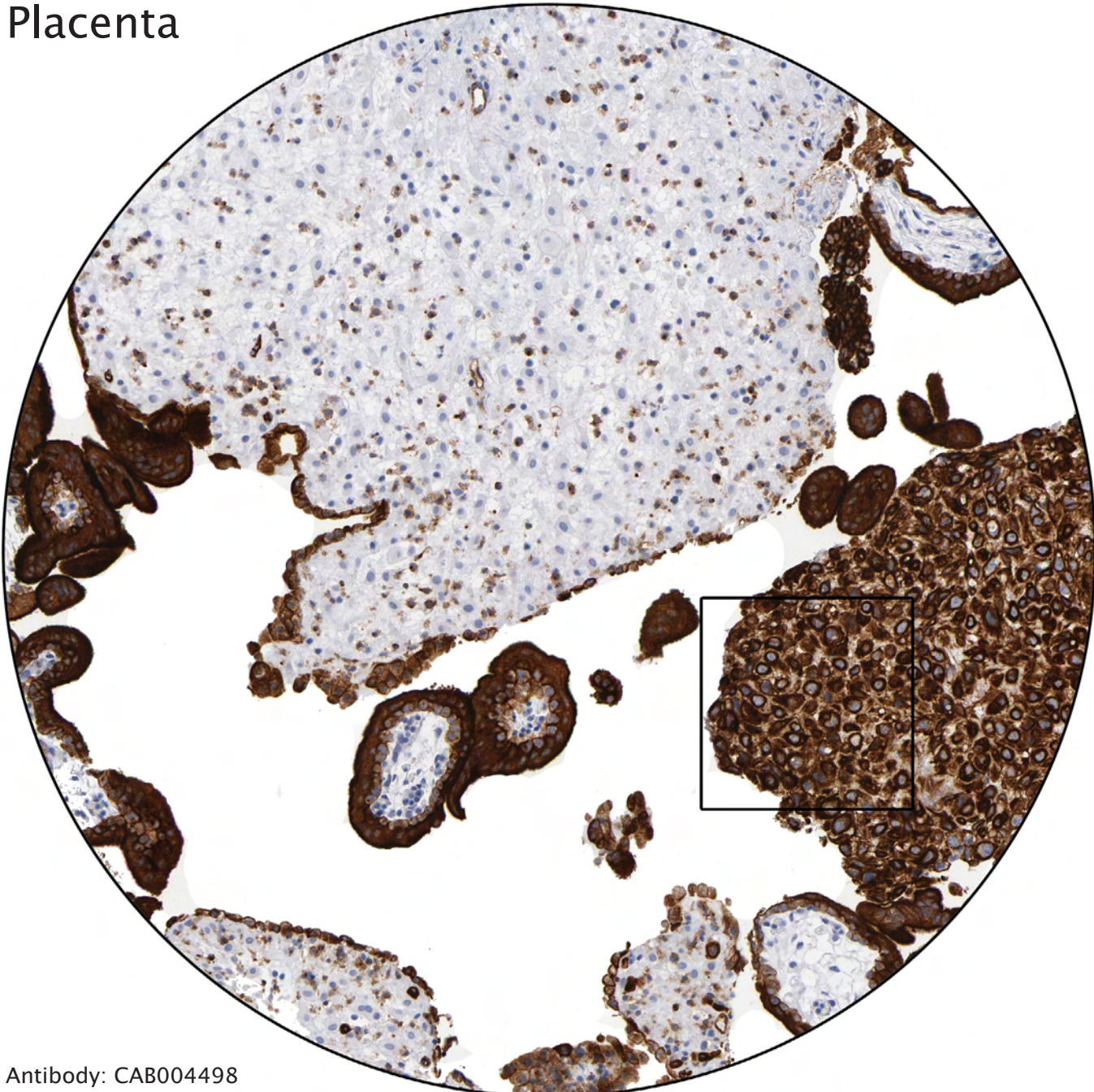
Antibody: HPA005573



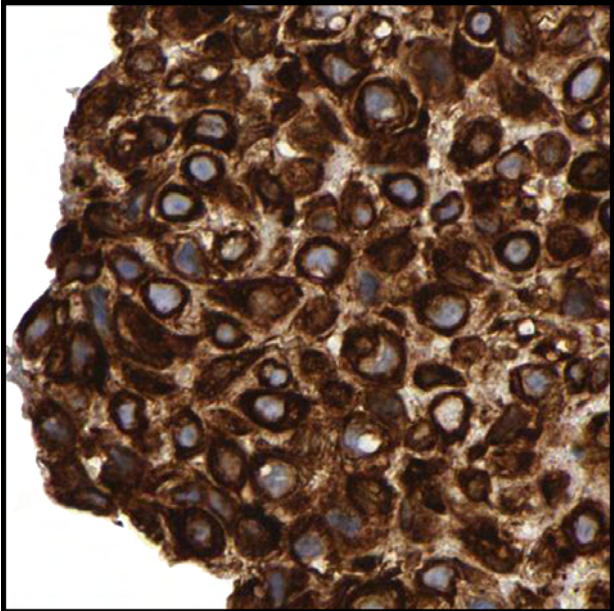
Strong staining of endometrial glandular cells.

Negative decidual cells surrounding the glandular cells.

Placenta

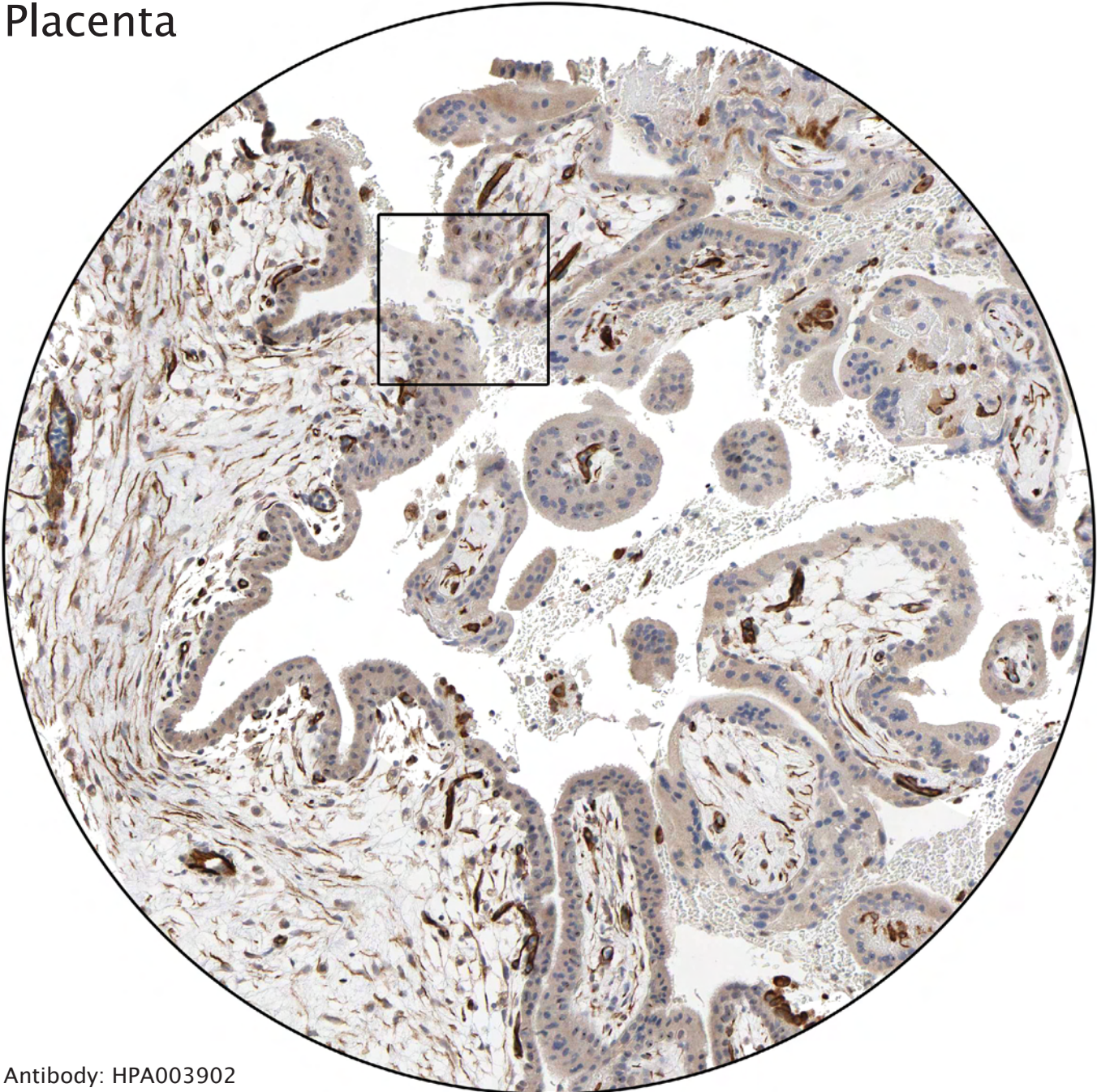


Antibody: CAB004498

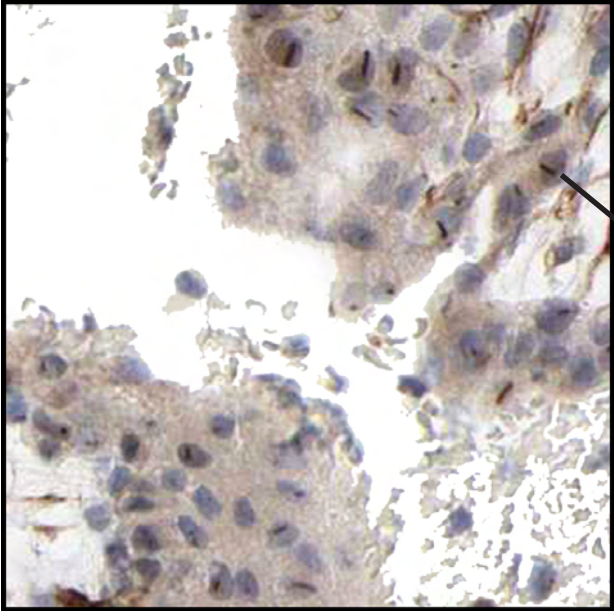


Accumulation of trophoblasts.

Placenta

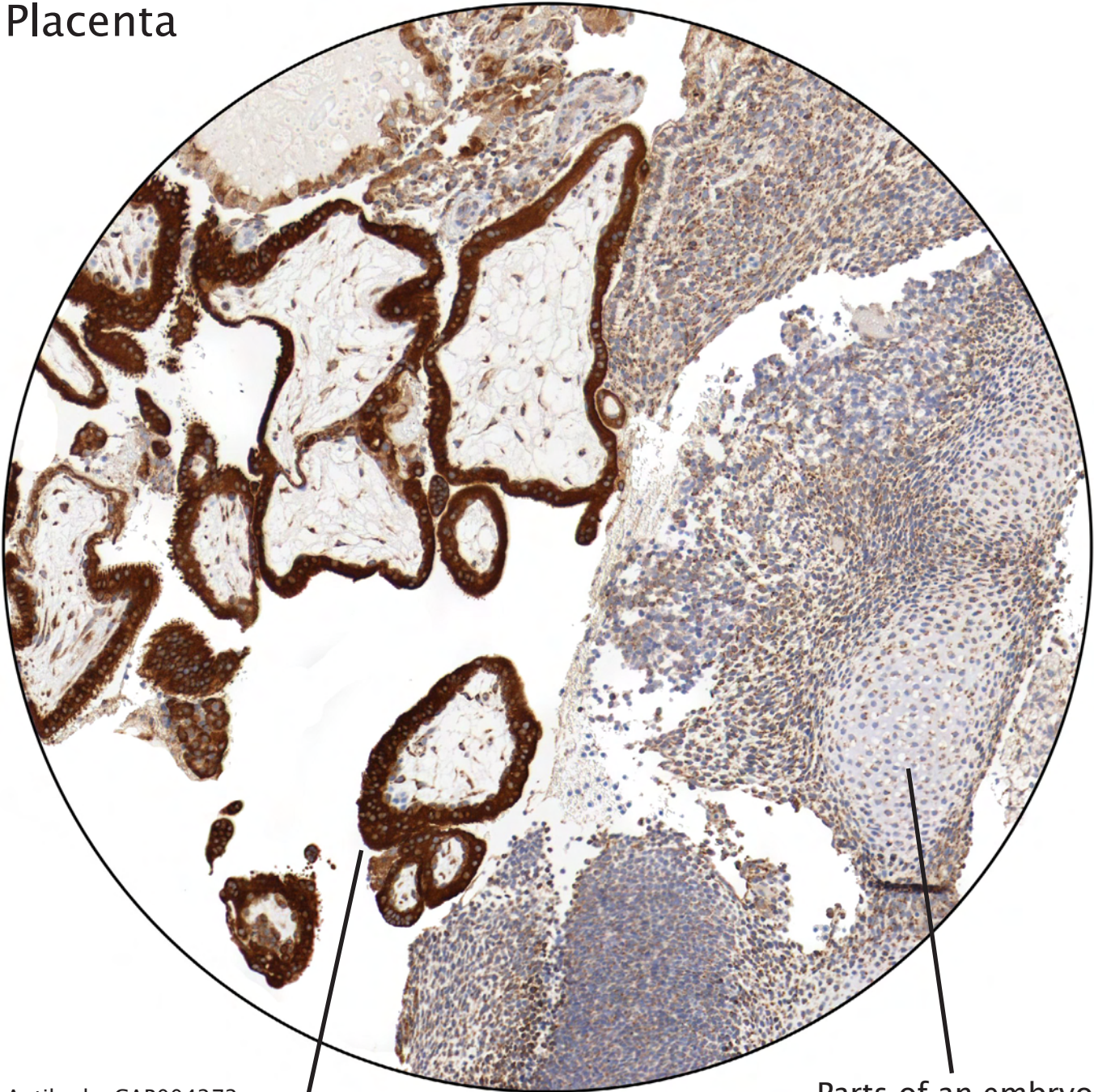


Antibody: HPA003902



Positivity of rodlike structures in nuclei of trophoblasts. The underlying basis for this staining pattern is unclear.

Placenta

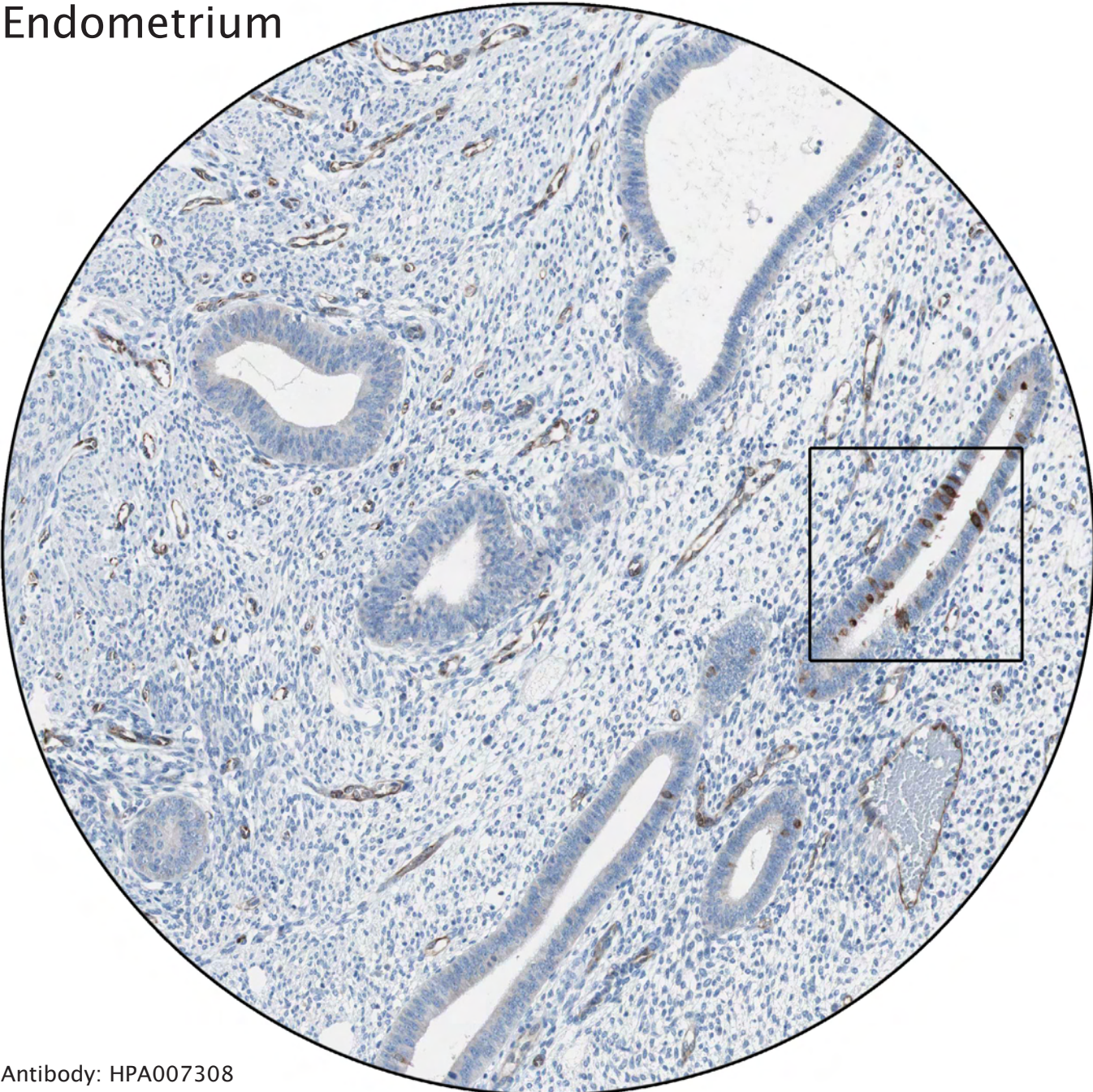


Antibody: CAB004272

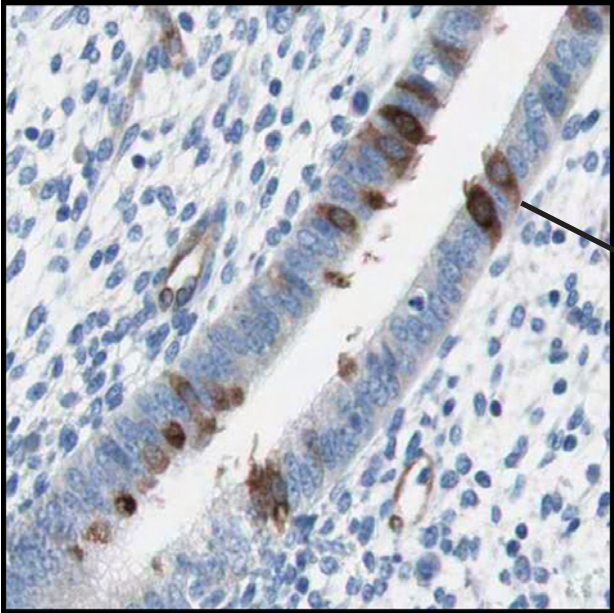
Parts of an embryo

Distinctly stained trophoblasts

Endometrium

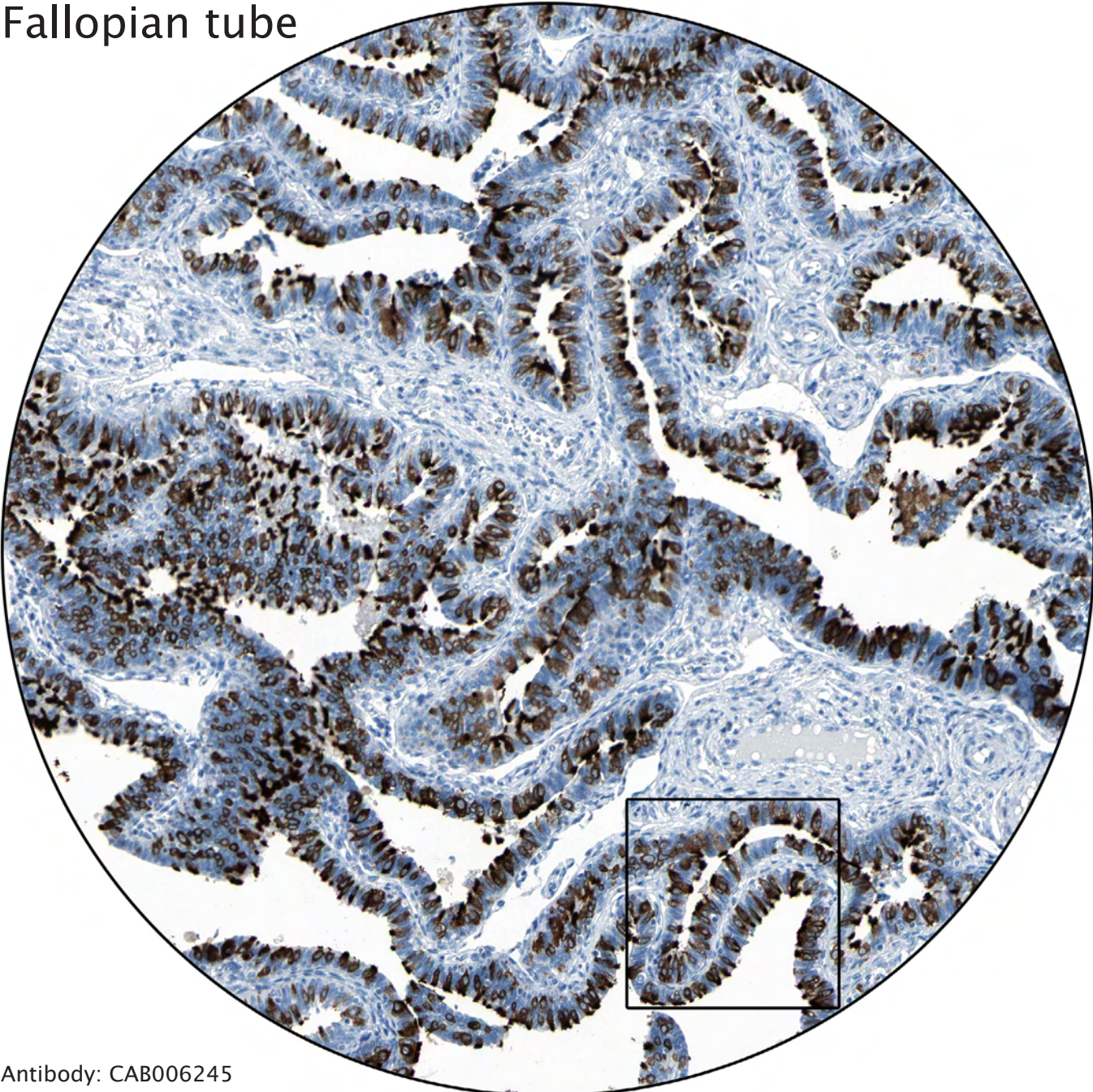


Antibody: HPA007308

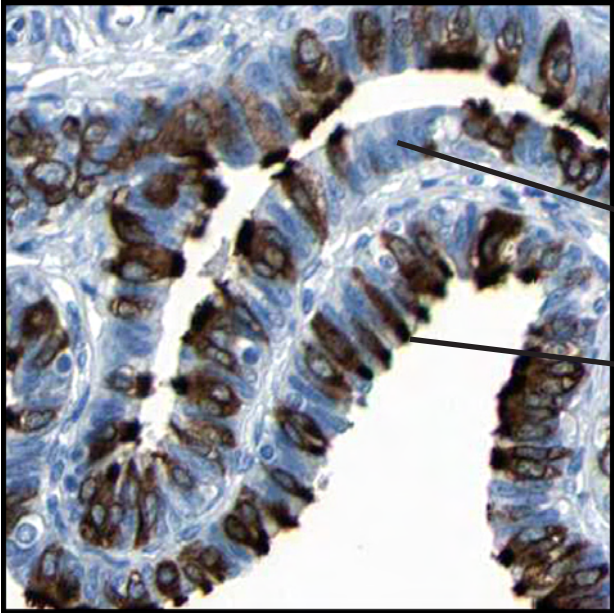

Distinct immunoreactivity of ciliated cells.

Fallopian tube



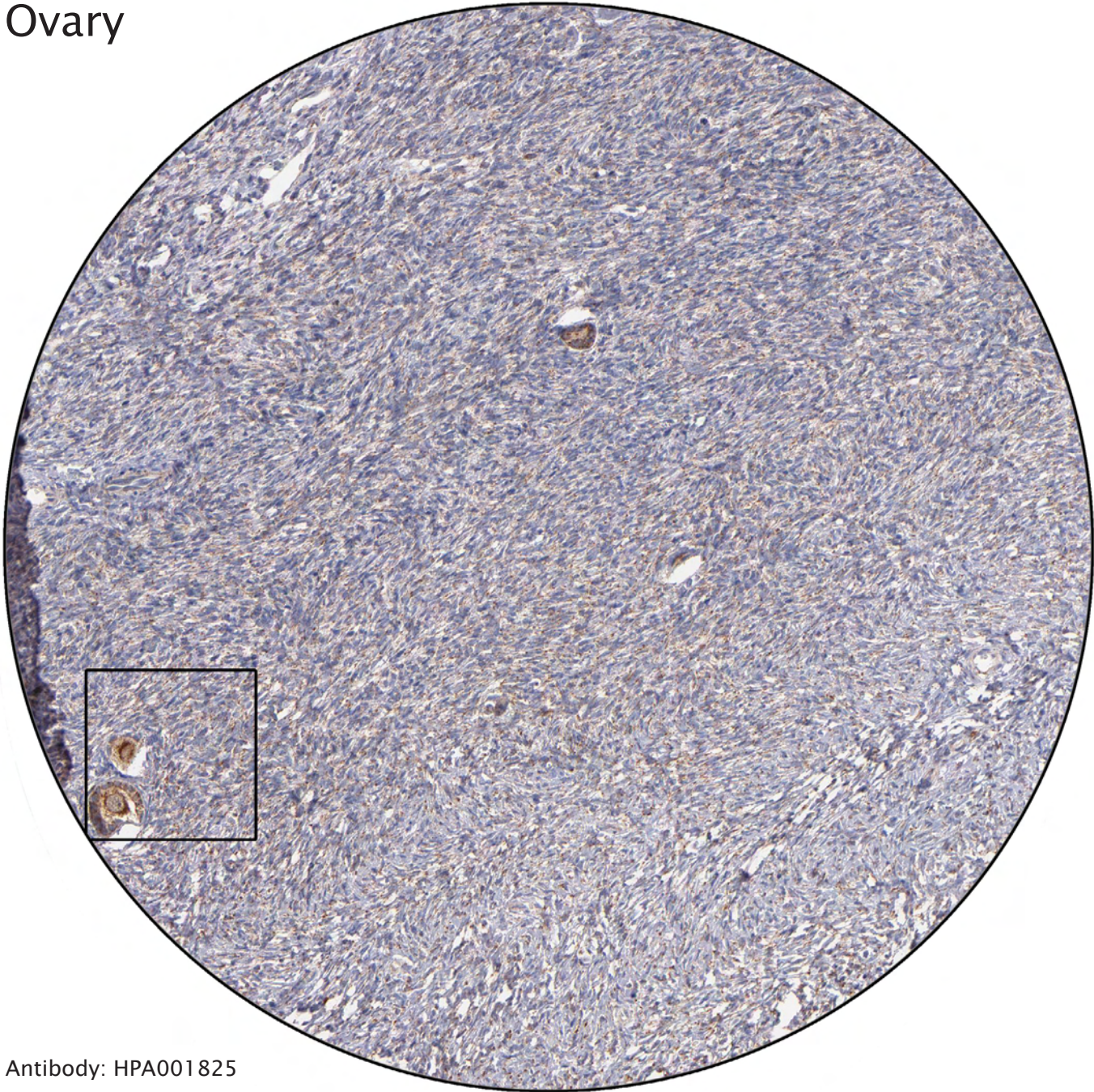
Antibody: CAB006245



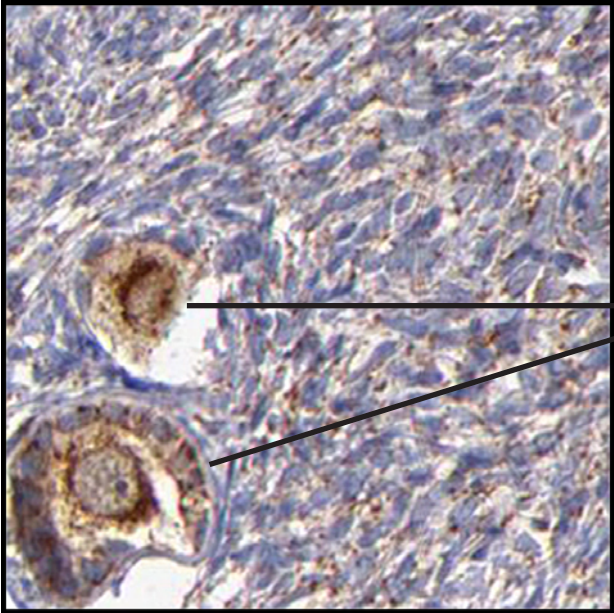
Secretory cells negative.

Ciliated cells distinctly stained.

Ovary

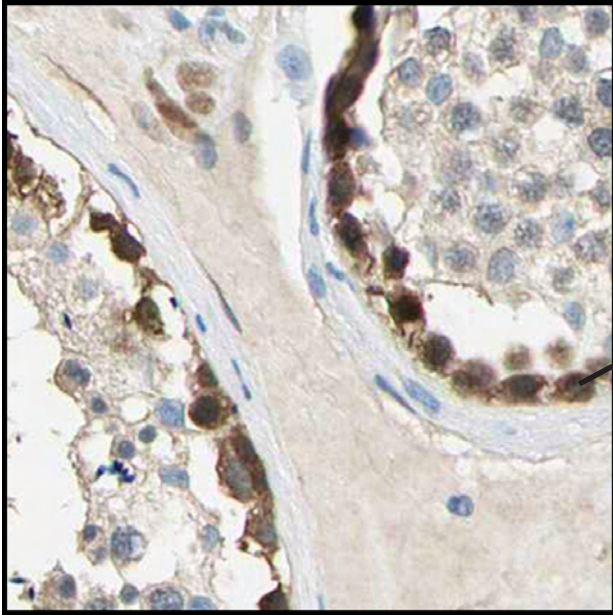


Antibody: HPA001825



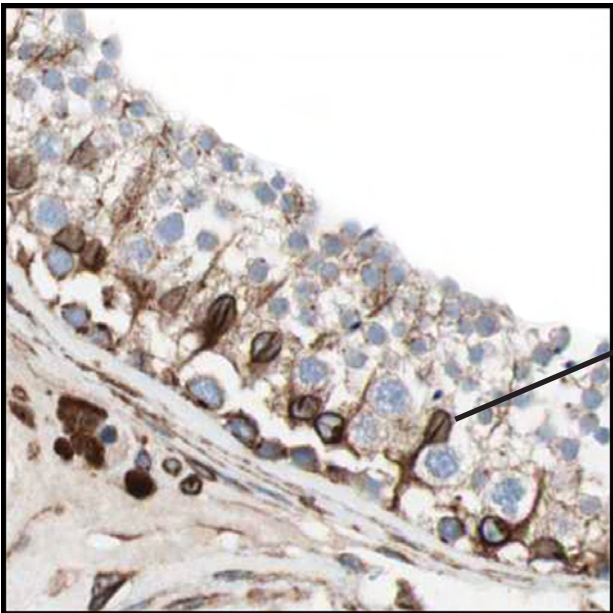
Positive follicles with central oocytes.

Testis



Spermatogonia, situated closest to the basal membrane, strongly stained.

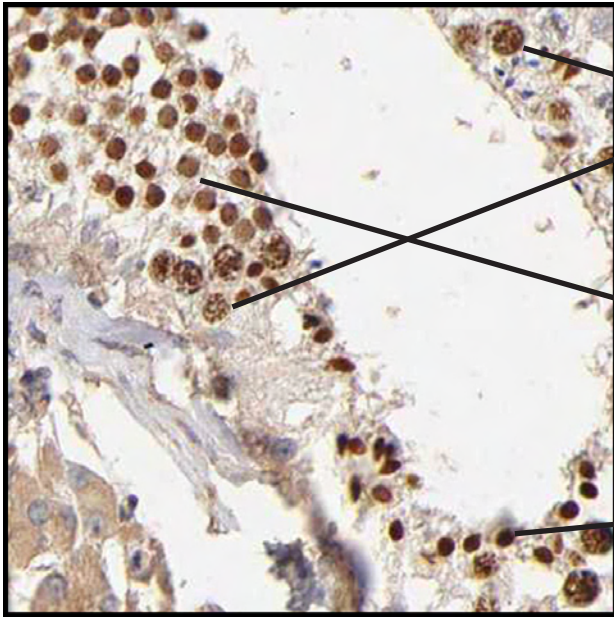
Antibody: HPA005993



The distinctly stained cells are sertoli cells, supporting cells that often have visible nucleoli.

Antibody: HPA007342

Testis

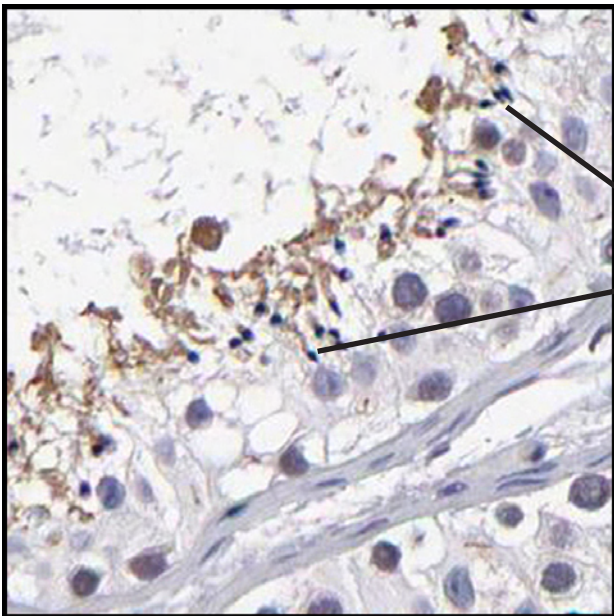


Primary spermatocytes, the largest cells of the spermatogenesis. The nuclei contain visible chromosomes.

Secondary spermatocytes, short-lived cells that develop into spermatids.

Spermatids undergo spermiogenesis and have small condensed nuclei.

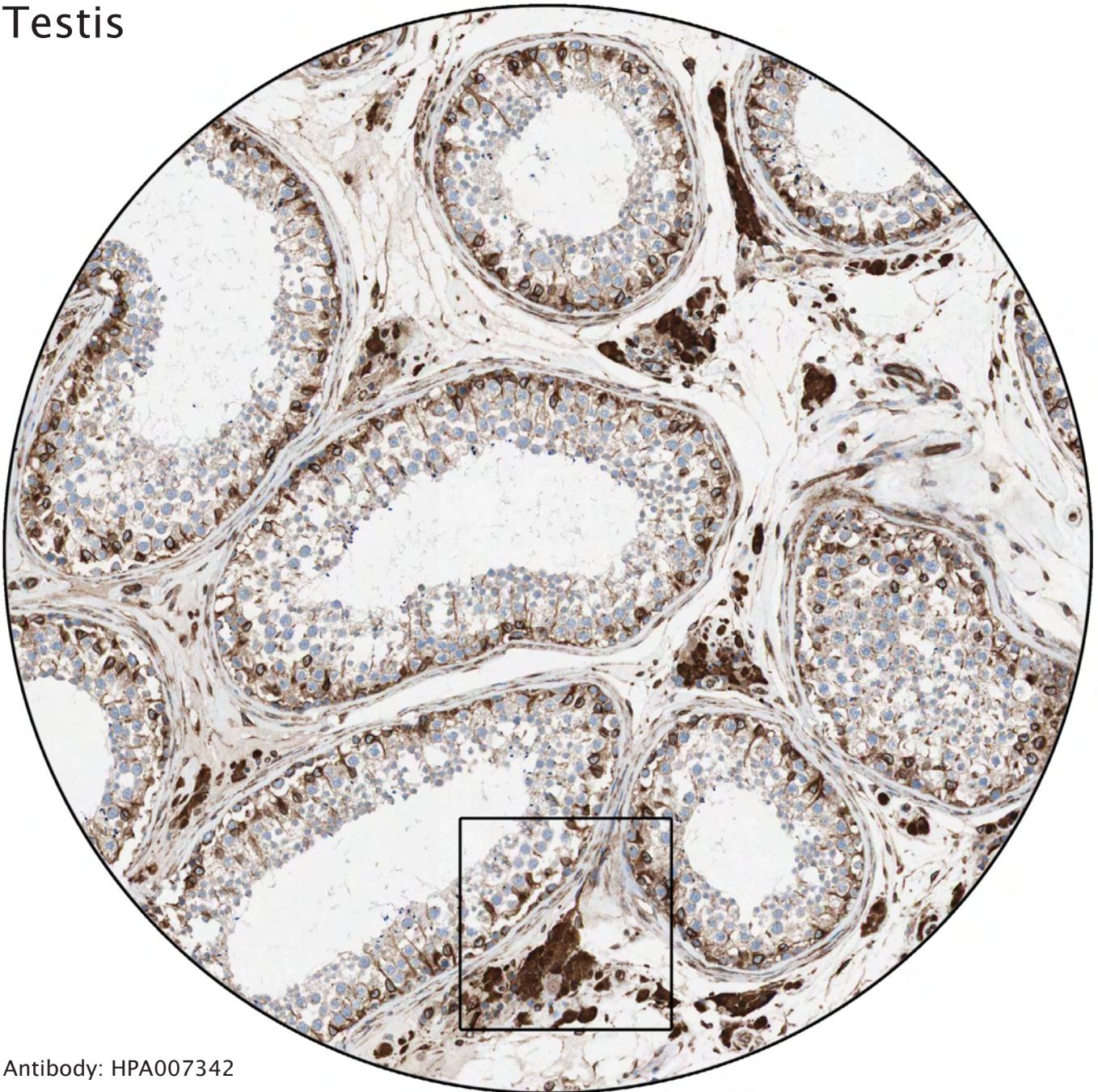Antibody: HPA003903



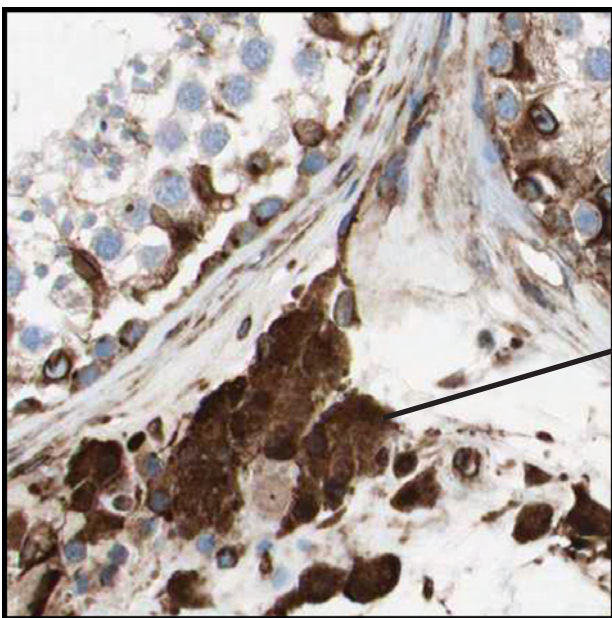
Spermatozoa, the end result of the spermiogenesis. The mature sperms are released into the lumen of seminiferous ducts.

Antibody: HPA001874

Testis



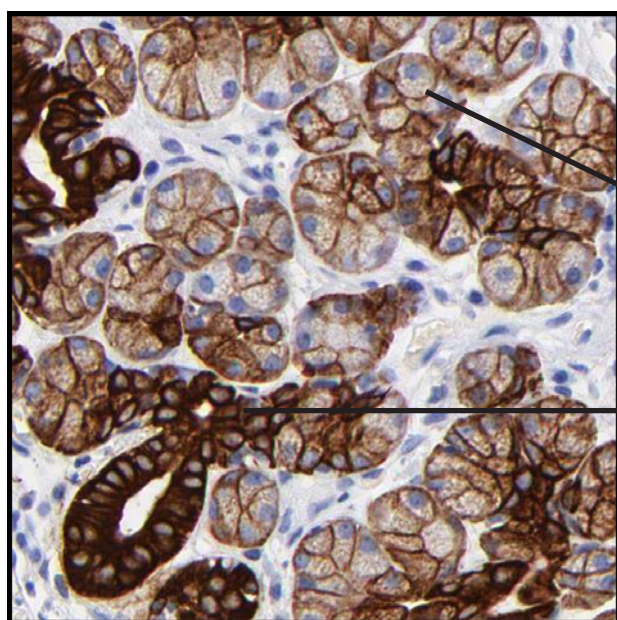
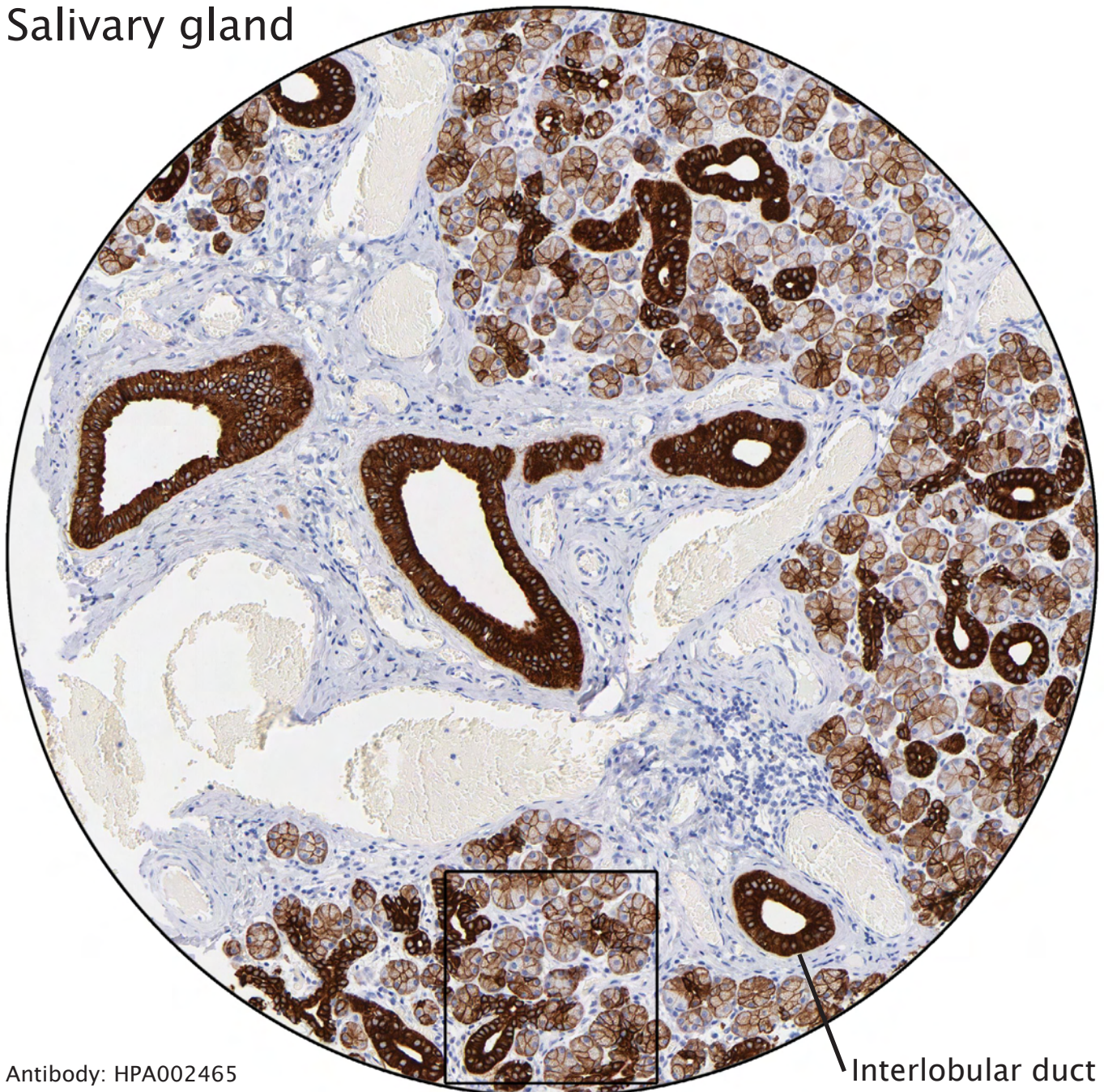
Antibody: HPA007342



Distinct immunoreactivity of Leydig cells.

----- Different celltypes and intracellular structures -----

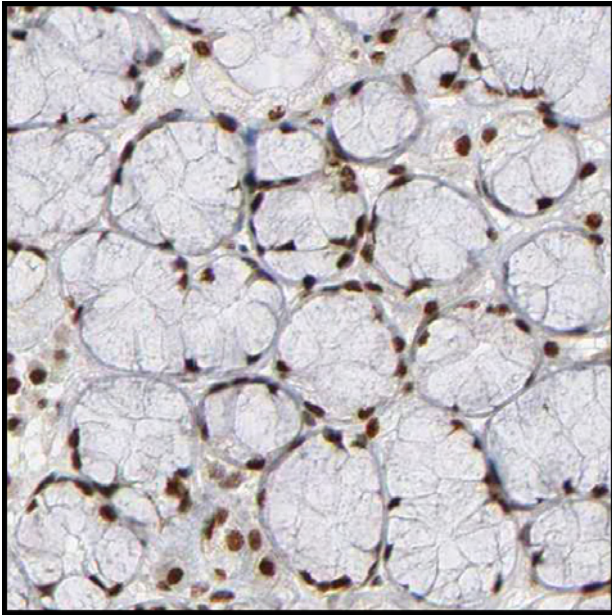
Salivary gland



Membranous positivity of glandular cells.

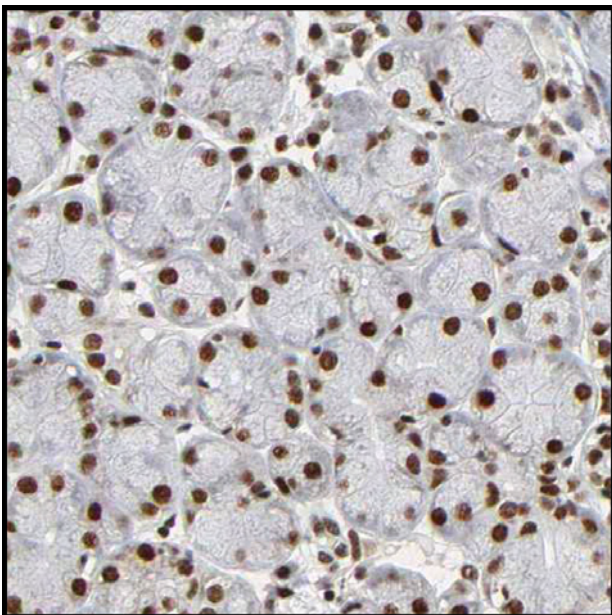
Distinct staining of intercalated ducts.

Salivary gland



Mucous acini are found in the sublingual glands and have oval, basally located nuclei.

Antibody: CAB004216

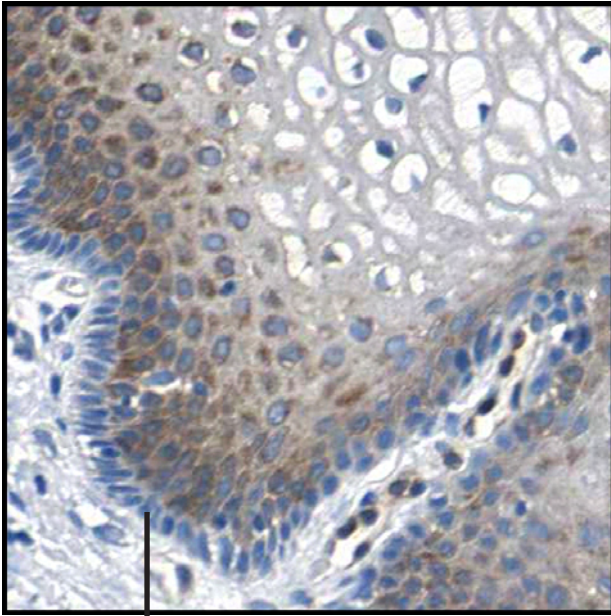


Serous acini are found in the parotid gland and have pyramidal-shaped cells with round nuclei.

The submandibular gland contains both mucous and serous acini.

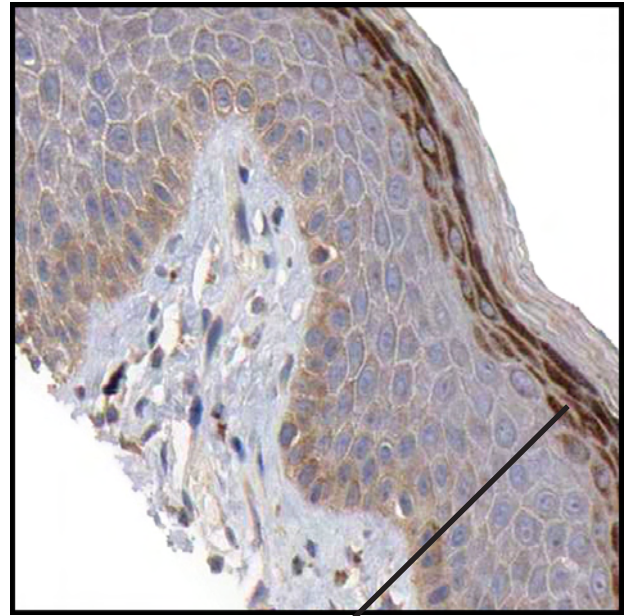
Skin

Antibody: HPA001813



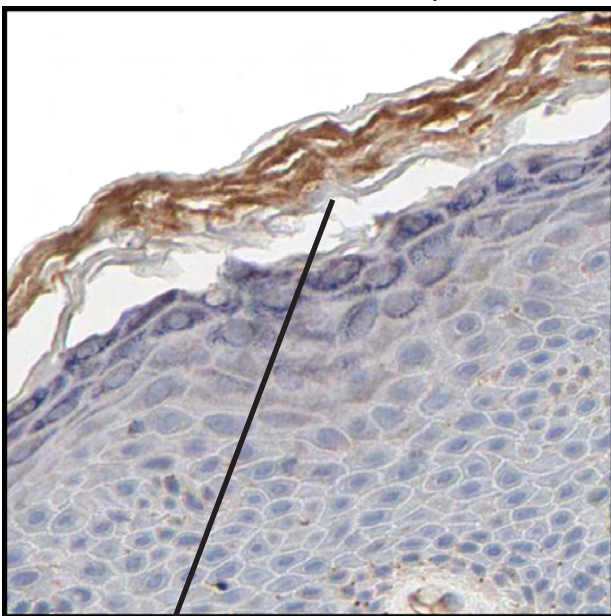
Stratum basale. The basal, negative layer.
Positivity of stratum spinosum.

Antibody: HPA004006



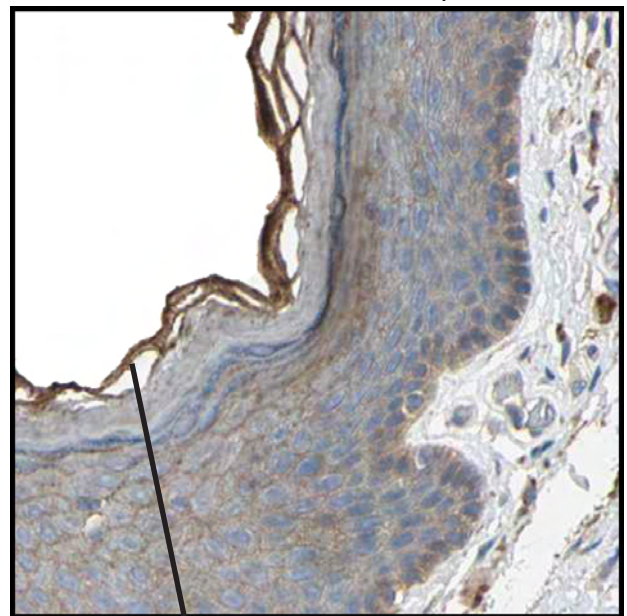
Strong staining of stratum granulosum, the superficial layer closest to the keratinized layers.

Antibody: HPA003747



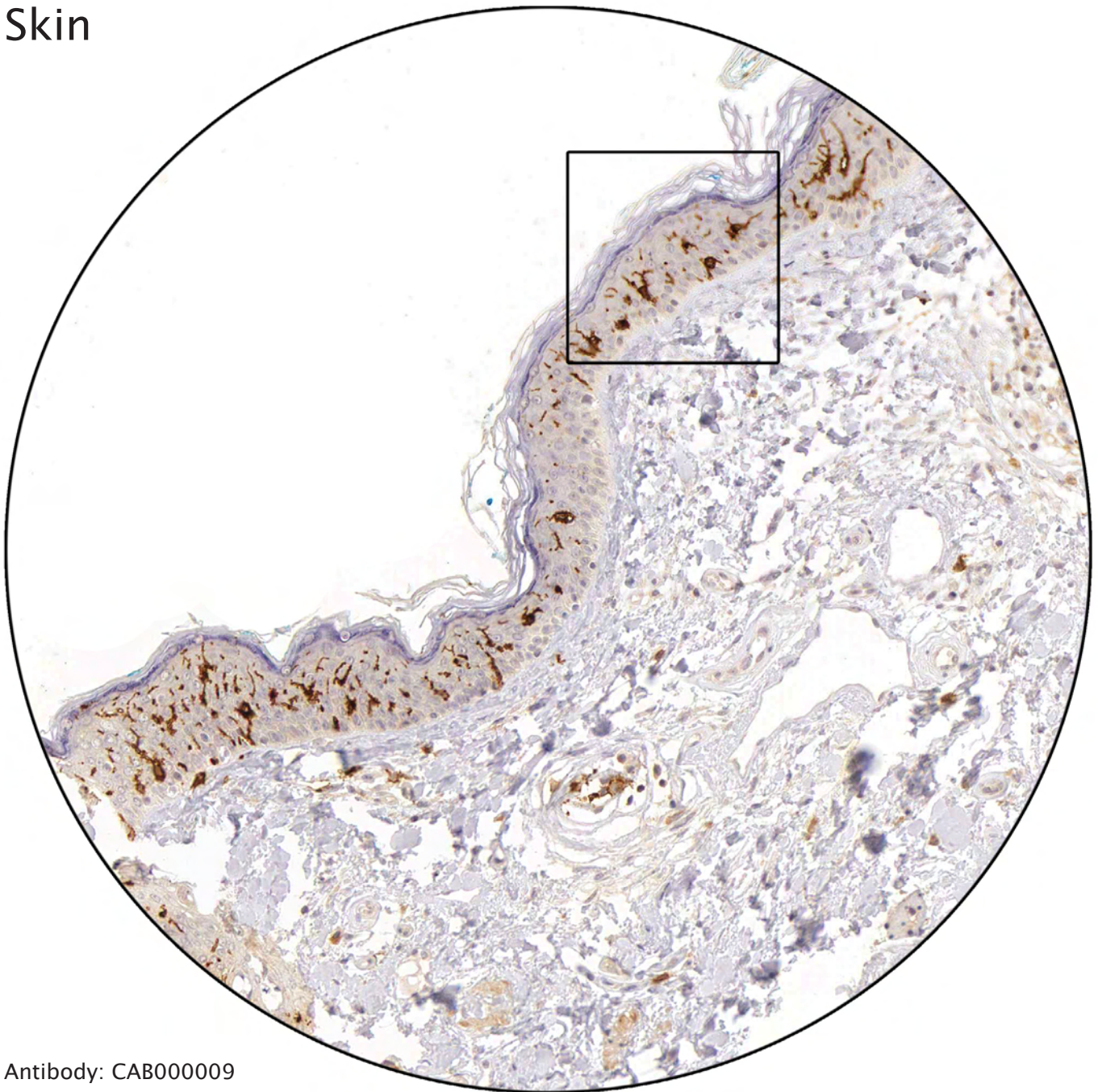
Stratum lucidum, the inner keratinized layer, is negative, while most of stratum corneum is distinctly stained.

Antibody: CAB005282

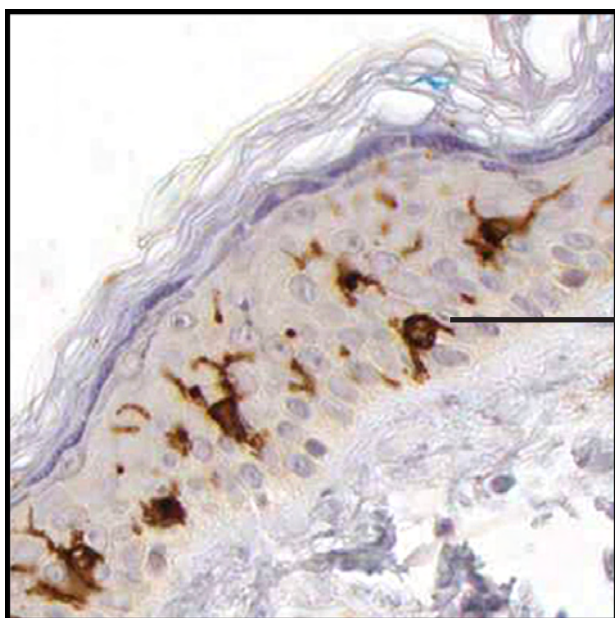


Positivity of stratum disjunctum, the superficial keratinized layer.

Skin

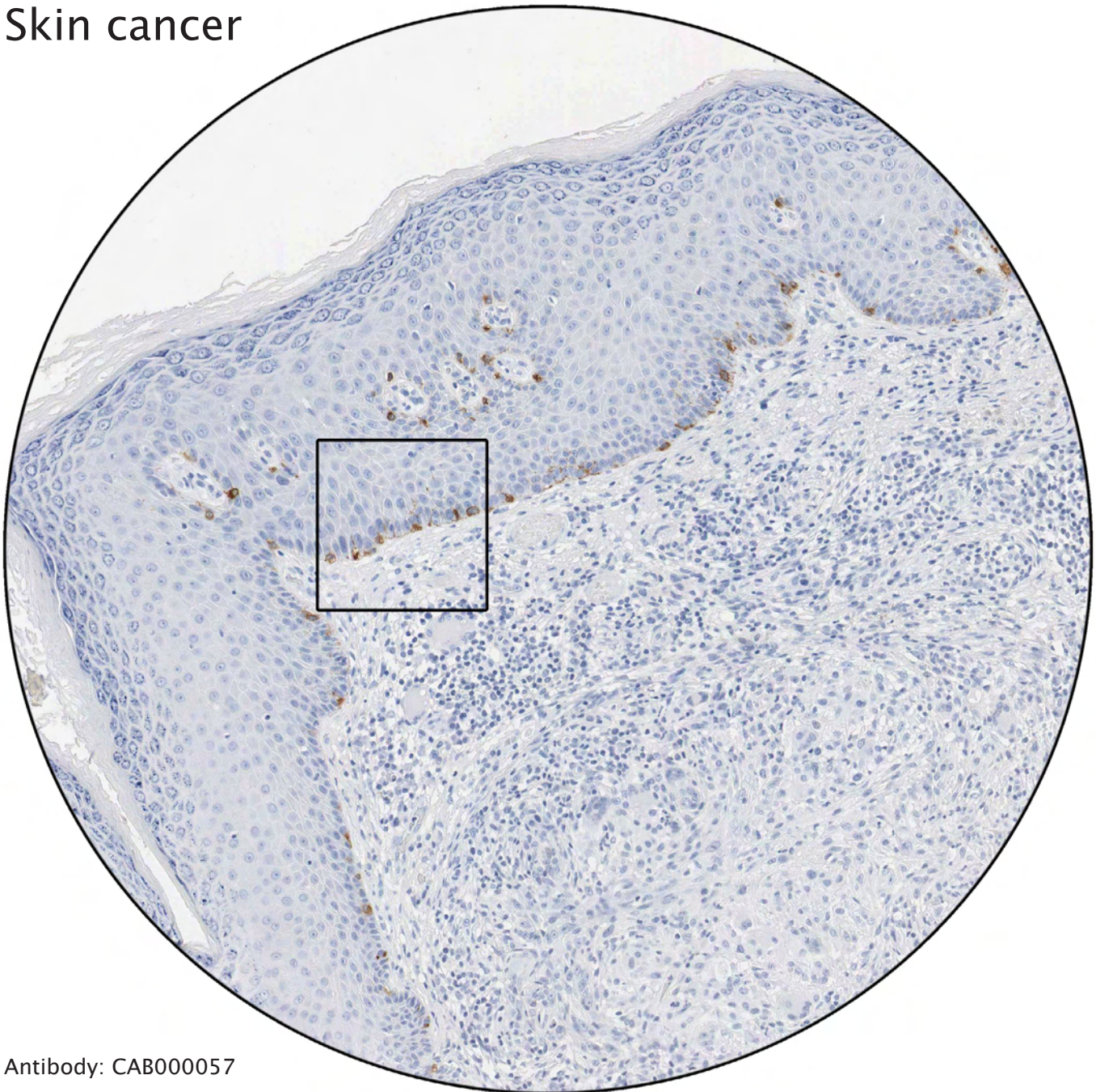


Antibody: CAB000009

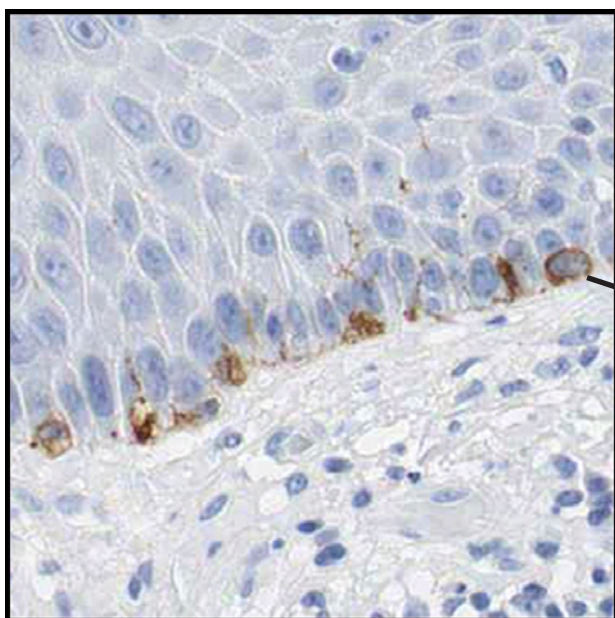


Positivity of dendritic antigen-presenting cells (Langerhans cells).

Skin cancer



Antibody: CAB000057

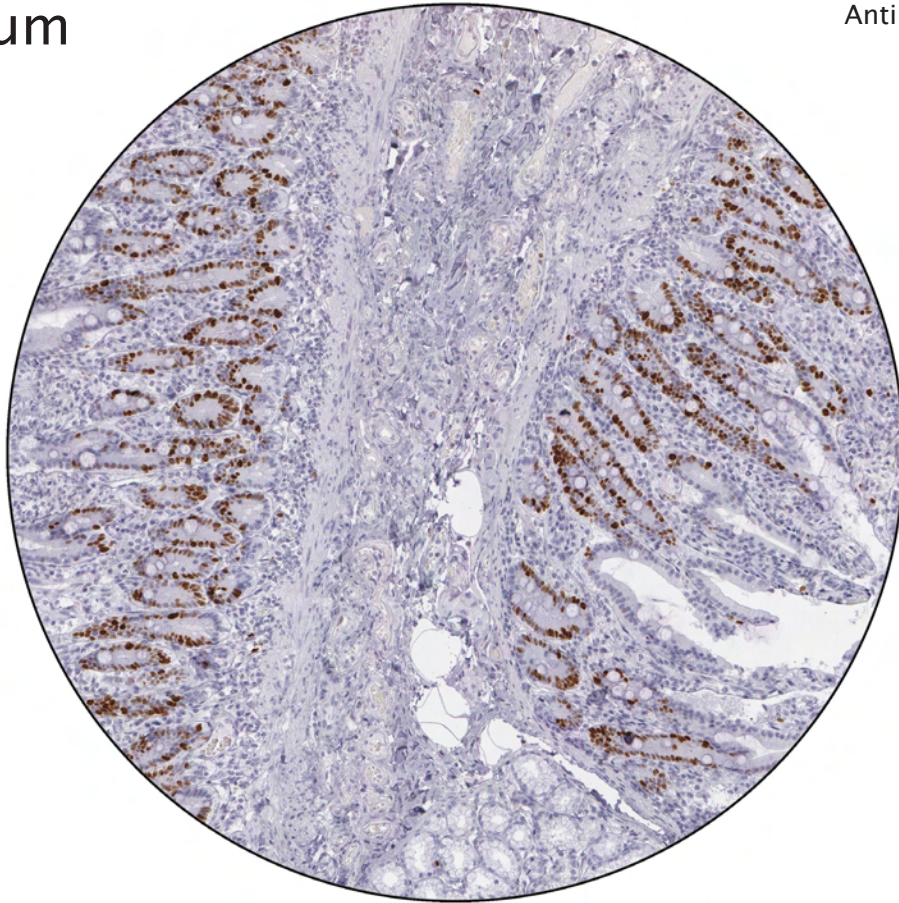


Positivity of melanocytes.

----- Different celltypes and intracellular structures -----

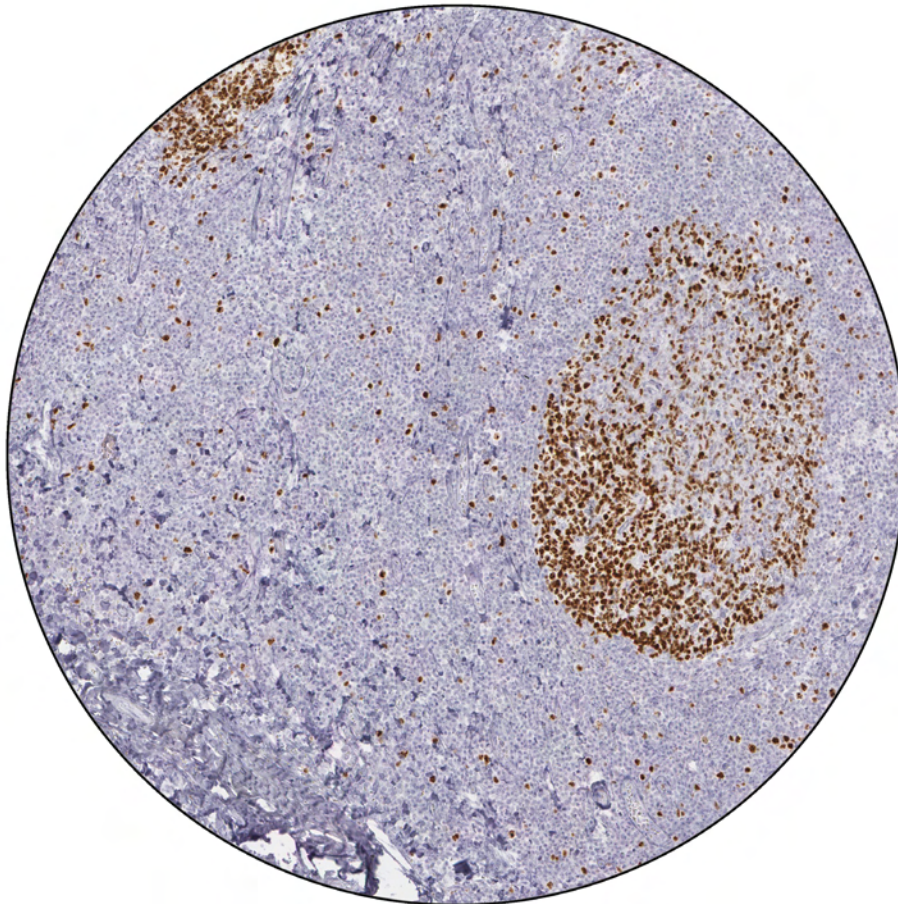
Duodenum

Antibody: CAB000058



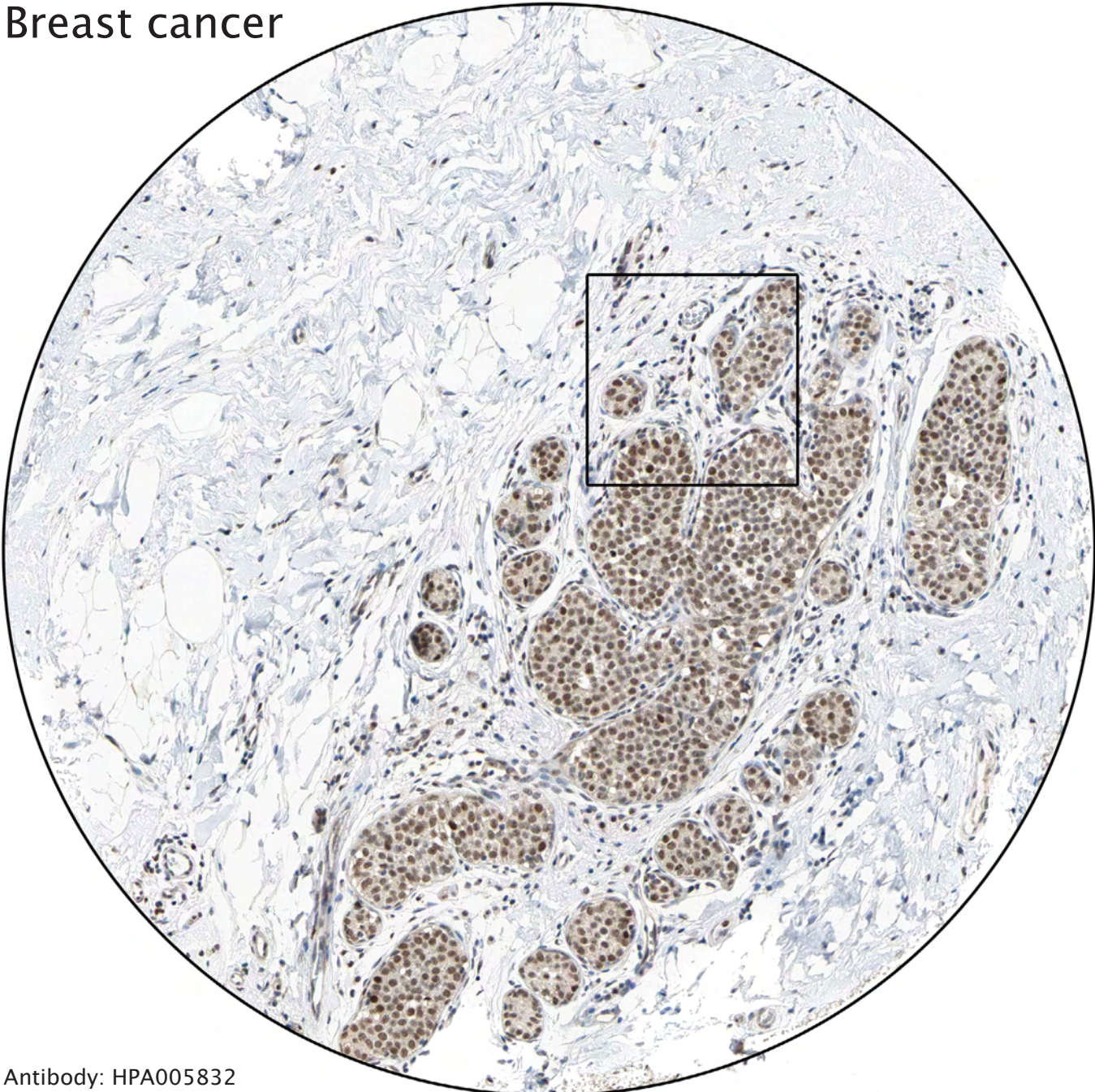
Strong positivity of proliferating cells. Examples of positive cells are shown in deep crypts of the intestine and in lymphoid germinal centra.

Tonsil

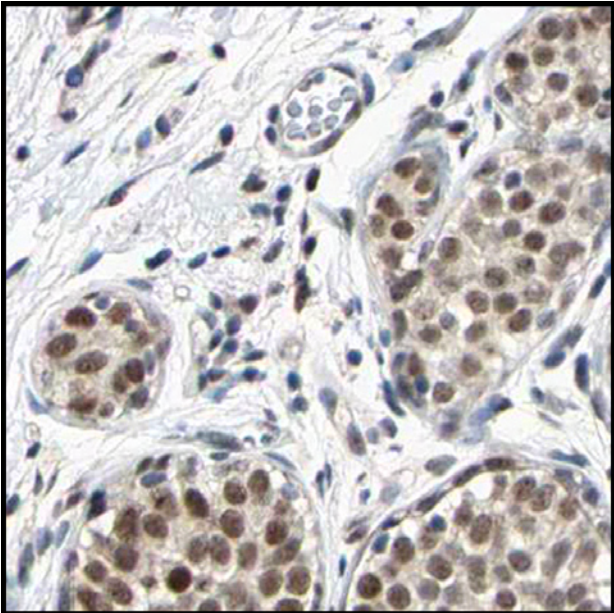


----- Different celltypes and intracellular structures? -----

Breast cancer



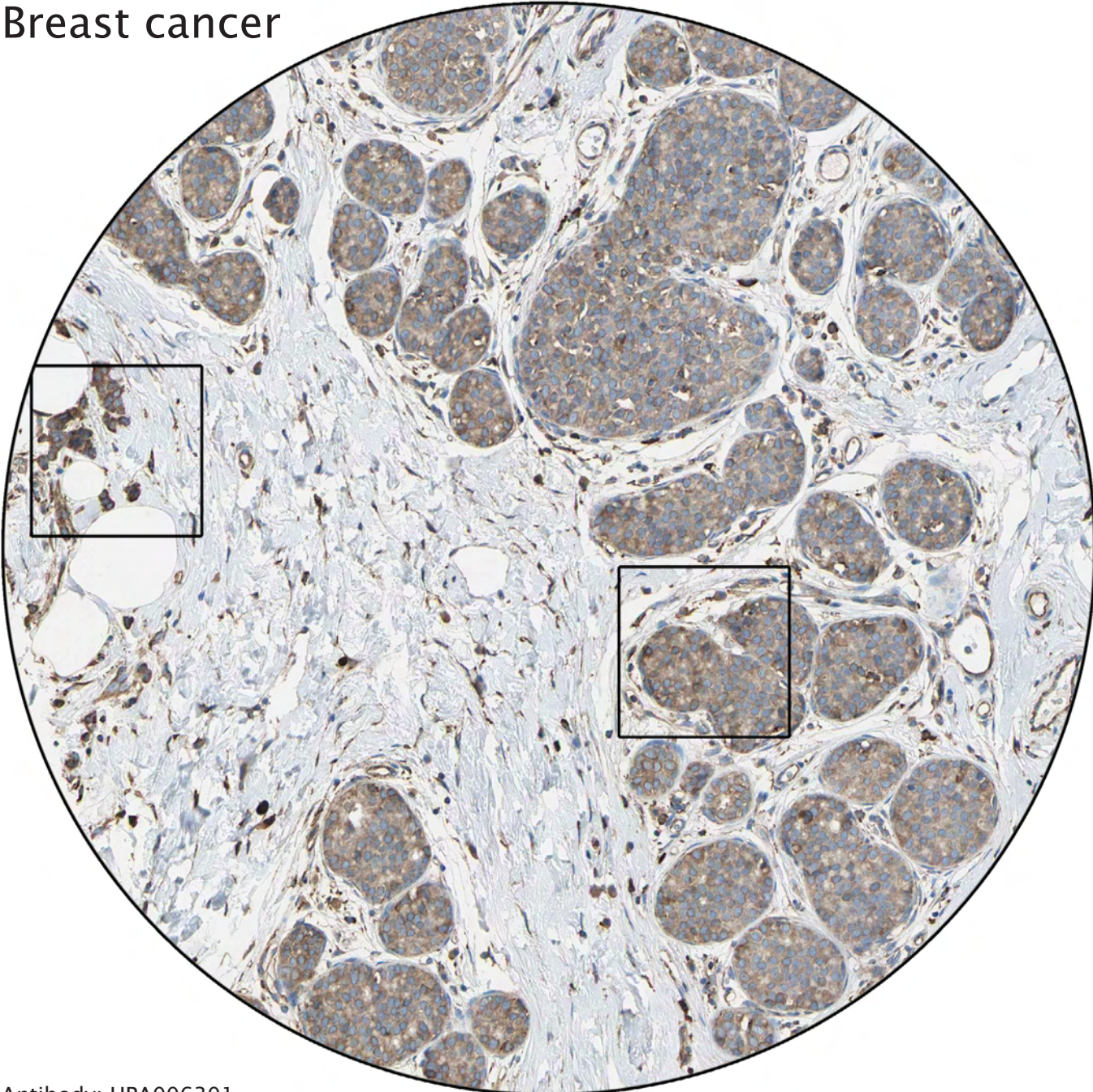
Antibody: HPA005832



Atypical lobular hyperplasia or lobular cancer in situ.

----- Tumor cells or not? -----

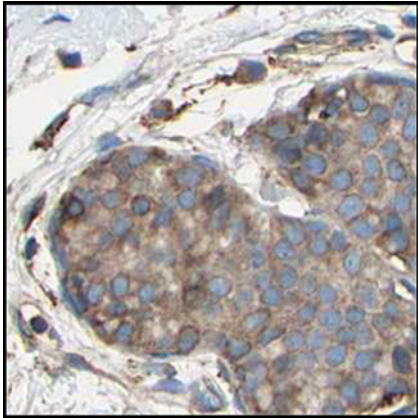
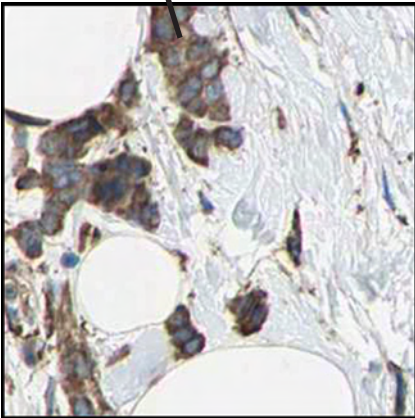
Breast cancer



Antibody: HPA006301

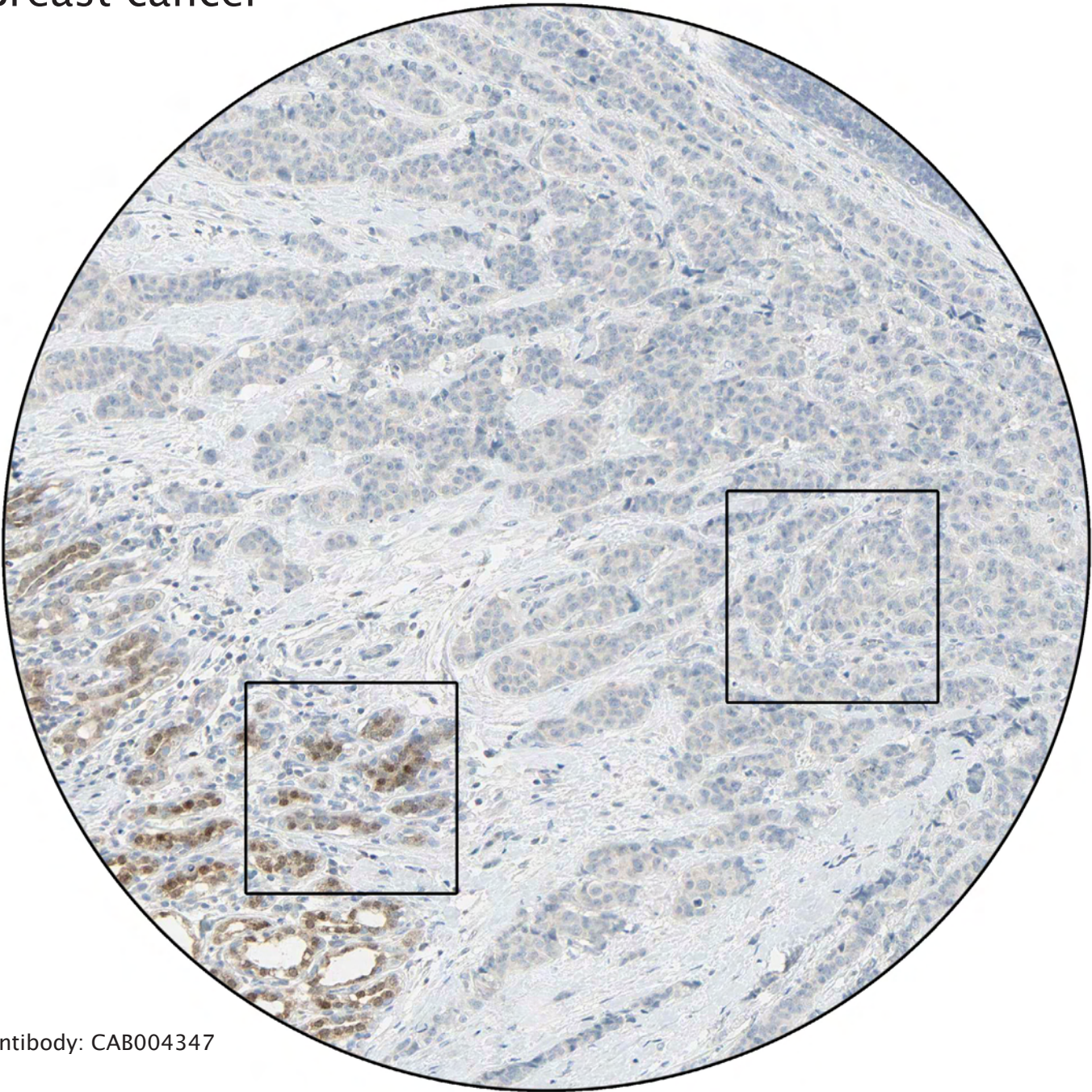
Only these cells represent invasive cancer.

All the other tumor cells represent cancer in situ and should not be annotated as cancer.



----- Tumor cells or not? -----

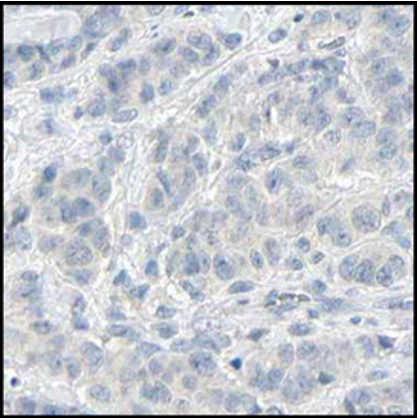
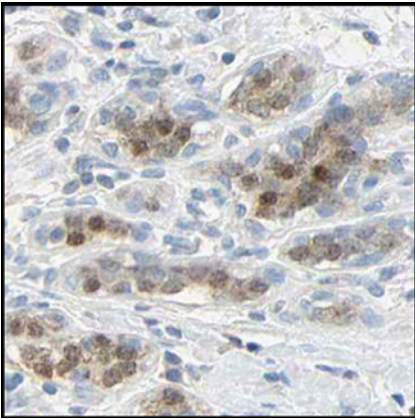
Breast cancer



Antibody: CAB004347

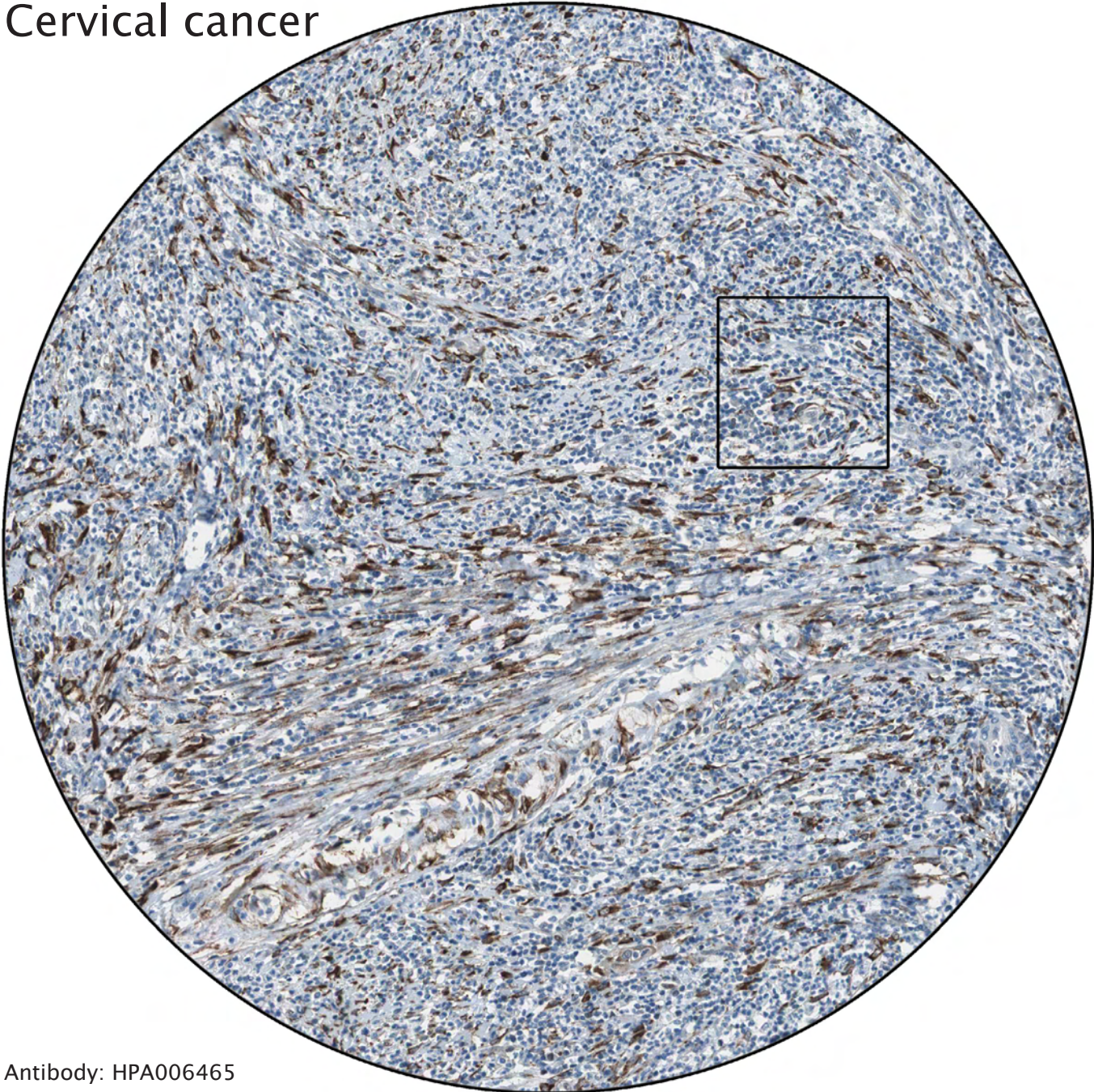
Positivity of benign glandular cells.

The malignant cells are negative.

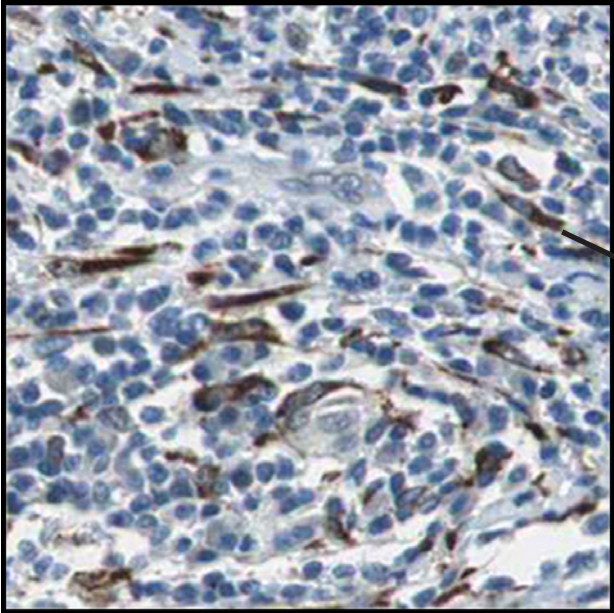


----- Tumor cells or not? -----

Cervical cancer



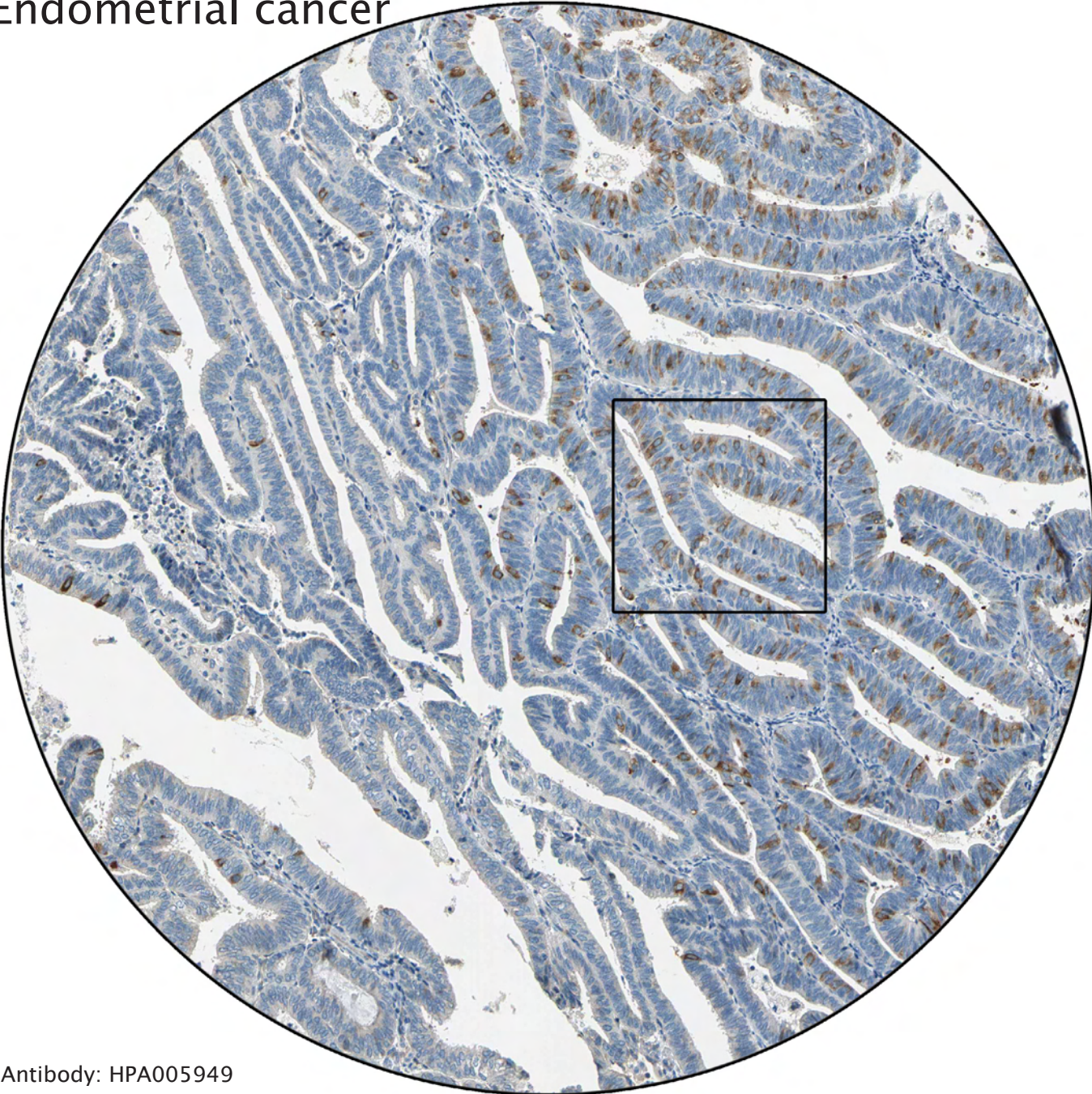
Antibody: HPA006465



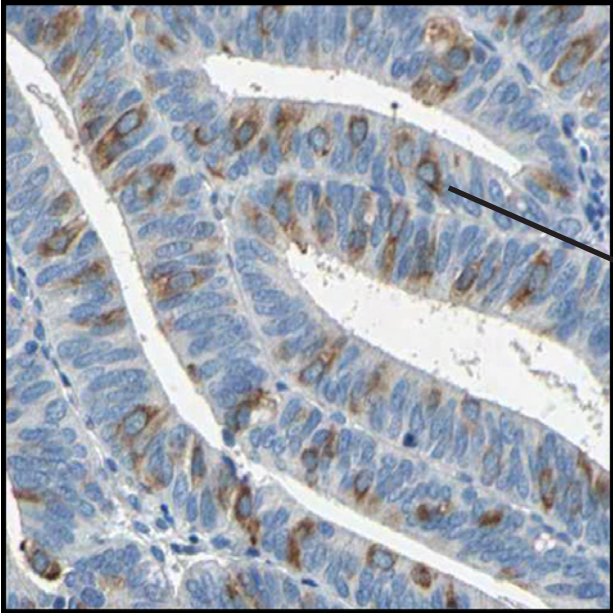
Distinct staining of tumor stroma (positive fibroblasts).

----- Tumor cells or not? -----

Endometrial cancer



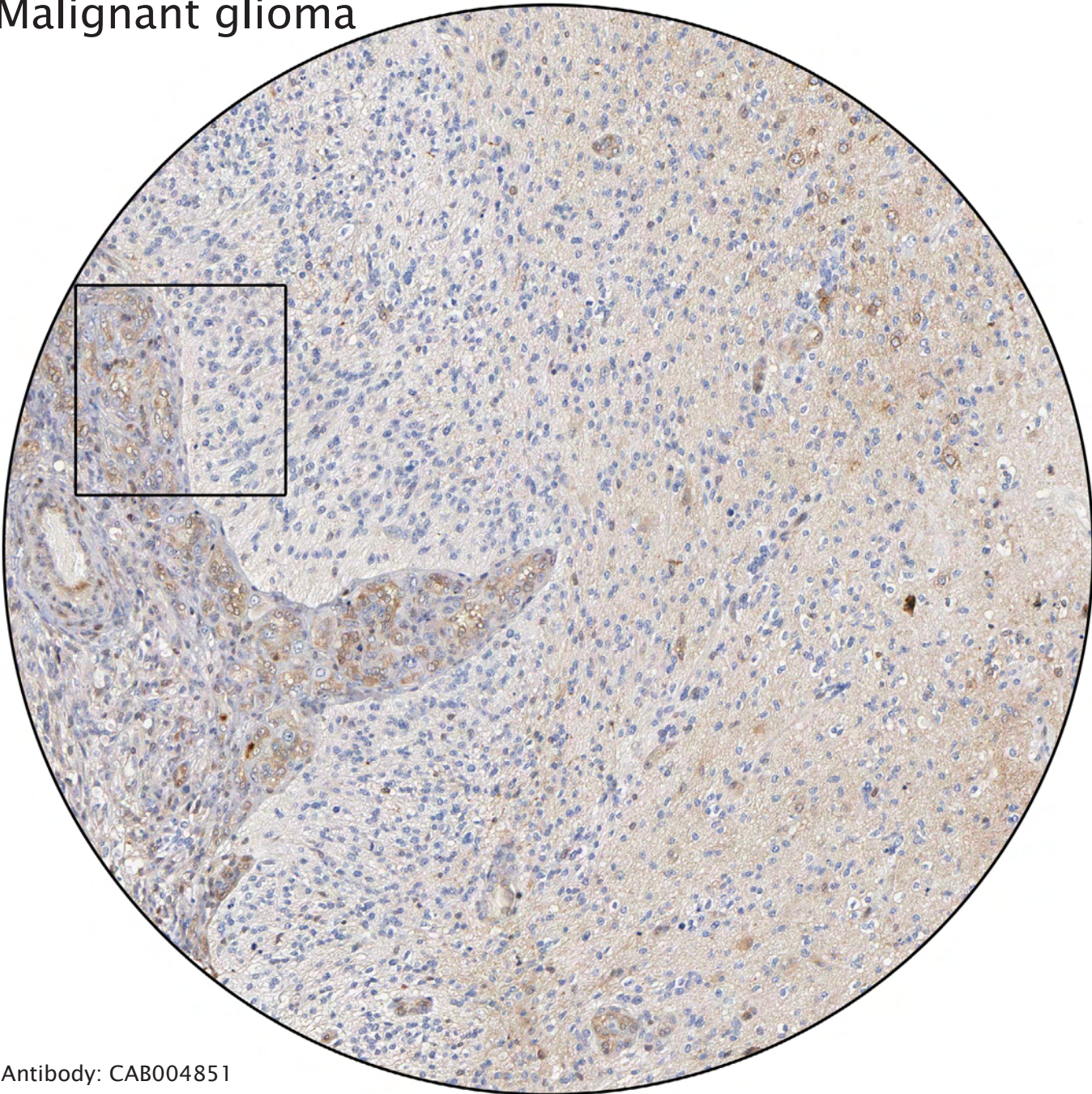
Antibody: HPA005949



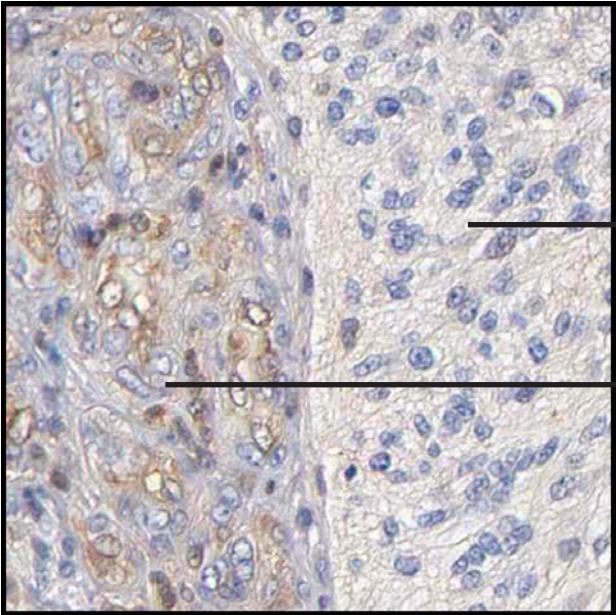
Distinct immunoreactivity of a subpopulation of tumor cells, possibly of endocrine phenotype.

----- Tumor cells or not? -----

Malignant glioma



Antibody: CAB004851

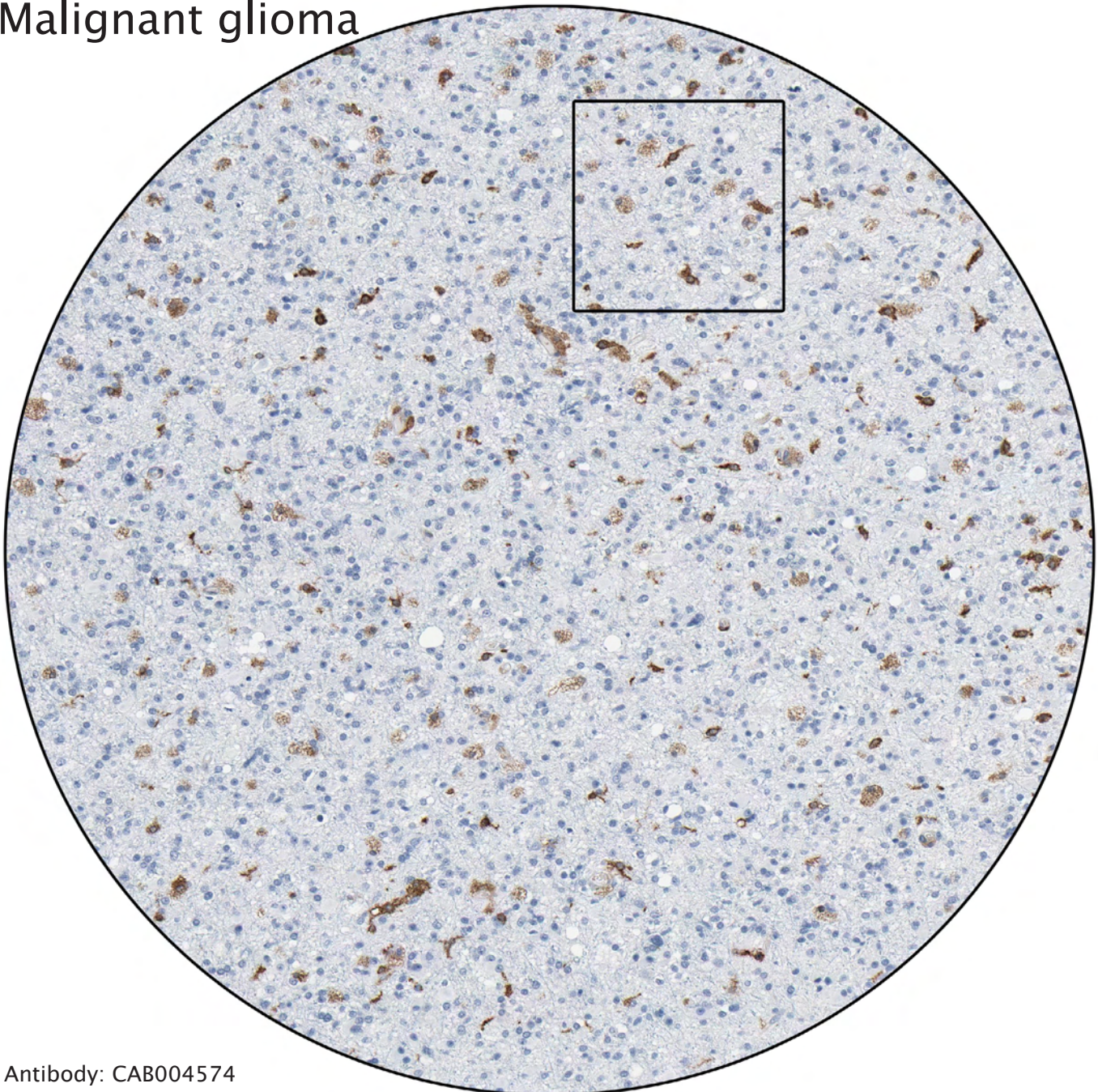


Negative tumor cells.

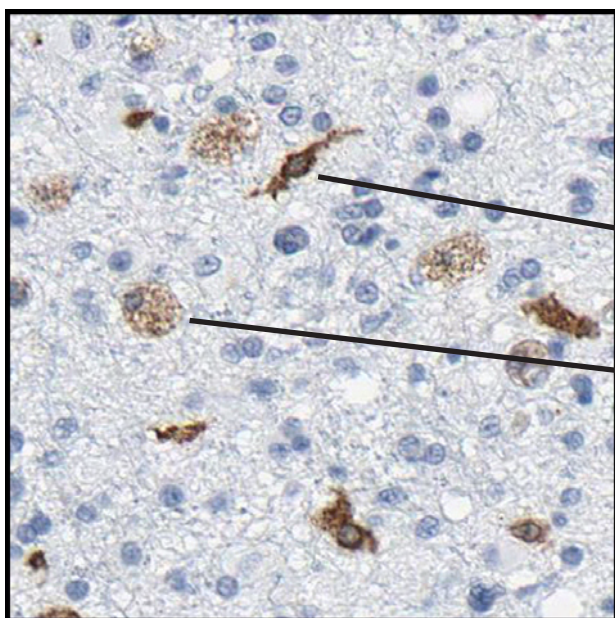
Positivity of epitheloid endothelial cell proliferations.

----- Tumor cells or not? -----

Malignant glioma



Antibody: CAB004574




Oligodendrocyte

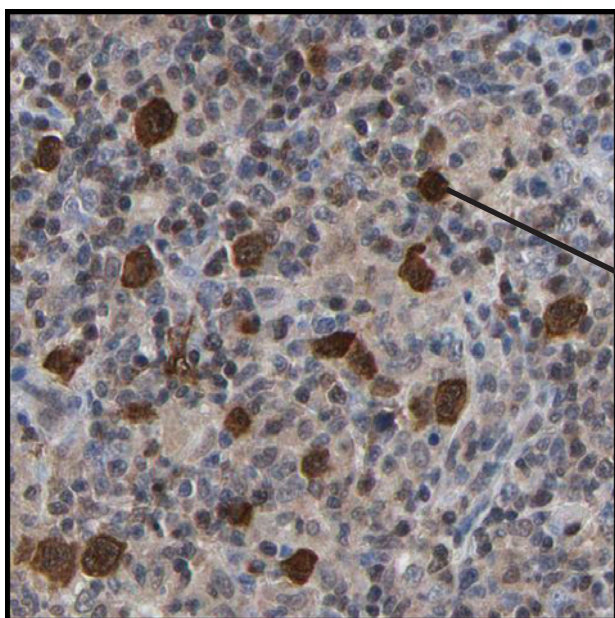
Phagocytic macrophage

----- Tumor cells or not? -----

Hodgkin's disease



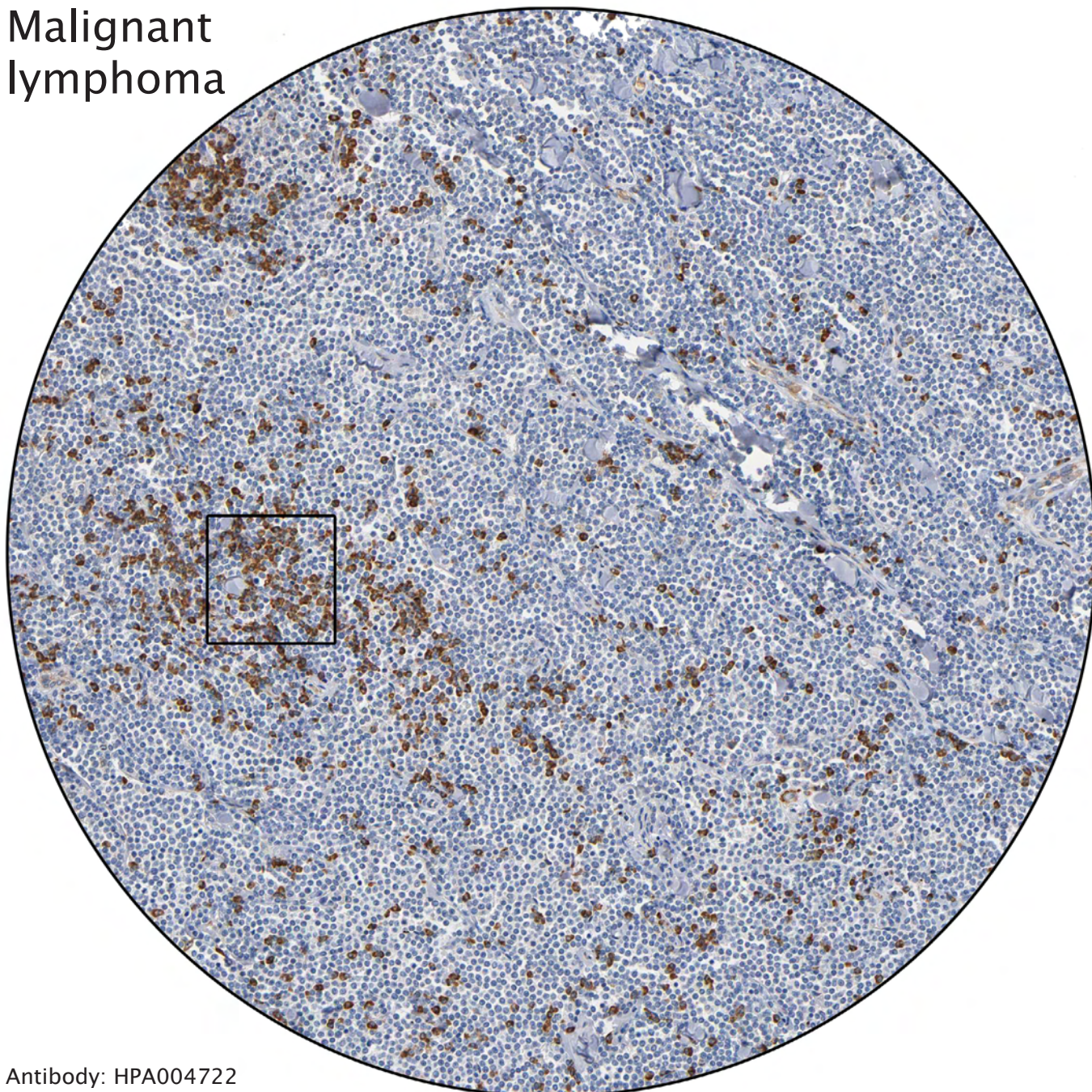
Antibody: CAB003860



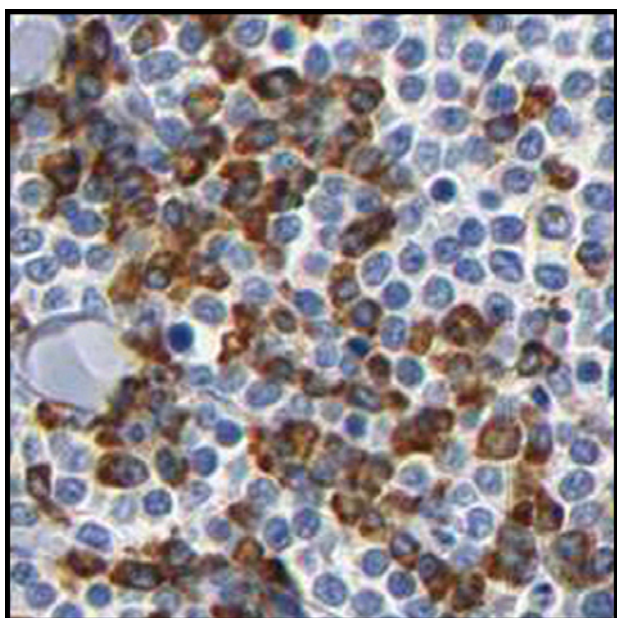
Strong positivity of Hodgkin cells, atypical lymphoid cells found in Hodgkin's disease. The surrounding cells are infiltrating benign lymphoid cells.

----- Tumor cells or not? -----

Malignant lymphoma



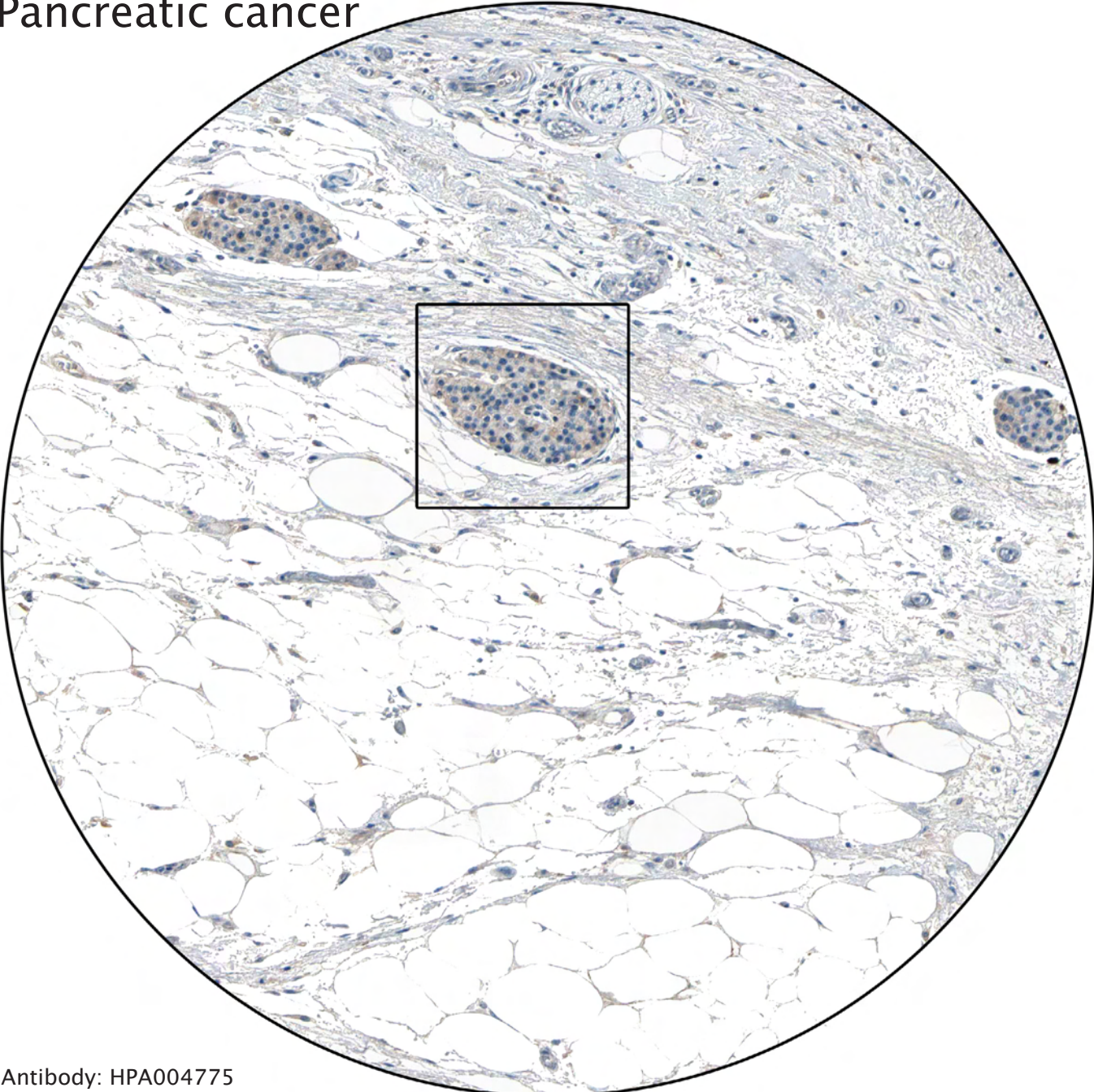
Antibody: HPA004722



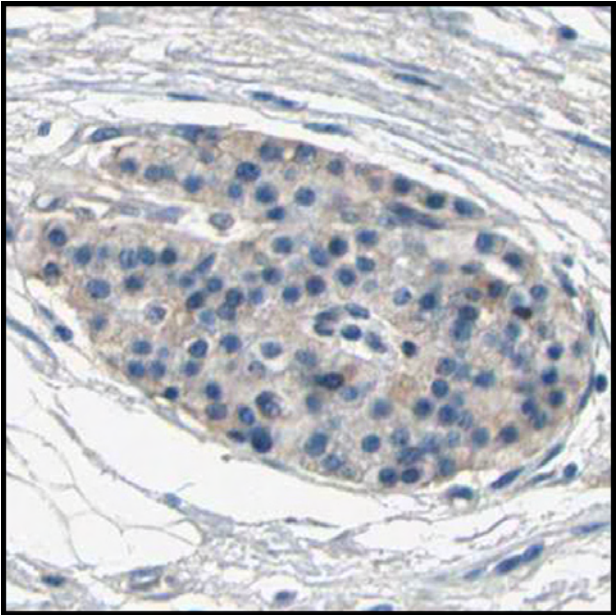
The strongly stained cells are probably reactive lymphocytes, surrounding the negative tumor cells.

----- Tumor cells or not? -----

Pancreatic cancer



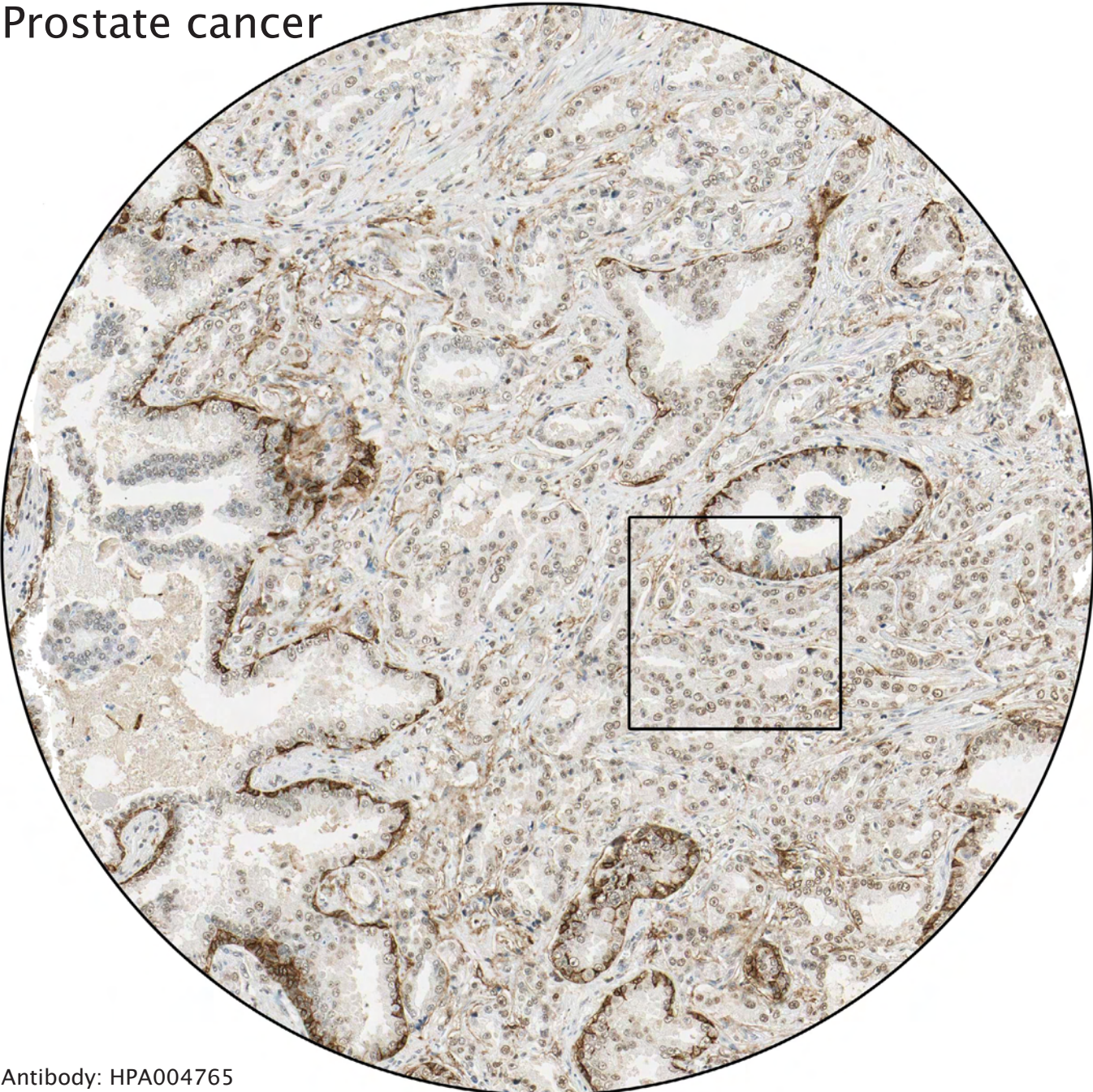
Antibody: HPA004775



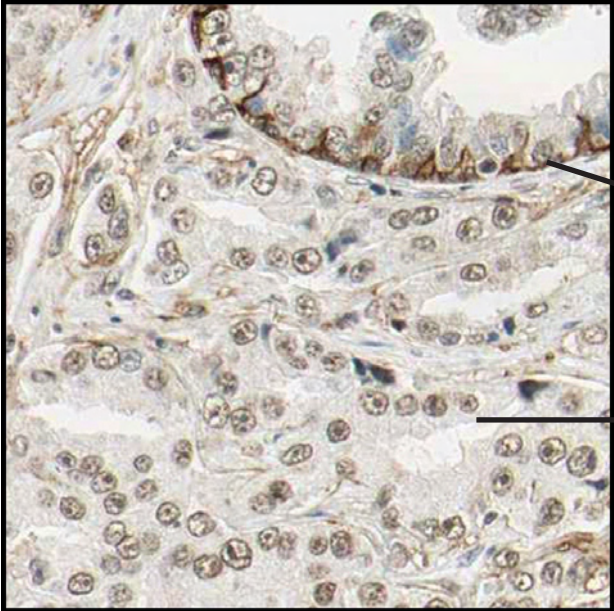
Residual Langerhans islets (endocrine cells) can be found following chronic pancreatitis. There are no tumor cells in the image above.

----- Tumor cells or not? -----

Prostate cancer



Antibody: HPA004765

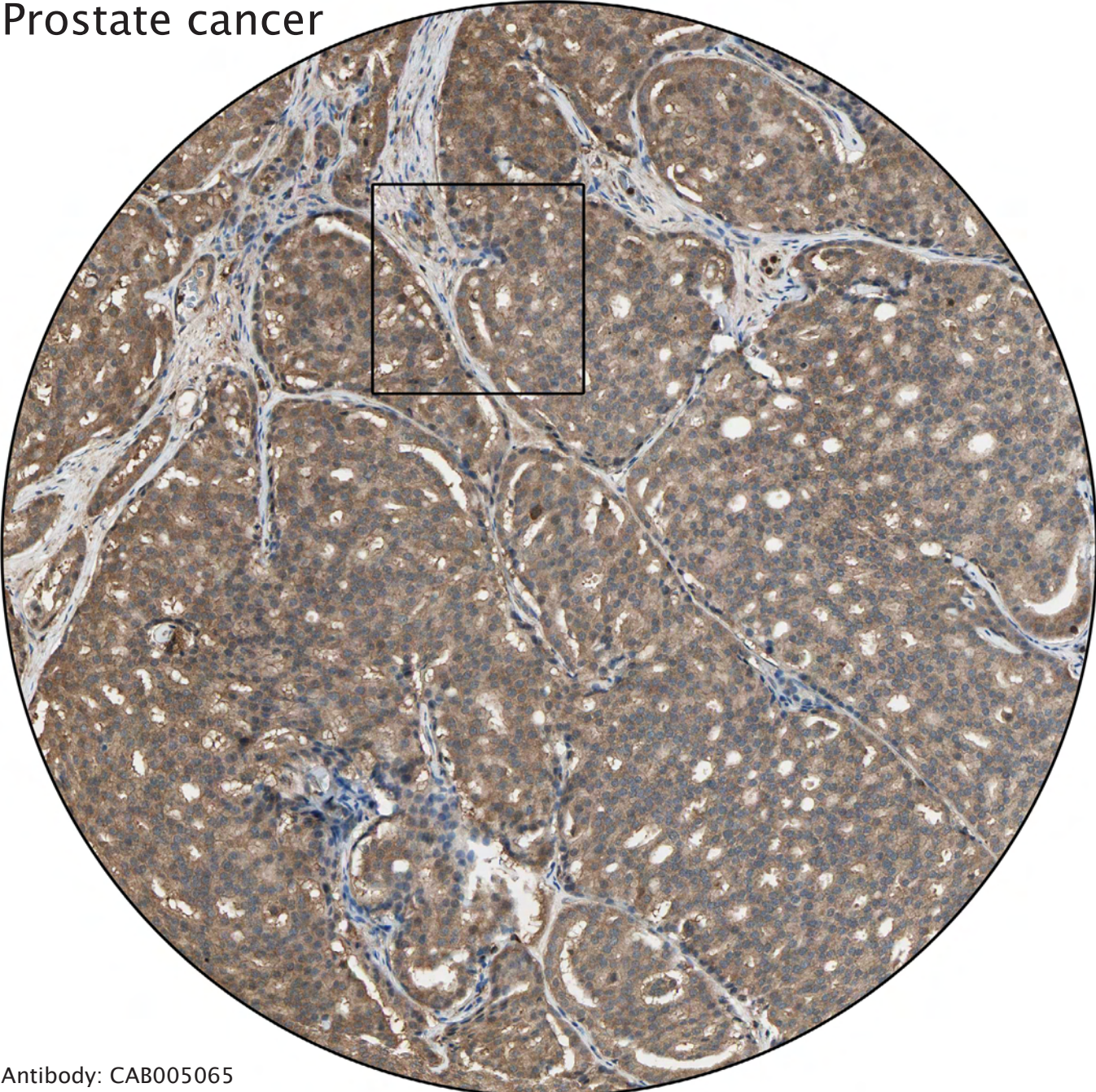


Distinct positivity of basal layer in benign glands.

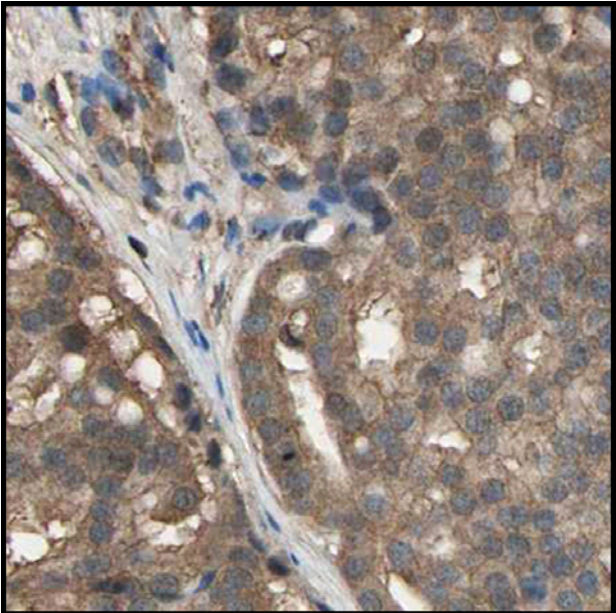
The tumor cells lack a positive basal layer and grow invasively between benign glands.

----- Tumor cells or not? -----

Prostate cancer



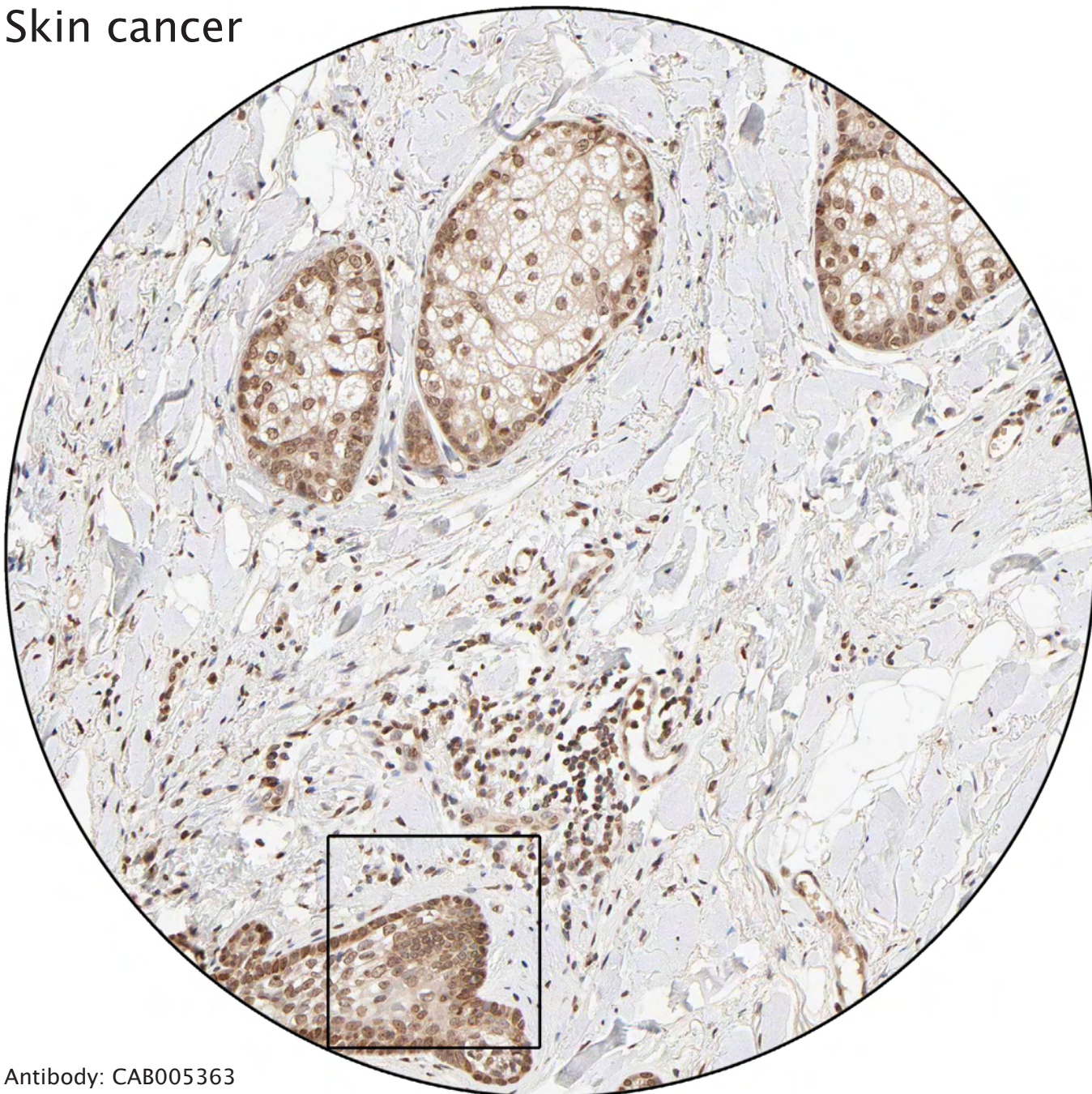
Antibody: CAB005065



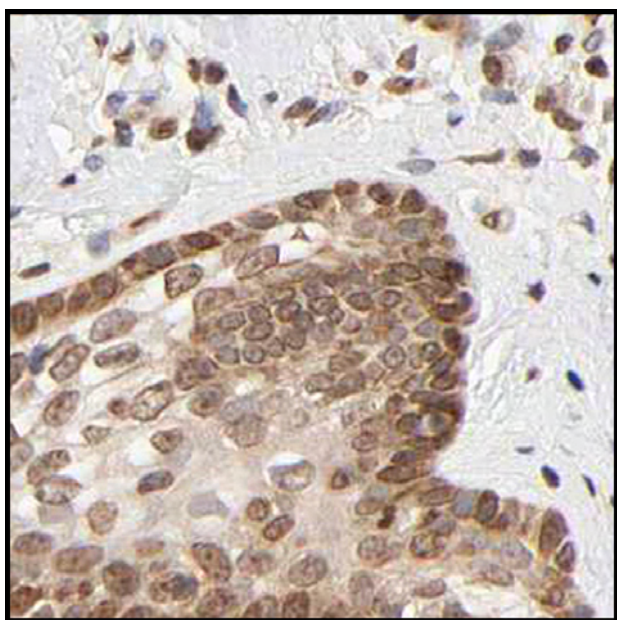
Prostate cancer (Gleason grade IV).

----- Tumor cells or not? -----

Skin cancer



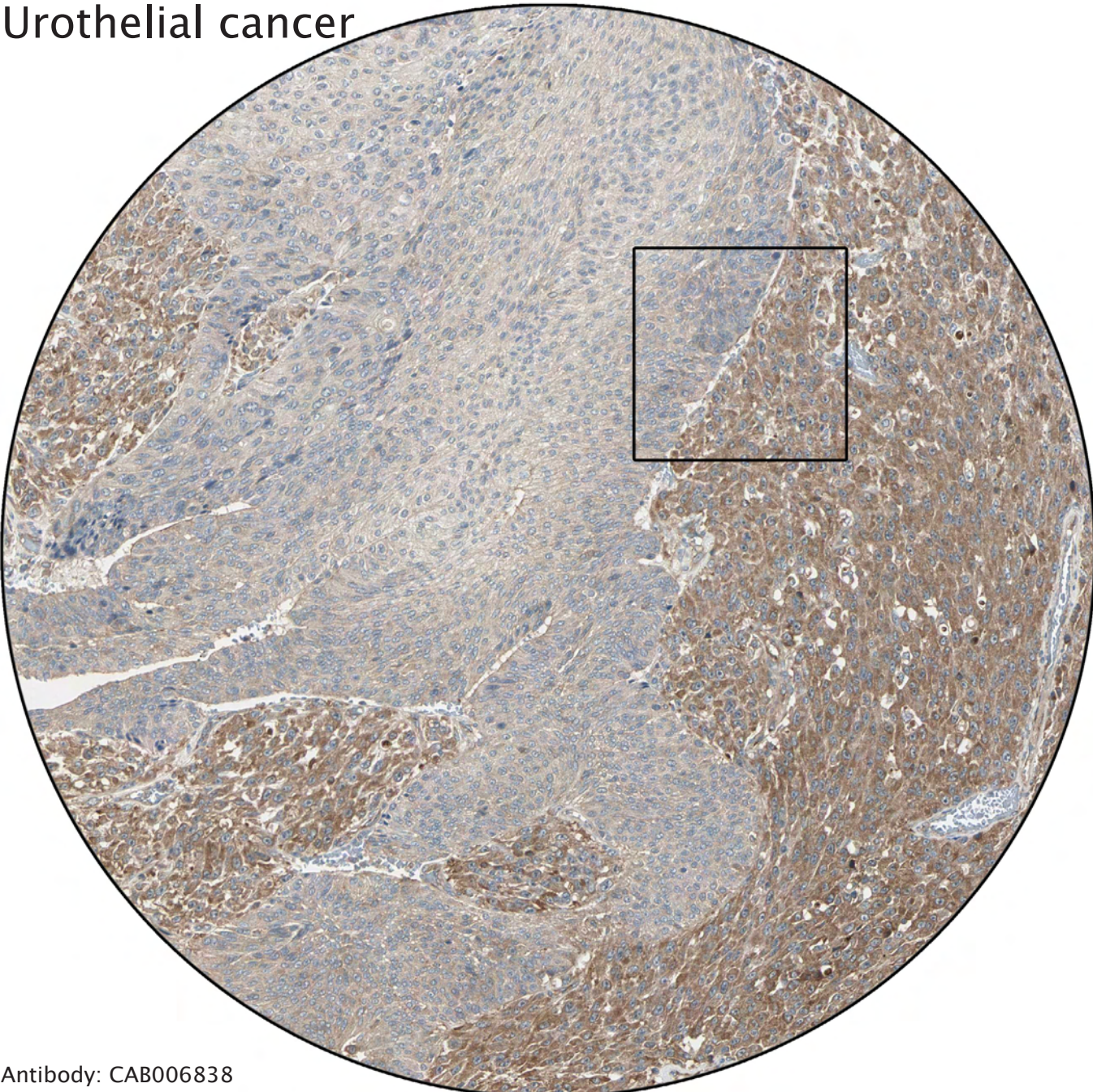
Antibody: CAB005363



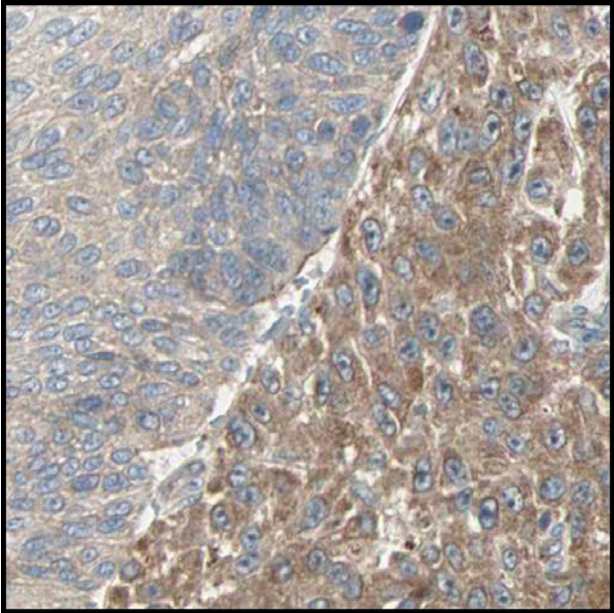
Sebaceous glands. Adnexal cells in skin can occasionally mimic basal cell carcinoma. There are no tumor cells in the picture above.

----- Tumor cells or not? -----

Urothelial cancer



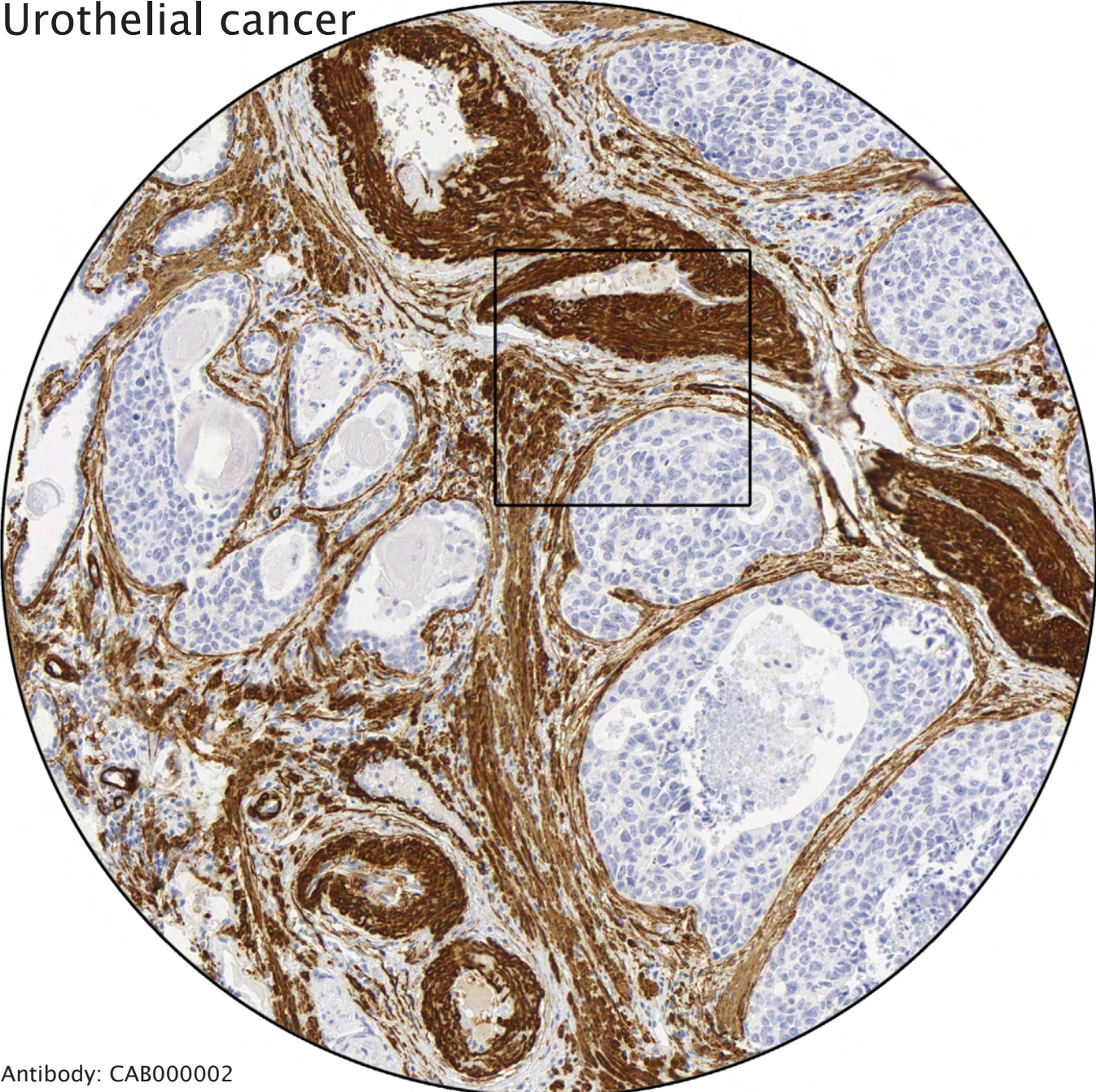
Antibody: CAB006838



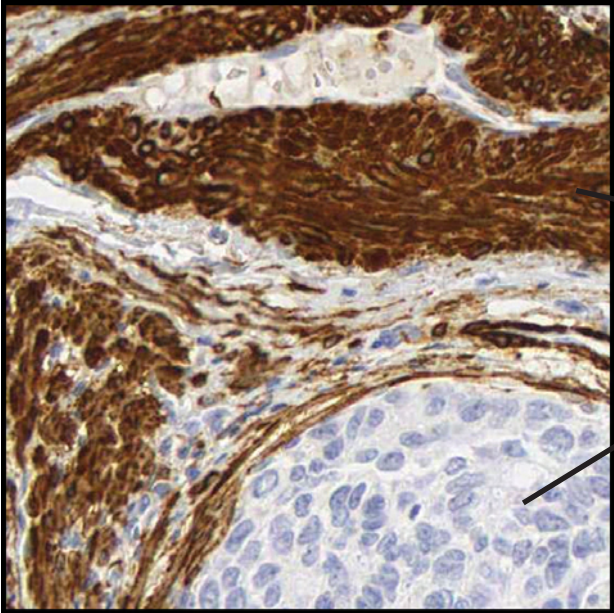
Both areas represent cancer, however, this tumor is bi-phasic, showing two clones with different grade of differentiation.

----- Tumor cells or not? -----

Urothelial cancer



Antibody: CAB000002



Strong positivity of smooth muscle cells.

Negative tumor cells.

----- Tumor cells or not? -----